

**COMPARATIVE STUDY BETWEEN MICROSCOPIC AND ENDOSCOPIC SURGERY  
IN INTRACRANIAL ARACHNOID CYSTS**

<sup>1</sup>\*Dr. Md. Moshir Rahman, <sup>2</sup>Dr. S.I.M. Khairun Nabi Khan, <sup>3</sup>Dr. Robert Ahmed Khan, <sup>4</sup>Dr. Md. Rokibul Islam, <sup>5</sup>Dr. K. M. Ziaur Rahman and <sup>6</sup>Prof. Mainul Haque Sarker

<sup>1</sup>Assistant Professor, (CC) Neurosurgery Department, Holy Family Red Crescent Medical College.

<sup>2</sup>Assistant Professor, Neurosurgery Department, BSMMU.

<sup>3,4</sup>Medical Officer, Neurosurgery Department BSMMU.

<sup>5</sup>Medical Officer, Neurosurgery Department Holy Family Red Crescent Medical College Hospital.

<sup>6</sup>Ex- Professor and Head, Neurosurgery Department Dhaka Medical College.

\*Corresponding Author: Dr. Md. Moshir Rahman

Assistant Professor, (CC) Neurosurgery Department, Holy Family Red Crescent Medical College.

DOI: 10.20959/ejpmr20202-7805

Article Received on 01/12/2019

Article Revised on 21/12/2019

Article Accepted on 11/01/2020

**ABSTRACT**

**Background:** Endoscopic or microscopic management for patient of intracranial arachnoid cysts are a surgeons choice and according to availability. Depending on the location of the cyst the surgeon may choose the procedure. Cortical cysts are challenging. Endoscopic fenestrations are less invasive and patients choice though the outcome is similar in both procedures. **Objective:** The main objective of this study is to compare the surgical outcome of endoscopic and microscopic management of intracranial arachnoid cysts. **Method:** A total 28 patients were studied retrospectively from 2009 to 2017 in private hospitals Dhaka, Bangladesh. The male and female ratio was 3:2. Both groups carry equal number of patients (14). [Endoscopic and microscopic] **Results:** Over 85% patients had satisfactory recovery. One patient required epilepsy surgery unrelated to cyst. Higher success rate in endoscopic procedure is noted. Sylvian cysts are most common in both groups. **Conclusion:** Both microscopic and endoscopic procedures are safe in intracranial arachnoid cysts. Endoscopic fenestration is less traumatic and gives better result though the outcome of surgery is almost similar.

**KEYWORDS:** Microscopic, Endoscopic, Intracranial, Fenestration, Arachnoid.

**INTRODUCTION**

Arachnoid cysts (ACs) are intra-arachnoid collections of cerebrospinal fluid (CSF)<sup>[1]</sup> and are regarded as a developmental abnormality of the arachnoid, originating from a splitting or duplication of this membrane.<sup>[2]</sup> Primary (congenital) arachnoid cysts are benign accumulation of clear fluid in relation to the arachnoid membrane between the dura and the brain substance throughout the cerebrospinal axis and do not communicate with subarachnoid space.<sup>[3]</sup> Secondary arachnoid cysts (acquired) are the consequence of hemorrhage, trauma and infection and typically interact with the subarachnoid space.<sup>[3-5]</sup> Specific locations of arachnoid cysts are the brain surface at the level of brain fissures such as sylvian, Rolandic and interhemispheric fissures, anterior cranial fossa and middle cranial fossa.<sup>[6]</sup> Surgical treatment is necessary for patients with raised intracranial pressure and corresponding clinical symptoms. Patients with acute arachnoid cysts have a significant improvement in their subjective preoperative dizziness after surgery.<sup>[7]</sup> Many operative methods for the

control of arachnoid cysts have been recommended, however it remains controversial as to which is the best method. Recently endoscopic procedure has been recommended as the first surgical option for cerebral AC.<sup>[8-13]</sup> Nowadays many kind of endoscopic procedures have been reported according to the location of lesion.<sup>[11-12]</sup>

**OBJECTIVE**

The main objective of this study is to compare the surgical outcome of endoscopic and microscopic management of intracranial arachnoid cysts.

**METHODS**

Type of Study - A retrospective study

Place of Study- Private hospitals Dhaka, Bangladesh.

Period of study – From 2009 to 2017

Sample size – 28

Figure 1 is showing that the male and female ratio was 3:2.

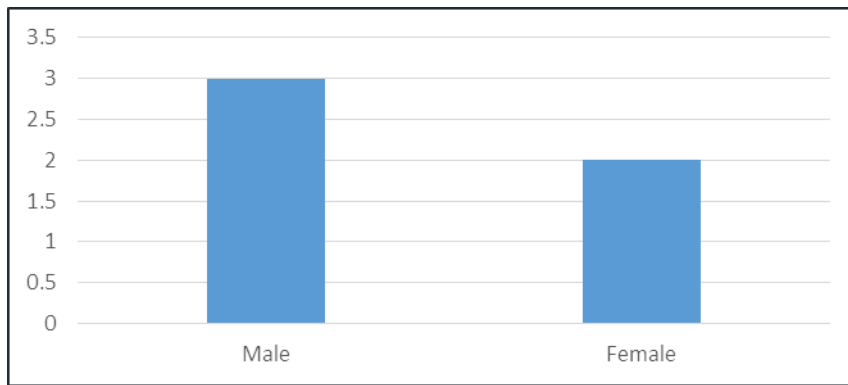


Figure 1: Male and female ratio.

Both groups carried equal number of patients and the number was 14 in both groups (endoscopic and microscopic). See figure 2-

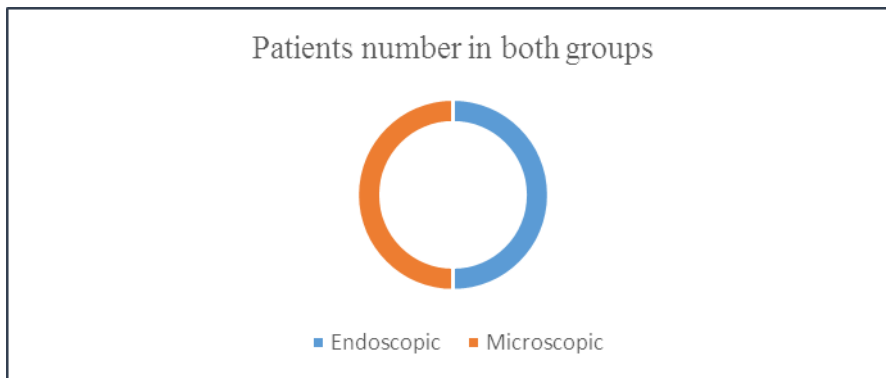


Figure 2: Number of patients in both groups.

**RESULTS**

In table 1, the present symptoms are shown. Among total 28 patients, headache was in 17 patients, gait disturbances in 3, cognitive decline and weakness in 5, and epilepsy in 1 patient.

**Table 1: Symptoms shown in all patients.**

Symptoms	Number of patients
Headache	17
Gait disturbances	3
Cognitive decline and weakness	5
Epilepsy	1

Among 28 patients the microscopic and endoscopic surgery was done equally. Different types of cysts were observed like cerebral convexity cysts, middle cranial fossa cysts, intraventricular region cysts, pineal area cysts, infratentorial cysts etc. but sylvian cysts were most common in both groups. In microscopic group it was in 62% patient and in endoscopic group it was in 71% patient. See figure 3-

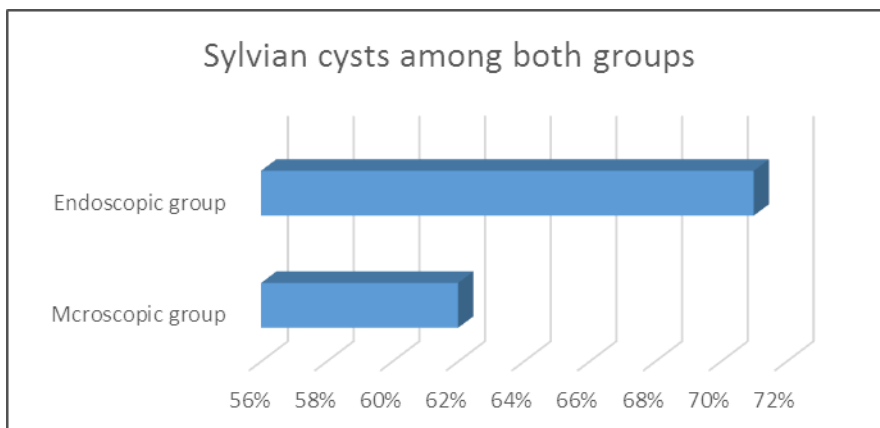


Figure 3: Rate of sylvian cysts among both group of patients.

Of the total 28 patients over 85% had complete satisfactory recovery. Improvement in their symptoms

were observed and higher success rate in endoscopic procedure has noted.

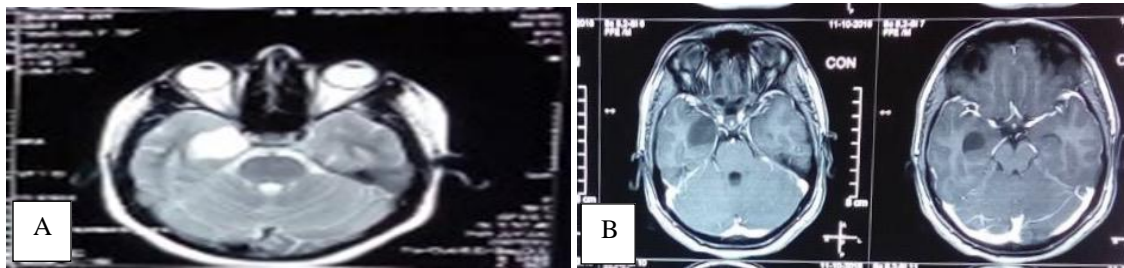


Figure 4 (A, B): Temporal Arachnoid cyst.

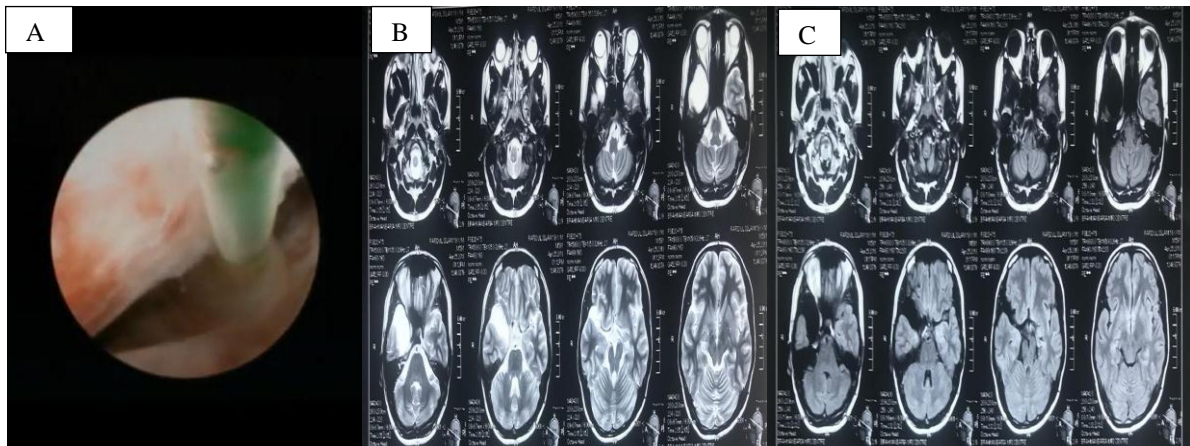


Figure 5: (A, B): Sylvian Arachnoid cyst. (C): Frontal Arachnoid cyst.

## DISCUSSION

Arachnoid cysts are found intracranially at any location and frequently communicating with the subarachnoid spaces. In boys, they are more common and occur on the right side. A study shows that arachnoid cysts occur in the temporal sections of the skull in 64.3% of patients and after surgery 85.71% patients improve significantly. Though headache was frequent in patients 50% patients but 71.4% patients did not have any neurological deficit.<sup>[14]</sup> Cysts in convexities constitute only 4% of total arachnoid cysts.<sup>[15]</sup> One interesting thing to note is that there may not be loss of any brain tissue, not even when the cysts are very large; it has been demonstrated that there is a proportional increase of affected hemisphericity.<sup>[16]</sup> This may explain why, in a majority of cases, no motor deficit or intellectual deficit has been found in different series.<sup>[17-19]</sup> Most authors agree that symptoms of intracranial hypertension, treatment resistant seizures, and focal neurological deficits are clinical criteria warranting surgical treatment.<sup>[20]</sup> Surgical interventions are varied and include endoscopic fenestration, microsurgical fenestration and cyst shunting. Some researchers agree that mistakenly found asymptomatic cases or those that only develop minor cosmetic defects do not require surgical intervention.<sup>[19,21]</sup> However we have reported some complications in our series but none of them was permanent. We could overcome the initial failure of surgery in one patient complicated by cerebrospinal fluid leakage by insertion of a cysto-peritoneal shunt.

Fortunately, subdural hygroma, which was reported in most of the other studies of endoscopic or microsurgical fenestration, was not reported in our study. One study shows they had 6 endoscopic fenestrations (25%) in patients who presented with non-ruptured sylvian arachnoid cyst.<sup>[22]</sup> Another one shows they had a complication rate of 29.4%.<sup>[23]</sup> The best surgical management of intracranial arachnoid cysts remains controversial. Microsurgical craniotomy provides focus excision or cortical thermocoagulation. The reoperation rate in the microscopic surgery group is bit higher than endoscopic surgery group. Microscopic surgery was more invasive than endoscopic surgery. However, the microsurgical technique can obtain greater control of hemostasis because of the ability to use bipolar forceps. A full space ensures the ability to perform another operation for cyst-related diseases, especially in cyst-related epilepsy. The latter technique is more efficient for cortical arachnoid cysts, cyst-related epilepsy, or cysts with preoperative diagnosis showing the possibility of a cystic tumor, according to previous studies.<sup>[24]</sup> The endoscopy gained low reoperation rate to microscopic surgery group for intracranial arachnoid cysts. Therefore, endoscopy is a safe and effective therapeutic modality. Our study shows higher success rate in endoscopic procedure but still there are some limitations in our procedure. In our study one patient required epilepsy surgery unrelated to cyst. Among all sylvian cysts were most common in both groups. In the endoscopic surgery the effective working area will be eroded by endoscope

itself. This 'hidden area' will not interfere with the operation itself, but may block the prompt approach to the specific endoscopic field area. It can be overcome by replacement of endoscope. Secondly, the limited illumination and view angle of endoscope can make 'blind spots' in the corner of operation fields, especially in the lesion with complex, large cavity. Finally, the surgeons cannot look behind along the shaft of endoscope. This may cause unexpected harmful events during endoscopic procedures. The imaging technology will be advanced day after day. Though the follow-up period is too short for long term outcome statements, the authors recommend additional endoscopic channel approach for arachnoid cyst treatment. If the endoscopic procedure fails, afterwards, existing treatment options can be carried out without additional risk.

### CONCLUSION

Advanced technology provide us new choices of treatment for intracranial arachnoid cysts. However, no gold standard criteria exist for different individuals. Microscopic surgery can be done for cortical arachnoid cysts but there is possibility of a cystic tumor or cyst-related epilepsy. Endoscopic surgery is the new safe technique and this involves the use of a high-definition and stereo vision system to observe the arachnoid cyst and its neighboring structures. Our study has shown higher success rate in endoscopic procedure as well. So, we can conclude that the endoscopic approach is highly effective for most cases of intracranial arachnoid cysts.

### REFERENCES

1. Ciricillo SF, Cogen PH, Harsh GR, Edwards MS: Intracranial arachnoid cyst in children. A comparison of the effects of fenestration and shunting. *J Neurosurg*, 1991; 74: 230-235.
2. Santamarta D, Aguas J, Ferrer E: The natural history of arachnoid cysts: endoscopic and cine-mode MRI evidence of a slit-valve mechanism. *Minim Invasive Neurosurg*, 1995; 38: 133-137.
3. Pascual-Castroviejo I, Roche MC, Martinez Bermejo A, Arcas J, Garcia Blazquez M. Primary intracranial arachnoidal cysts: a study of 67 childhood cases. *Childs Nerv Syst.*, 1991; 7: 257-63.
4. Robinson RG. Congenital cysts of the brain: arachnoid malformations. *Prog Neurol Surg*, 1971; 4: 133-74.
5. Pascual-Castroviejo I, Roche MC, Martinez Bermejo A, Arcas J, Garcia Blazquez M. Primary intracranial arachnoidal cysts: a study of 67 childhood cases. *Childs Nerv Syst.*, 1991; 7: 257-63.
6. Wester K. Peculiarities of intracranial arachnoid cysts: location, sidedness, and sex distribution in 126 consecutive patients. *Neurosurgery*, 1999; 45: 775-9.
7. Tunes C, Flønes I, Helland C, Wilhelmsen K, Goplen F, Wester KG: Pre- and post-operative dizziness and postural instability in temporal arachnoid cyst patients. *Acta Neurol Scand*, 2014; 129(5): 335-342.
8. Auer LM, Holzer P, Ascher PW, Heppner F: Endoscopic neurosurgery. *Acta Neurochir (wien)*, 1988; 90: 1-14.
9. Caemaert J, Abdullah J, Calliauw L, Carton D, Dhooge C, vanCoster R : Endoscopic treatment of suprasellar arachnoid cysts. *Acta Neurochir (Wein)*, 1992; 119: 68-73.
10. Choi JU, Kim DS, Huh R: Endoscopic approach to arachnoid cyst. *Childs Nerv Syst.*, 1999; 15: 285-291.
11. Hopf NJ, Poretsky A: Endoscopic neurosurgery and endoscope assisted micro neurosurgery for the treatment of intracranial cysts. *Neurosurgery*, 1998; 43: 1330-1336; discussion 1336-1337.
12. Kim MH: The role of endoscopic fenestration procedures for cerebral arachnoid cysts. *J Korean Med Sci.*, 1999; 14: 443-447.
13. Pierre-Kahn A, Capelle L, Brauner R, Sainte-Rose C, Renier D, Rappaport R, et al. : Presentation and management of suprasellar arachnoid cysts. Review of 20 cases. *J Neurosurg*, 1990; 73: 355-359.
14. Rahman MM, Zaman UKS. Surgical Outcome of Endoscopic Cysto-Cisternostomy for Arachnoid Cyst. *Ann. Int. Med. Den. Res.*, 2019; 5(1): MC01MC03. [Google Scholar].
15. Rangacharya SS, Watanabe I, Brackett CE. Pathogenesis of intracranial arachnoid cysts. *Surg Neurol*, 1978; 9: 139- 144.
16. Vahdermeache FGA, Braakman RJ. Arachnoid cysts in the middle cranial fossa: Causes and treatment of progressive and non-progressive symptoms. *J Neurol Neurosurg Psychiatry*, 1983; 46: 1102-1107.
17. Rangacharya SS. Parasagittal arachnoid cyst: A case report. *Neurosurgery*, 1981; 9: 70-75.
18. Robinson RG. Congenital cysts of the brain and arachnoid malformations. *Prog Neurol Surg*, 1971; 4: 133-174. VOLUME 32-AUGUST 1995.
19. Vahdermeache FGA, Braakman RJ. Arachnoid cysts in the middle cranial fossa: Causes and treatment of progressive and non-progressive symptoms. *J Neurol Neurosurg Psychiatry*, 1983; 46: 1102-1107.
20. Duz B, Kaya S, Daneyemez M, Gonul E: Surgical management strategies of intracranial arachnoid cysts: A single institution experience of 75 cases. *Turk Neurosurg*, 2012; 22(5): 591-598.
21. Hanich A, Simpson DA, North JB. Arachnoid cysts: A critical review of 41 cases. *Child's Nerv Syst.*, 1988; 4: 92- 96.
22. Schulz M, Kimura T, Akiyama O, Shimoji K, Spors B, Miyajima M, Thomale UW: Endoscopic and microsurgical treatment of sylvian fissure arachnoid cysts-clinical and radiological outcome. *World Neurosurg*, 2015; 84(2): 327-336.
23. Couvreur T, Hallaert G, Van Der Heggen T, Baert E, Dewaele F, Kalala Okito JP, Vanhauwaert D, Deruytter M, Van Roost D, Caemaert J: Endoscopic treatment of temporal arachnoid cysts in 34 patients. *World Neurosurg*, 2015; 84(3): 734-740.

24. Gangemi M, Seneca V, Colella G, Cioffi V, Imperato A, Maiuri F. Endoscopy versus microsurgical cyst excision and shunting for treating intracranial arachnoid cysts. *J Neurosurg Pediatr*, 2011; 8: 158-64.