

EFFICACY OF METHOTREXATE FOR MANAGEMENT OF UNRUPTURED ECTOPIC PREGNANCY IN BANGLADESH**Dr. Farhana Kabir^{*1}, Dr. Shamima Ferdous Chowdhury², Dr. Nayer Islam³**¹Lecturer, Dept. of Pharmacology, Gazi Medical College, Sonadanga, Khulna, Bangladesh.²Lecturer, Dept. of Pharmacology, Dhaka Central International Medical College, Dhaka, Bangladesh.³Lecturer, Dept. of Pharmacology, Gazi Medical College, Sonadanga, Khulna, Bangladesh.***Corresponding Author: Dr. Farhana Kabir**

Lecturer, Dept. of Pharmacology, Gazi Medical College, Sonadanga, Khulna, Bangladesh.

Article Received on 03/04/2020

Article Revised on 24/04/2020

Article Accepted on 14/05/2020

ABSTRACT

Objectives: In this study our main aim is to evaluate efficacy of Methotrexate for management of Unruptured Ectopic pregnancy in Bangladesh. **Methods:** A prospective observational study was carried out tertiary medical college and hospital from May 2011 to May 2012. During the study all the patients had initial investigations before the administration of Methotrexate. **Results:** in the study 70% presented with abdominal pain and only 30% had per vaginal bleeding. 91% patients had only single dose of methotrexate and only 7% patients needed more than one dose which were two and three doses respectively, and 2% patient needed laparotomy for suspected ruptured ectopic. 70% patients were completely recovered after treatment. **Conclusion:** Methotrexate is safe and effective for unruptured ectopic pregnancies that satisfy the strict criteria with little side effects and the advantage of avoiding invasive surgery. Further study is needed for better outcome.

KEYWORDS: Ectopic pregnancy; Methotrexate, reproduction.**INTRODUCTION**

A pregnancy located outside the uterine cavity is defined as an ectopic pregnancy. About 99% of ectopic pregnancy occur in the fallopian tube and it accounts for 1-2% of all pregnancies.^[1] Ectopic pregnancy are potentially life threatening and incidence of it continues to increase day by day due to the occurrence of sexually transmitted disease, prior salpingitis, IUCD users, pelvic adhesions and after infertility treatment. Until recently, ectopic pregnancy was considered an exclusively surgical condition.

It is one of the most important causes of death during 1st trimester of pregnancy. Ectopic pregnancy is more threatening for women than normal vaginal delivery and induced abortion.^[2] Timely diagnosis and appropriate treatment can reduce the risk of maternal mortality and morbidity related to ectopic pregnancy.^[3] If not diagnosed and treated preciously it may also take the life of the mother or at the very least, compromise her future ability to reproduce.

Surgery is not always the most appropriate form of treatment. Medical management avoids the inherent morbidity of anesthesia and surgery and reduce costs. Methotrexate, Potassium chloride, hyperosmolar glucose, Actinomycin D and Prostaglandins have been used successfully to treat ectopic pregnancy.^[4-5] Methotrexate

(MTX) has been established as an effective first line medical therapeutic alternative to surgical treatment. Methotrexate, a folic acid antagonist, highly toxic to rapidly replicating trophoblastic cells has been the mainstay of the medical management of ectopic pregnancy.^[6]

In this study our main aim is to evaluate efficacy of Methotrexate for management of Unruptured Ectopic pregnancy in Bangladesh.

OBJECTIVE**General objective**

To evaluate efficacy of Methotrexate for management of Unruptured Ectopic pregnancy in Bangladesh.

Specific objective

- To detect clinical signs among patients.
- To identify treatment status of the patients.

METHODOLOGY

Type of study	Prospective observational study
Place of study	Tertiary medical college and hospital
Study period	May 2011 to May 2012.
Study population	Total 100 patients having ectopic pregnancies were included in this study.
Sampling technique	Random sampling

METHOD

During the study all the patients had initial investigations before the administration of Methotrexate. Selection criteria for medical therapy were positive pregnancy test, abdominal pain, per vaginal bleeding, hemodynamically stable condition, β -hCG < 3000 IU/L and sonographic (TVS) findings of adnexal mass < 3cm with no cardiac pulsation. Criteria for medical therapy in this study included a stable clinical condition, no evidence of rupture on ultrasound, normal liver and renal function, patients' reliability for followup. These patients

were treated with 50 mg of intramuscular methotrexate (single or multiple doses)

Statistical analysis

Collected data was collated and appropriate statistical analysis was done using computer-based SPSS (Statistical program for scientific study) package.

RESULTS

In table-1 shows gender distribution of the patients where most of the patients belong to 20-30 years age group. The following table is given below in detail:

Table 1: Gender distribution of the patients.

Age group	Percentage (%)
< 20 Years	4.5
20 to 30 Years	82.1
> 30 Years	13.4

In table-2 shows height, weight, BMI, blood pressure and Pulse rate of study groups where mean (\pm SD) weight of the subjects were 50 ± 10.4 Kg and 55 ± 10.3 Kg in study group respectively. The following table is given below in detail:

Table 1: Height, Weight, BMI, Blood pressure and Pulse rate of study groups (n=100).

Variable	Group A (n=100)
Height (cm)	63 ± 2.0 (55 - 67)
Weight (kg)	50 ± 10.4 (32 - 92)
BMI (kg/m^2)	22 ± 4.1 (15.6-28.8)
Systolic BP (mm of Hg)	109.49 ± 7.0 (100 - 120)
Diastolic BP (mm of Hg)	76.85 ± 4.9 (70-80)
Pulse (beats/min)	78 ± 4.1 (70 - 88)
Initial β -hCG level:	
<1500 IU/L:	68
>1500 IU/l	32
β -hCG	< 3000 IU/ml.
Size of gestational sac	2.5 - 4cm

In table-3 shows educational status of the patients where 21.4% patients were illiterate followed by 23.2% passed class I-V, SSC passed only 11.6%. The following table is given below in detail:

Table 3: Distribution of educational status among the patients.

Educational Status		Among patients (%)
Educational Status	Illiterate	21.4
	Can Sign Only	18.8
	Class I – V	23.2
	Class VI – X	22.3
	SSC Passed	11.6
	HSC & Above	2.7

In figure-1 shows clinical signs among patients where 70% presented with abdominal pain and only 30% had

per vaginal bleeding. The following figure is given below in detail:

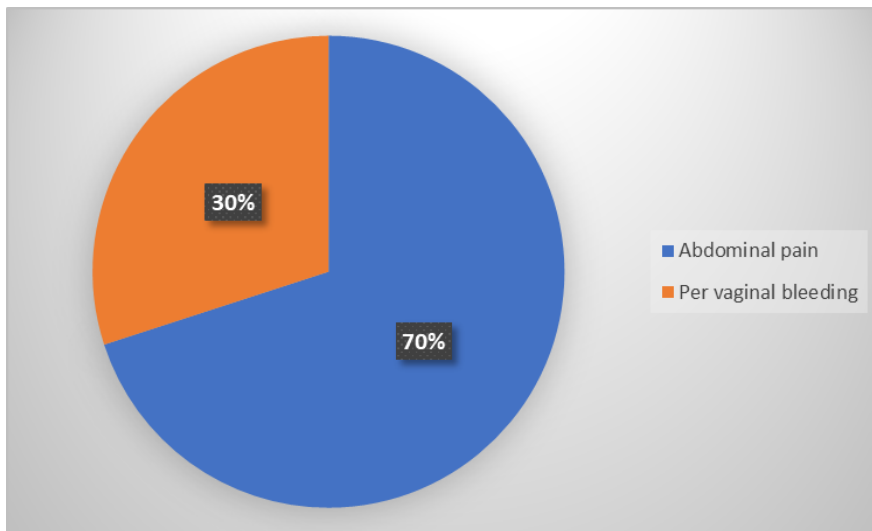


Figure 1: Clinical signs among patients.

In figure-2 shows treatment status of the patients where 91% patients had only single dose of methotrexate and only 7% patients needed more than one dose which were

two and three doses respectively, and 2% patient needed laparotomy for suspected ruptured ectopic. The following figure is given below in detail:

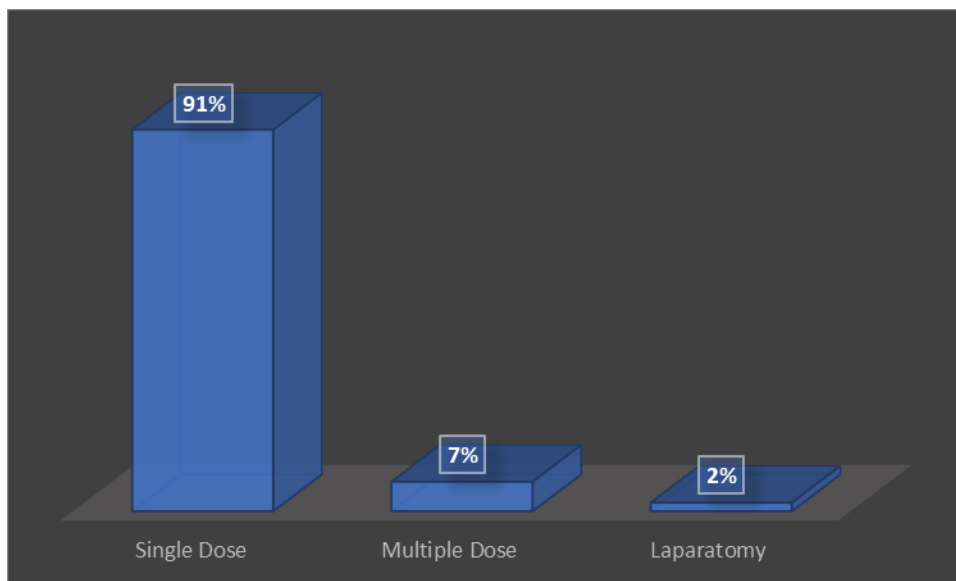


Figure 2: Treatment status of the patients.

In table-4 shows post treatment status of the patients where 70% patients were completely recovered. The

following table is given below in detail:

Table 4: Post treatment status of the patients.

Age group	Percentage (%)
Complete and uneventful recovery	70%
Tubal rupture	12%
Tubal abortion	10%
Complication of drug	1%

In figure-3 shows time taken for resolution of β -hCG to <5 I.U/L. 95% patients who had methotrexate their β -hCG returned to the normal within 28 days. 5% patient

took 42 days for her β -hCG to return to normal. The following figure is given below in detail:




Figure 3: Time taken for resolution of β -hCG to <5 I.U/L.

In figure-4 shows complication after treatment where 90% patients had no complication followed 7% had hair

loss problem, 3% had gastroenteritis. The following figure is given below in detail:

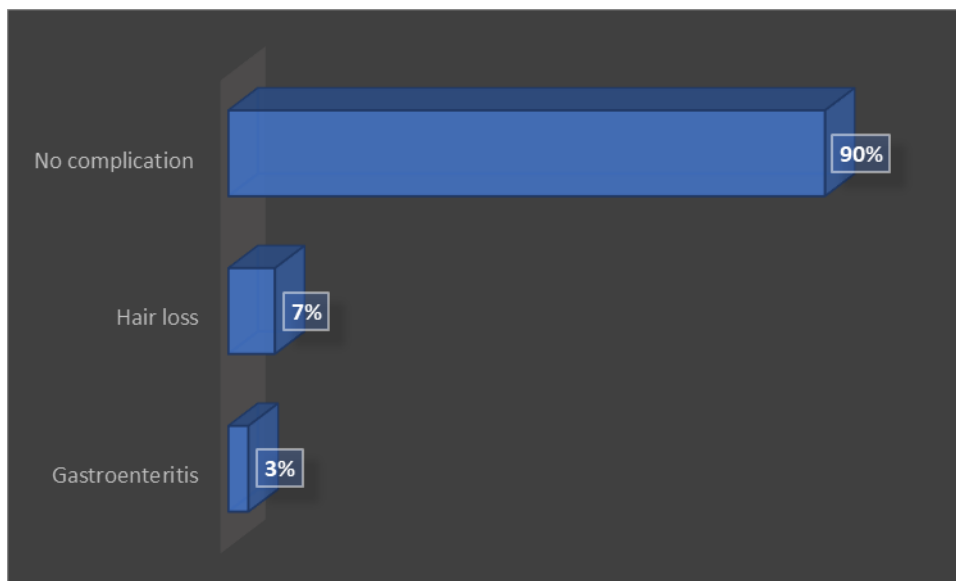


Figure 4: Complication after treatment.

DISCUSSION

Since the late 1980s, systemic Methotrexate has been employed to treat ectopic pregnancy with

excellent result. The initial studies were done using Methotrexate and Leucovorin for the treatment of unruptured ectopic pregnancy in selected,

stable patients. Patients were closely monitored during therapy with complete blood count, liver and renal function tests and β -hCG levels.^[8]

In one study supports the use methotrexate as a safe and highly effective alternative treatment of ectopic pregnancies with a success rate of 85%. Which was quite similar to our study, success rate was 90%.^[9]

Management of ectopic pregnancy has shifted from emergency lifesaving intervention to more conservative treatment modalities aimed at reducing mortality and morbidity, preserving fertility and reducing costs.^[10]

Laparoscopic surgery is still the cornerstone of the treatment in the majority of women with tubal pregnancy. If the diagnosis of ectopic pregnancy can be made earlier noninvasively, medical treatment with systemic intramuscular Methotrexate in a single or multiple dose regimen is an alternative treatment option, but only after properly informing patients about the risk and benefit of the available treatment option if the following criteria are satisfied as follows: haemodynamically stable women, unruptured tubal pregnancy, no sign of active bleeding and low initial serum β -hCG concentration.^[11-12]

In one report they showed that, three to seven days after receiving methotrexate, some patients may also experience pelvic pain which maybe caused by tubal abortion and can be confused as tubal rupture.^[13] In presence of stable vital signs and serial normal haematocrits, these episodes are self-limited and do not warrant surgical intervention. The first quantitative β -hCG should not be obtained sooner than 4 days post methotrexate treatment as an initial increase in the β -hCG level is frequently noted presumably due to trophoblast lysis. In our study, 95% patients who had methotrexate their β -hCG returned to the normal within 28 days. 5% patient took 42 days for her β -hCG to return to normal.

In one article reported that, side effects of medical treatment may include transient increase in liver enzymes, gastroenteritis, hair loss.^[14] Which is quite similar to our study where 90% patients had no complication followed 7% had hair loss problem, 3% had gastroenteritis.

CONCLUSION

Methotrexate is safe and effective for unruptured ectopic pregnancies that satisfy the strict criteria with little side effects and the advantage of avoiding invasive surgery. Further study is needed for better outcome.

REFERENCES

1. Talwar P, Sandeep VSM, Nikita, Dugga BS, Tony J. Systemic methotrexate: An effective to surgery for the management of unruptured ectopic pregnancy. Medical Journal Armed Forces India, 2013; 69: 130-131.

1. Cunningham FG et al. Ectopic pregnancy In Williams obstetrics, 21st ed. New York. MCGraw Hill, 2001; 883-910.
2. Dhar H, Hamdi I, Rathi B. Methotrexate Treatment of Ectopic Pregnancy: Experience at Nizwa Hospital with Literature Review. Oman Med J. Mar, 2011; 26(2): 94-98.
3. Oron G, Tulandi T. A Pragmatic and Evidence-Based Management of Ectopic Pregnancy. Journal of Minimally Invasive Gynecology, 2013; 20(4): 446-454.
4. Berek JS, Rinehart RD, Hillard APJ, Adash, EY. Novak's Gynaecology, 13th ed. Wolters Kluwer. William and Willkins, 2002; 507-42.
5. Barnhart KT. The medical management of ectopic pregnancy. A meta analysis comparing single dose and multi dose regimens. Obstetric Gynaecology, 2003; 101: 778-84.
6. Speroff L, Glass Rh, Kase NG. Clinical Gynaecology endocrinology and infertility, Sixth ed. Wolters kluwer; William and Wilkins, 1999; 1146-48.
7. S. Vitthala, M Cheema, Misra P K. Medical Management of ectopic pregnancy using methotrexate. The Journal of Gynecology and Obstetric, 2006 6(2): 8713-17.
8. Pilic Z. Juznic N. Radosavltevic A. Pantovic D. Treatment of ectopic pregnancy using methotrexate.] Jugoslavenska Gineko Logijia Perinato Logija, 1990; 30(3-4): 87-9.
9. Lozeau AM, Potter B. Diagnosis and Management of Ectopic Pregnancy. *Am Fam Physician*, 2005; 72(9): 1707-1714.
10. Lantikainen T, Tuomivaara L, Kanppila K. Comparison of a Local injection of Hyperosmolar glucose solution with saipingectomy for the conservative treatment of tubal pregnancy. *FertilSteril*, 1993; 60: 80-4.
11. Lindblom B, Hahlin M, Lundorff P, Thorburn J. Treatment of tubal pregnancy by laparoscope guided injection of prostaglandin F2 alpha. *FertilSteril*, 1990; 54: 404.
12. Stika CS. Methotrexate: the pharmacology behind medical treatment for ectopic pregnancy. *Clin Obstet Gynecol*, 2012 Jun; 55(2): 433-9.
13. Shehab. M, Nusair B. Medical treatment of ectopic pregnancy. *Rawal Med J*, 2008; 33: 186-188).