

SIGNIFICANCE OF APICAL PATENCY IN ENDODONTICS. A NARRATIVE REVIEWChein Shee Antoinette Yen^{#1}, Kashmira Sawant^{#1}, Dr. Ajinkya M. Pawar^{1*} and Dr. Kulvinder Singh Banga¹[#]Intern¹Department of Conservative Dentistry and Endodontics, Nair Hospital Dental College, Mumbai, Maharashtra India.***Corresponding Author: Dr. Ajinkya M. Pawar**

Department of Conservative Dentistry and Endodontics, Nair Hospital Dental College, Mumbai, Maharashtra India.

Article Received on 11/10/2020

Article Revised on 21/11/2020

Article Accepted on 01/12/2020

ABSTRACT

The apical portion of root canal is the most complex part of tooth anatomy. To negotiate the root canal the most common method used is apical patency. Gaining apical patency means that a small flexible K-file which is passively moved through the apical constriction 0.5-1mm beyond the minor diameter without widening it. This process involves the use of a small diameter file that is set 1mm longer than the working length and recapitulated after each instrument to prevent packing of debris in the apical part. The prominence of micro-organisms in pulpal and periapical diseases is notable and the anaerobic bacteria are recognised as important pathogens. With advances in apical patency all techniques have its own advantages and limitation so it is important to use the technique judiciously and minimize trauma to periapical tissue and respect the root apical anatomy. This article weighs the pros and cons of apical patency and its clinical significance along with its need.

KEYWORDS: Apical patency, apical seal, periradicular diseases, recapitulation, working length.**INTRODUCTION**

The innate complexity of the apical third of the root canal make the process of debridement and preparation intricate in nature often resulting in blocked root canals due to the clogging of pulpal remnants and dentinal chips.^[1,2] This may lead to procedural errors such as apical transportations, ledge formations and perforations.^[3] Instrumentation beyond the apical constriction is not accepted, albeit when executed to the apical constriction which is the smallest diameter located coronally to the apical foramen deliver the best prognosis however its position and diameter cannot be identified in radiographs.^[2,3] The liability of root canal failures is considered to be due to incomplete debridement, foramen transportations and inadequate seal.^[3] Additionally another debatable argument is the maintenance of the apical patency during canal preparation.^[2] Several researchers and authors have emphasized on the concept of patency filling.^[4] This article weighs the pros and cons on apical patency and its necessity in endodontic therapy.

Concept of Apical Patency

American Association of Endodontics defines patency, "a canal preparation technique where the apical portion of the canal is maintained free of debris by recapitulation with a small file through apical foramen".^[4] The most accepted method is carried out by passing a patency file as small as no 6-10K file through the apical foramen to assure that the canal is negotiable in other words patent.^[5] Buchanan describes patency, -"small flexible

K-file which is passively moved through the apical constriction 0.5-1mm beyond the minor diameter without widening it".^[4] Apical patency curtails the risk of losing working length, enhances irrigation and improves the tactile sensation of the clinician.^[6,7] On the contrary numerous studies relate the extrusion of contaminated debris and irritated periapical tissues to apical patency.^[8,10]

Role of Micro-Organisms /Microbiological Considerations

The prominence of micro-organisms in pulpal and periapical diseases is notable and the anaerobic bacteria are recognised as important pathogens.^[11] Notwithstanding the divergences regarding their percentage the predominance of anaerobic micro-organisms in the apical third, including the cemental canal is a common trait.^[12,13] The endodontic treatment of vital teeth is originally a prophylactic treatment, for the reason that the pulp space is usually free of micro-organisms and the prevailing hypothesis is to prevent probable infection and consequently periradicular disease.^[14,15] Intra radicular infection in cases of necrotic pulps has already been established and endodontic procedure should focus not only on preventing new micro-organisms from being introduced into the root canal system, but also in reducing the micro-biological load there.^[16]

Importance of Apical patency

During mechanical instrumentation of root canal, dentinal shaving and apical pulp tissue may get packed towards the apical foramen causing apical blockage. The concept of apical foramen is defined as creation of glide path for the file for instrumentation of apical part of root canal and prevent occlusion of the canal apex from debris.^[17,18,19] The apical patency is established by cleaning the apical foramen free from dentin chips with an instrument that binds to the apical foramen and moves freely through the foramen without advancing beyond the apex. On contrary of this procedure there are few arguments; one of them being that if a file of diameter same as the apex will lead to extrusion of debris beyond the apex.^[18] While the apex diameter will reduce extrusion of debris, the purpose of apical patency is to maintain access to the foramen which is mechanical goal of biochemical preparation of root canal and along with the patency the foramen must be clean which is biological goal of canal instrumentation.^[20] As the patency file with smaller diameter will not be cleaning canal properly whereas the one that binds the canal walls will certainly have better cleaning action. Hence the best approach is negotiating the canal with a file smaller diameter and further cleaning the canal with a file binding the canal walls.^[21] An extremely important issue while establishing the working length is the apical limit of the file. There is a general agreement of maintaining the instrumentation and root filling within the root canal.^[22] The various apical reference points are Cemento-dentinal junction (CDJ), Apical foramen (AF), Apical constriction (AC) and radiographic apex.^[23,24] According to the anatomy of the root canal which diverges from the minor constriction towards the coronal, third the file binding the apical foramen will solely bind the foramen portion and will not touch the divergent walls of the canal limiting its cleaning potential. There are various concepts for determining the working length which have been proposed but the most widely accepted approach is to choose working length 1mm coronal to the apex. According to Wein's,^[25] recommendation working length should be 1, 1.5 or 2mm short of radiographic apex. The limitation of this technique is that foramen is not thoroughly cleaned. This explains the reason for persistent lesions and root canal failure. It is proved in various studies that there is presence of bacteria beyond the foramen so it suggested to extend the instrumentation beyond this area.^[26] In some cases over instrumentation of canal beyond the apical foramen into periapical tissue will lead to acute inflammatory response,^[27,28] and irritation of tissues.^[29] The pathogens may gain access to periapical tissues causing extra-radicular through over instrumentation. Whereas under instrumentation of the root canal may lead to the loss of working length and debris plug in the apical area of root.^[30] The most important point while determining the working length is the ideal apical termination point which could be CDJ, AF, AC and radiographic apex.

Cemento-dentinal junction – Termination point

The ideal point for root canal treatment termination is CDJ.^[31,32] Theoretically sealing the canal at this point will prevent escape of microbes into the periapical tissue and prevent entry of tissue fluid in the canal.^[33] CDJ cannot be considered as ideal termination point as it's a histological point and cannot be located clinically. Hence CDJ cannot be used as end point in root canal procedure.

Apical foramen – Termination point

Apical foramen can be considered as a reliable landmark as it is located within the apex of root so entire cleaning and shaping procedure is performed within the root canal. However the location of AF can accurately detected histologically,^[34] and also the position of AF was reported to affect the accuracy of electronic apex locator.^[35] Hence it is not considered as ideal reference point.

Apical constriction- Termination point

Apical constriction also called as minor diameter is the smallest apical dimension of root canal. Limitation of instrumentation to this point will lead to least amount of tissue damage.^[36] In various studies it has been proved that there is favourable histological response at the periapical region when instrumentation ended at the level of AC.^[37] Studies conducted by Sjögen^[38] et al concluded that 90% healing in infected teeth is seen when instrumentation is limited to AC. Other studies in literature concluded that the treatment outcome was better in studies in which instrumentation was extended till the level of AC. There are several limitation in the process of restricting instrumentation till AC some of which includes retaining diseased tissue retained apical to the AC,^[39] in many teeth AC cannot be histologically identified,^[40,41] and variability in position of AC complicates the root canal procedure.^[42,43]

Radiographic apex- Termination point

Extending the instrumentation and root filling to the level of radiographic apex was recommended by Schilder.^[18,44] There few long term results in support of this concept as adapting the radiographic apex as reference point would result in under or over instrumentation as AF does not coincide with radiographic apex in most cases.^[45] In a in vitro studies 50% of the teeth had file extended beyond the apex when it was inserted at the level of radiographic apex.^[46]

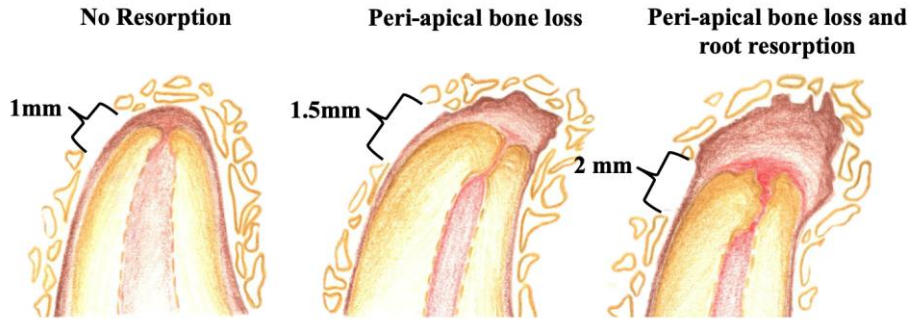


Figure 1: Morphology of the anatomy of the root apex.

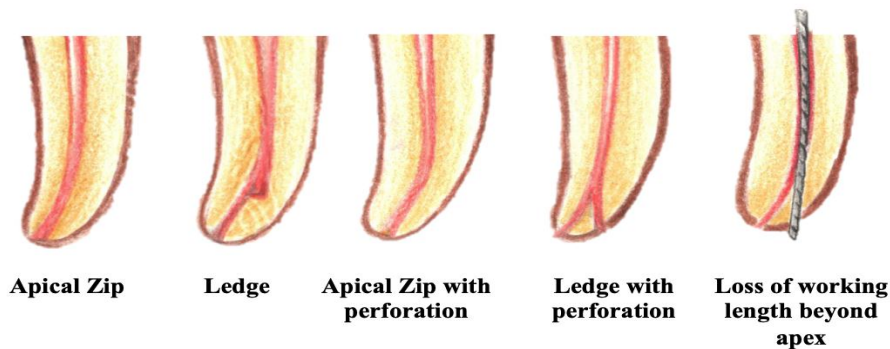


Figure 2: Weine's modification of working length determination. 1) No resorption-subtract 1 mm. 2) Periapical bone loss-subtract 1.5mm. 3) Periapical bone loss+ root apex resorption-subtract 2mm.

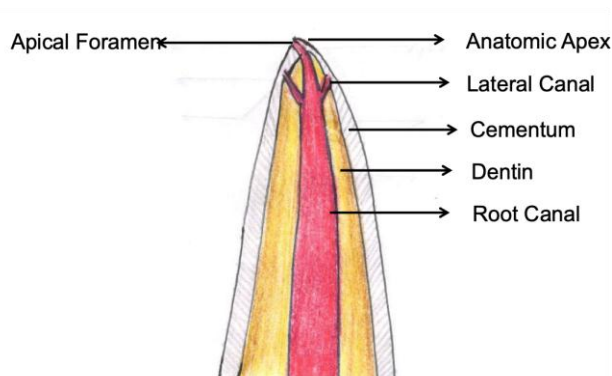


Figure 3: Hazards of overenlarging the apical curve.

Table 1: Advantages of gaining Apical Patency.

Advantages of gaining Apical Patency	
1.	Helps in establishing a smooth glide within for the entire root canal from orifice to apical foramen.
2.	Helps the clinician understand the presence of apical root curvature if any.
3.	Improves the efficiency of root canal irrigation in the apical third.
4.	Helps to reduce the loss of working length and prevents apical blockage.

Table 2: Endodontic treatment outcome in the persistence of bacteria.

Endodontic treatment outcome in the persistence of bacteria.	
1.	Able to survive without nutrients.
2.	Helps the clinician understand the presence of apical root curvature if any.
3.	Reach a climax population density (load) high enough to inflict damage on host.
4.	Reaching concentrations strong enough to directly or indirectly induce damage to periradicular tissues.

Advantages of negotiating Apical Patency

Apical patency aims at a mechanical preparation of the canal walls and cleaning of the apical exit free of debris and microorganisms. The use of patency filling has several advantages which are discussed in Fig 2.

1. Maintenance of Glide path

The procedure of preparation of smooth filling of canal walls through circumferential filling by successive file often leads to clogging of dentinal shavings at the apex and hinders proper instrumentation of the canal. The use of patency filling ensures the apex is clear of debris occlusion and helps in achievement of root canal treatment objectives.^[47]

2. Enlightens the clinician about apical root anatomy

The root apex being the complex part of root anatomy makes it difficult for clinician to gauge the root curvature. The coronal 3rd of the root is flared up with constricts towards the apex.^[48] The technique of precurving the small file #10K in accordance the root curvature with reference from periapical radiograph helps to sense the three dimensional anatomy of the root and sense the curvature of root canal.^[49]

3. Helps to improve the efficiency of irrigation procedure.

The anatomy of root apex consists of several lateral canal and apical delta.^[48] As in the procedure of mechanical instrumentation the apical foramen enlargement is restricted to ISO size 20-30 which limits the volume of irrigant in apical third of root canal system. The use of apical filling with small ensures the movement of irrigant in the apical wall and lateral canal with various technique like dynamic agitation,^[50] along with irritants' such as 17% EDTA and 5.25% NaOCl which clear organic and inorganic debris. It is suggested by Buchanan to check patency of the canal prior to irrigation of the canal after with filling with a larger diameter file.

4. Prevents loss of working length

The root apex is usually occluded with debris and dentins particles after instrumentation which leads to blockage of canal and loss of working length.^[51]

In phase of canal preparation the loss of working length leads to incomplete treatment of periapical infection and further progress to periapical abscess or cyst accompanied by bone loss in the same region. It is advices to recapitulate the canal with the apical file to check the patency of canal and the working length which ensures proper disinfection of canal and achieve a proper apical seal.^[52]

Limitations in Achieving Apical Patency

Listed below are situations that could conceivably hinder the clinician against attaining competent levels of apical patency. Fig 3.

Primarily the existence of an immature root present in young individuals or as an after effect of a traumatic incidence to the dentition during the phase of tooth development .This results in recurrent bleeding during the course of instrumentation and irrigation. The irrigants delivered through side vented needles, activated either manually or mechanically are advocated to accomplish improved cleanliness of the canal space.^[53]

The existence of blocked canals developed physiologically as a consequence of the deposition of cementum results in failure to achieve apical patency. The canal in these cases is negotiated with the help of viscous chelating agents along with pre-curved files in a light pecking motion. Neglect during the clearing of the apical pathway hints at a failure to deride the apical region from groups of dormant organisms effectively. The prognosis of the root canal therapy may not have favourable outcomes and hence regular follow-up of the cases is essential for the prognosis and healing of periapical lesion. A surgical approach might also be carried out in cases of persistent clinical symptoms or radiological factors which are irreversible in nature.

CONCLUSION

Apical patency is the technique most commonly used in root canal treatment to prevent debris collection at the apex and preparation of apical third of root canal. There are various techniques used for negotiating the patency of the root canal like the use of smallest binding file or used of electronic apex locator. With advances in apical patency all techniques have its own advantages and limitation so it is important to use the technique judiciously and minimize trauma to periapical tissue and respect the root apical anatomy.

REFERENCES

1. Garg N, Sharma S, Chhabra A, Dogra A, Bhatia R, Thakur S. Clinical evaluation of maintenance of apical patency in postendodontic pain: an in vivo study. *Endodontology*, 2017; 29: 115.
2. Ahmad MZ. Apical Patency or Apical Plug: A Literature Review. *Saudi Endod J.*, 2011; 1: 6.
3. Machado R, Ferrari CH, Back E, Comparin D, Tomazinho LF, Vansan LP. The impact of apical patency in the success of endodontic treatment of necrotic teeth with apical periodontitis: a brief review. *Iran Endod J*, 2016; 11: 63-66.
4. Khatavkar R, Hegde V. Importance of patency in endodontics. *Endod*, 2010; 22: 85-91.
5. Mohammadi Z, Jafarzadeh H et al. Establishing Apical Patency To be or not to be ? *J Contemp Dent Pract*, 2017; 18: 326-329.
6. Souza RA. The importance of Apical patency and cleaning of the apical foramen on Root canal preparation. *Braz Dent J*, 2006; 17: 6-9.
7. Salzgeber RM, Brilliant JD. An invivo evaluation of the penetration of an irrigating solution in root canals. *J.Endod*, 1977; 3: 394-398.

8. Buchanan LS. Cleaning and shaping the root canal system.in:Cohen S,Burns RC, editors. Pathway of the pulp,5th ed. St.Louis: CV Mosby, 1991; 166-192.
9. Vera J, Arias A, Romero M. Effect of maintaining apical patency on irrigant penetration into the apical third of root canals when using passive ultrasonic irrigant:as invivo study. J Endod, 2011; 37: 1276-1278.
10. GU LS, Kim JK, Ling J, Choi KK ,Pashley DH. Review of contemporary irrigant agitation techniques and devices. J Endod, 2009; 35: 791-804.
11. Ronaldo Araujo SOUZA. The Importance of Apical Patency and Cleaning of the Apical Foramen on Root Canal Preparation. Braz Dent J, 2006; 17: 6-9.
12. Baumgartner JC, Falkler WA. Bacteria in the apical 5mm of infected root canals. J Endod, 1991; 17: 380-383.
13. Wayman BE, Murata SM, Almeida RJ, Fowler CB. A bacteriological and histological evaluation of 58 periapical lesions. J Endod, 1992; 18: 152-155.
14. Deonizio MD, Sydney GB, Batista A, Pontaroto R. Influence of apical patency and cleaning of the apical foramen on periapical extrusion in retreatment. Braz Dent J, 2013; 24: 482-486.
15. Tsesis I, Ander B, TAMSE A, Kfir A. The effect of maintaining apical patency on canal transportation. Int Endod J, 2008; 41: 431-435.
16. Torabinejad M, Eby WC, Naidorf IJ. Inflammatory and immunological aspect of the pathogenesis of human periapical lesions. J Endod, 1985; 11: 479-88.
17. Goldberg F, Massone EJ. Patency file and apical transportation: an in vitro study. J Endod, 2002; 28: 510-511.
18. Izu KH, Thomas SJ, Zhang P, Izu AE, Michalek S. Effectiveness of sodium hypochlorite in preventing inoculation of periapical tissues with contaminated patency files. J Endod, 2004; 30: 92-94.
19. Cemal-Tinaz A, Alacam T, Uzun O, Maden M, Kayaoglu G. The effect of disruption of apical constriction on periapical extrusion. J Endod, 2005; 31: 533-535.
20. Schilder H. Cleaning and shaping the root canal. Dent Clin North Am, 1974; 18: 269-96.
21. Souza RA. The importance of apical patency and cleaning of the apical foramen on root canal preparation. Braz Dent J, 2006; 17: 6-9.
22. Wu MK, Wesselink PR, Walton RE. Apical terminus location of root canal treatment procedures. Oral Surg Oral Med Oral Pathol Oral Radiol Endod, 2000; 89: 99-103.
23. Ricucci D. Apical limit of root canal instrumentation and obturation, part 1. Literature review. Int Endod J, 1998; 31: 384-93.
24. Schaeffer MA, White RR, Walton RE. Determining the optimal obturation length: A meta-analysis of literature. J Endod, 2005; 31: 271-4.
25. Weine FS. Endodontic therapy, 5th edn, Mosby, St. Louis, 1996; 243.
26. Moura MS, Guedes OA, De Alencar AH, Azevedo BC, Estrela C. Influence of length of root canal obturation on apical periodontitis detected by periapical radiography and cone beam computed tomography. J Endod, 2009; 35: 805-9.
27. Siqueira JF Jr. Microbial causes of endodontic flare-ups. Int Endod J, 2003; 36: 453-63.
28. Siqueira JF Jr, Barnett F. Interappointment pain: Mechanisms, diagnosis, and treatment. Endod Topics, 2004; 7: 93-109.
29. Yusuf H. The significance of the presence of foreign material periapically as a cause of failure of root treatment. Oral Surg, 1982; 54: 566-74.
30. Siqueira JF Jr. Reaction of periradicular tissue to root canal treatment: Benefits and drawbacks. Endod Topics, 2005; 10: 123-47.
31. Grove CJ. Why root canals should be filled to the dentinocemental junction. J Am Dent Assoc, 1931; 19: 314-9.
32. Palmer MJ, Weine FS, Healey HJ. Position of the apical foramen in relation to endodontic therapy. J Can Dent Assoc, 1971; 37: 305-8.
33. Grove CJ. Why root canals should be filled to the dentinocemental junction. J Am Dent Assoc, 1930; 17: 293-6.
34. Coolidge ED. Anatomy of root apex in relation to treatment problems. J Am Dent Assoc, 1929; 16: 1456-65.
35. Ding J, Gutmann JL, Fan B, Lu Y, Chen H. Investigation of apex locators and related morphological factors. J Endod, 2010; 36: 1399-403.
36. Ricucci D, Langeland K. Apical limit of root canal instrumentation and obturation, part 2. A histological study. Int Endod J, 1998; 31: 394-409.
37. Sjögren U, Hägglund B, Sundqvist G, Wing K. Factors affecting the long-term results of endodontic treatment. J Endod, 1990; 16: 498-504.
38. Martinez-Lozano MA, Forner-Navarro L, Sanchez-Cortes JL, Llana-Puy C. Methodological considerations in the determination of working length. Int Endod J, 2001; 34: 371-6.
39. Stöber EK, Duran-Sindreu F, Mercadé M, Vera J, Bueno R, Roig M. An evaluation of Root ZX and iPex apex locators: An *in vivo* study. J Endod, 2011; 37: 608-10.
40. Meder-Cowherd L, Williamson AE, Johnson WT, Vasilescu D, Walton RE, Qian F. Apical morphology of the palatal roots of maxillary molars by using micro-computed tomography. J Endod, 2011; 37: 1162-5.
41. Chapman CE. A microscopic study of the apical region of human anterior teeth. J Br Endod Soc., 1966; 3: 52-8.
42. Chunn CB, Zardiackas LD, Menke RA. *In vivo* root canal length determination using the Foramer. J Endod, 1981; 7: 515-20.

43. Dummer PM, McGinn JH, Rees DG. The position and topography of the apical canal constriction and apical foramen. *Int Endod J*, 1984; 17: 192-8.
44. Schilder H. Filling root canals in three dimensions. *Dent Clin North Am*, 1967; 723-44.
45. Degerness RA, Bowles WR. Dimension, anatomy and morphology of the mesiobuccal root canal system in maxillary molars. *J Endod*, 2010; 36: 985-9.
46. Palmer MJ, Weine FS, Healey HJ. Position of the apical foramen in relation to endodontic therapy. *J Can Dent Assoc*, 1971; 37: 305-8.
47. Saunders WP, Saunders EM, Sadiq J, Cruickshank E. Technical standard of root canal treatment in an adult Scottish sub-population. *British Dental Journal*, 1997; 182: 382.
48. Vertucci FJ. Root canal anatomy of the human permanent teeth. *Oral Surg Oral Med Oral Pathol Oral Radiol*, 1984; 58: 589-99.
49. Al-Omari MA, Dummer PM. Canal blockage and debris extrusion with eight preparation techniques. *J Endod*, 1995; 21: 154-8.
50. Jiang LM, Lak B, Eijsvogels LM, Wesselink P, van der Sluis LW. Comparison of the cleaning efficacy of different final irrigation techniques. *J Endod*, 2012; 38: 838-41.
51. Chugal NM, Clive JM, Spångberg LS. Endodontic infection: some biologic and treatment factors associated with outcome. *Oral Surg Oral Med Oral Pathol Oral Radiol Endod*, 2003; 96: 81-90.
52. Wu MK, Wesselink PR, Walton RE. Apical terminus location of root canal treatment procedures. *Oral Surg Oral Med Oral Pathol Oral Radiol Endod*, 2000; 89: 99-103.
53. Gu L, Kim J, Ling J, Choi K. Review of contemporary irrigant agitation techniques and devices *J Endod*, 2009; 35: 791-804.