



## ESTHETIC REHABILITATION BY FIBER-REINFORCED COMPOSITE SPACE MAINTAINER FOR ANTERIOR MISSING TEETH IN PEDIATRIC PATIENT: A CASE REPORT

<sup>1</sup>Dr. Saraswathi V. Naik\*, <sup>2</sup>Dr. Devamatha Priyadarshini, <sup>3</sup>Dr. Mohammed Salman Ali, <sup>4</sup>Dr. Basappa N. and <sup>5</sup>Dr. Raju O.S.

Department of Pedodontics and Preventive Dentistry, Bapuji Dental College and Hospital.

\*Corresponding Author: Dr. Saraswathi V. Naik

Department of Pedodontics and Preventive Dentistry, Bapuji Dental College and Hospital.

Article Received on 30/05/2022

Article Revised on 20/06/2022

Article Accepted on 10/07/2022

### ABSTRACT

Dental trauma is generally affecting the teeth associated with soft tissue injuries and result in fractured, avulsion or lost anterior teeth. The fiber-reinforced composite represent an interesting alternative to conventional metal bridges and is suitable to replace a missing permanent anterior tooth, especially in growing child until a fixed prosthesis can be provided at the end of growth period. The aim of present clinical case report is to describe a conservative provisional treatment of the anterior missing tooth using fiber-reinforced composite. A 11-year-old girl reported with the chief complaint of missing tooth in upper front tooth region of jaw. Patient gave history of trauma resulted into avulsion of upper right central incisor. The treatment was planned to replace the edentulous space with an acrylic tooth bonded to fiber reinforced composite as a space maintainer. Patient was recalled after 1 week, 1 month, 6 months, 12 months and yearly for followup. FRC technique suggests an alternative treatment option for the temporarily replacement of a missing anterior tooth. Using this technique, it is possible to restore esthetics and function.

**KEYWORDS:** Fiber reinforced composite, Avulsion, Dental trauma, Space Maintainer.

### INTRODUCTION

Dental traumatic injuries are relatively prevalent among young patients. Dental trauma is generally affecting the teeth associated with soft tissue injuries and result in fractured, avulsion or lost anterior teeth. Studies reported frequencies of dental traumatic injuries ranging from 9.4%–41.6% in primary dentition. Traumatic injuries in permanent teeth have been reported to have a prevalence rate is 6.1% to 58.6%.<sup>[1]</sup>

Different therapeutic options can be considered for the replacement of a congenitally or traumatically missing permanent incisor in young children and adolescents which are removable partial denture, fixed partial denture and implant.<sup>[2]</sup> If the missing teeth are not replaced with a prosthetic appliance, adjacent teeth can migrate towards the edentulous alveolar ridge, leading to malocclusion and issues with dental eruption or it may cause development of secondary habit like tongue thrust or bruxism.<sup>[3]</sup>

Removable partial dentures (RPD) are often recommended for very young patients, especially in growing child, until a fixed prosthesis can be provided at the end of the growth period, where these dentures could be modified or altered when necessary.<sup>[2]</sup> The disadvantages of RPD include metallic appearance of the

clasp which is unacceptable for esthetic reason and are irritating to gingival tissue, resulting in denture induced trauma, acrylic resin is vulnerable to fracture,<sup>[4]</sup> lack of compliance in appliance wear and care by the young child is the greatest limitation of RPD.<sup>[3]</sup>

Implants are the treatment of choice and should be considered when general and local conditions are favorable. Their use is generally not intended before the end of the growth period and around the age of 18 years,<sup>[2]</sup> since implants cannot follow with the maxillary and mandibular growth processes of drift and displacement, resulting in unpredictable implant dislocations during growth.<sup>[5]</sup> High cost, poor financial condition could also limit their use. Hence, more economically acceptable treatments should be considered for the replacement of a missing tooth, as a main treatment or as a long-term provisional treatment before implant therapy.<sup>[2]</sup>

Fixed partial denture take support of adjacent teeth as abutment and restoring the missing teeth as pontics. Different type of material used for FPD which are metal, ceramic, acrylic, or composite resin. FPD are usually avoided in young, actively growing patients as they could prevent jaw growth, especially if prosthesis crosses the midline.<sup>[6]</sup>

The fiber-reinforced composite (FRC) represent an interesting alternative to conventional metal bridges (conventionally fixed partial metal-ceramic restorations). They could be made directly or indirectly using an artificial acrylic tooth or the avulsed tooth, or by a direct build up composite resin tooth with or without porcelain veneering.<sup>[2]</sup> Valentina Pankratz et al have reported FRC is suitable to replace a missing permanent anterior tooth, especially in growing child until a fixed prosthesis can be provided at the end of growth period. Advantages of FRC include bondability, chairside ease of fabrication and repairability, it is both economical and less time consuming as the fabrication can be performed in a single appointment. It is non-invasive and reversible.<sup>7</sup> Unlu and Belli et al have reported a mean survival period of 3 and 4.5 year respectively, for fixed FRC which makes it suitable interim treatment for replacing for missing permanent anterior teeth in child patients until a definitive restoration can be provided. Passivity and Flexibility of FRC allows both contention and physiological dental movement.<sup>[3]</sup>

The present clinical case report describes a conservative provisional treatment of the anterior missing tooth using fiber-reinforced composite.

### CASE REPORT

An 11-year-old girl came to Department of Pedodontics and Preventive Dentistry, Bapuji Dental College and Hospital with the chief complaint of missing tooth in upper front tooth region of jaw. Patient gave history of trauma from self-fall 6 months back which resulted into avulsion of upper right central incisor. Patient desired for esthetic, economical and functional treatment for the same. On clinical examination mixed dentition with missing 21. Teeth present were

16	55	54	53	12	11	22	63	64	65	26
46	85	84	83	42	41	31	32	73	74	36

Bilaterally angle's class I Malocclusion with 2mm overjet and overbite was present.

On radiographic examination edentulous space with well healed bone were observed. (Figure no. 1). Concerning the aesthetic needs of this young girl, the treatment was planned to replace the edentulous space with an acrylic tooth bonded to fiber reinforced composite as a space maintainer. After early clinical results, the alginate impression was made followed by making diagnostic model and working model. (Figure no. 2)

After Tanaka-Johnston analysis, there was space available in the arch for the unerupted teeth, so it was planned to give esthetic space maintainer using reinforced fiber composite. Fiber-Reinforced composite was measured from distal surface of 22 to distal surface of 12 with a dental floss and required length was accessed and cut. The fibers was embedded to bonding agent placing it under a cover to avoid light absorption. Tooth shade was matched using shade guide (VITA classical) and an acrylic tooth of shade A2 with proper

size was selected and then acrylic tooth was cleaned with fine pumice using a micro motor and micro brush and rinsed with air-pressure spray. In order to acquire a mechanical strength, a groove was prepared at midpalatal surface on the acrylic tooth. Mesial and distal contours of acrylic tooth were extended to fit the edentulous space area with FRC material in working model, then the material was polymerized, and two free arm of composite fibers were adapted to adjacent tooth in cast. (Figure no. 3, 4, 5, 6)

Putty index were prepared to restore the proper position of artificial tooth with relation to adjacent natural teeth. (Figure no. 7) After that, patient was recalled for final restoration. The palatal surface of 11 and 22 were etched with 37% phosphoric acid for 20 s and then rinsed for 15s. and air-dried. The bonding agent was applied and light polymerized with a light curing device. (Figure no. 8) The indirect restoration with arm of composite fibre were positioned properly and putty index was placed and evaluated for the occlusion (Figure no 9). The flowable composite resin was applied on the palatal surfaces of adjacent teeth and light-cured. Finally, occlusion was adjusted with articulating paper, premature contacts were eliminated, and esthetic contouring of the restoration was done. The restoration was finished and polished. (Figure no. 10) Patient was recalled after 1 week, 1 month, 6 months, 12 months and yearly for followup.

### DISCUSSION

Fiber reinforced composite (FRC) is an interesting alternative for replacing a missing permanent anterior tooth in growing child. FRC materials consist of glass, carbon, or polyethylene fibers contained within a resin matrix. The type of fiber, the fiber architecture, and the quality of the fiber/matrix coupling determine the mechanical properties of the material like Stiffness, strength, toughness and less fatigue. Fibers produce a load enhancing effect on the brittle composite materials by acting as stress-bearing component and by crack-stopping or crack-deflecting mechanisms. Laboratory studies have shown that FRC materials exhibit flexure strength that is comparable to or greater than that of metal alloys. FRC offer a suitable alternative to replace a missing permanent anterior tooth, especially in a growing child until a fixed prosthesis can be provided at the end of growth period.<sup>[3]</sup>

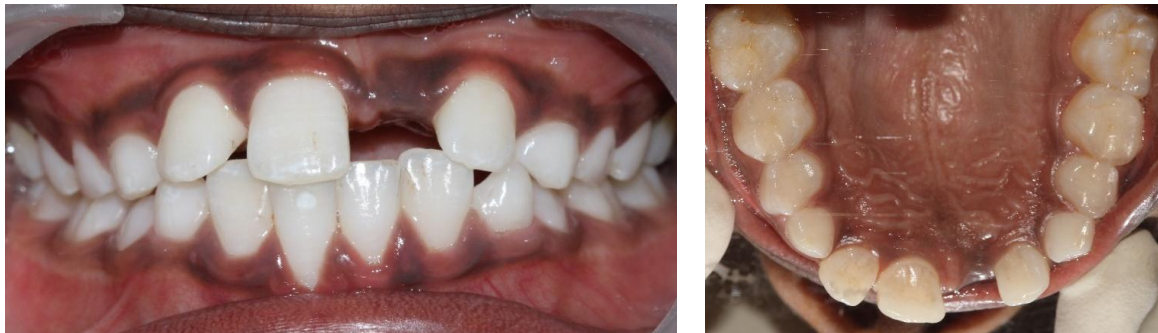The method described in this case is based on bonding an acrylic tooth to Fiber reinforced composite resin. Tayab T et al reported the use of natural teeth as pontic in such FRC-fixed prosthesis. Although an acrylic tooth as a pontic have been successfully used with reinforced composite resins. Since the early 1990s, polyethylene ribbon (RibbondTM) has been used for the treatment of anterior missing teeth, reinforcement of provisional artificial resin-fixed partial dentures. In present case because of edentulous space for 6 months lead to supra eruption of lower central incisors due to which the restored tooth was kept out of the occlusion. Many

treatment alternatives are present for a fixed partial prosthesis, but the esthetic superiorities of FRC frameworks to conventional fixed partial prosthesis with metal frameworks should be considered before the treatment. Clinical usage and clinical research have shown that FRC prostheses can be used to satisfactorily restore or replace teeth with fixed prostheses.<sup>[9]</sup>

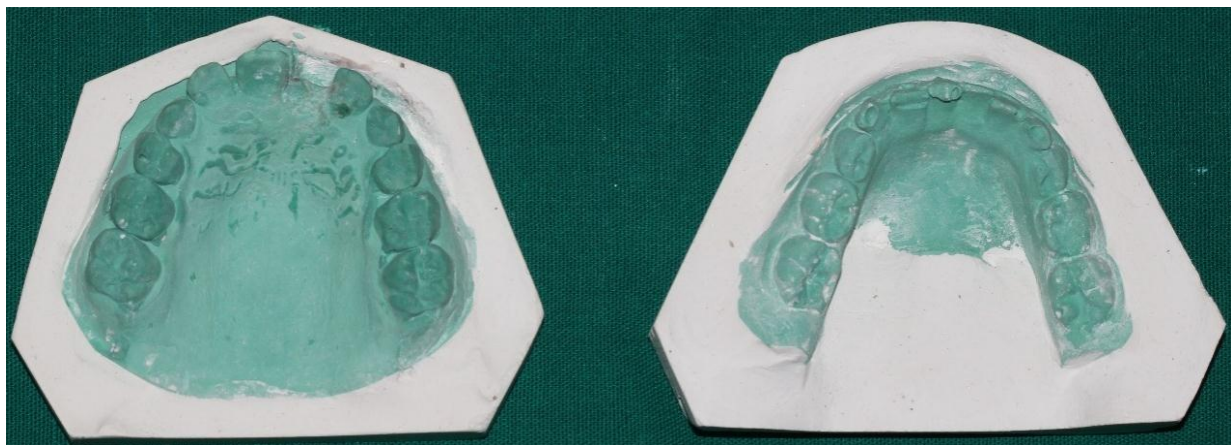
Bagis B et al reported bonding of the surface-retained adhesive restoration to adjacent teeth and preparing the grooves on all adjacent teeth are also important for the

success of FRC. Therefore, bonding procedures should be carried out carefully to increase the retention, adhesion, and mechanical durability of the adhesive bridge restorations.<sup>[9]</sup>

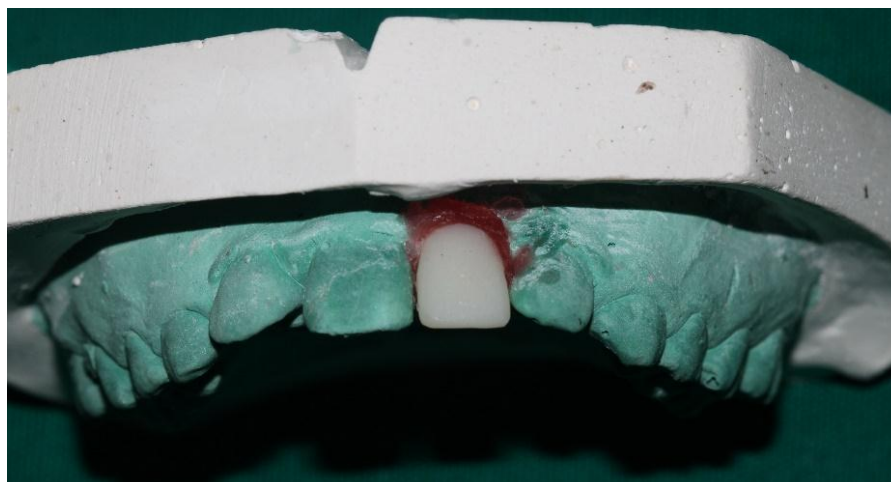
However, disadvantages include difficulty in maintaining the oral hygiene and its questionable ability to withstand heavy masticatory load. Hence, fixed FRC bridges might offer a metal-free and clinically permanent anterior tooth, but further studies are needed to verify the success of these FRC.



**Figure 1: Pre-operative photographic showing missing upper left central incisor.**



**Figure 2: Diagnostic model / Working model.**



**Figure 3: Acrylic tooth of shade A2 with proper size.**

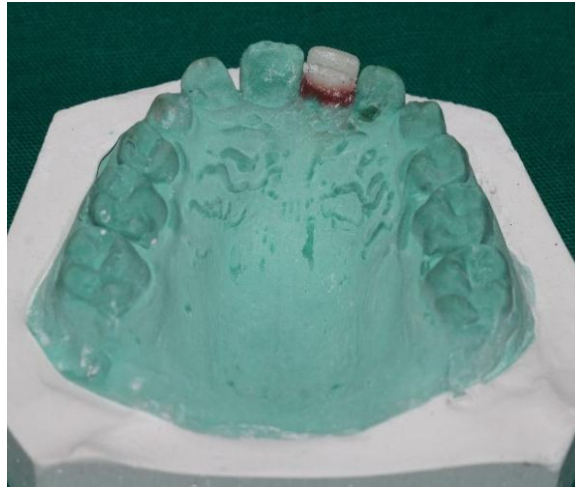


Figure 4: Groove prepared at midpalatal surface on the acrylic tooth.

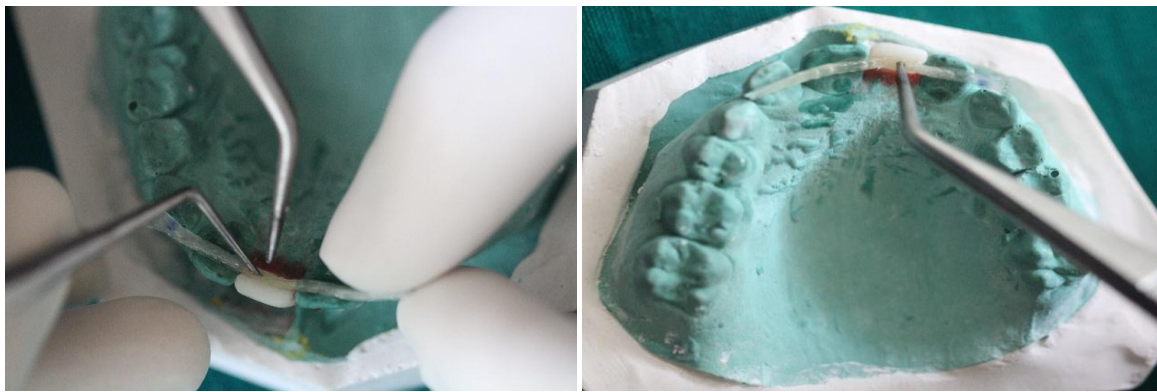

Figure 5: Mesial and distal contours of acrylic tooth.

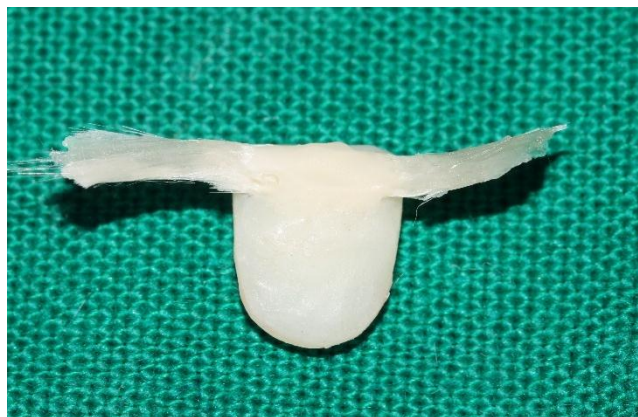

Figure 6: Two free arm of composite fibers were adapted to adjacent tooth in cast.

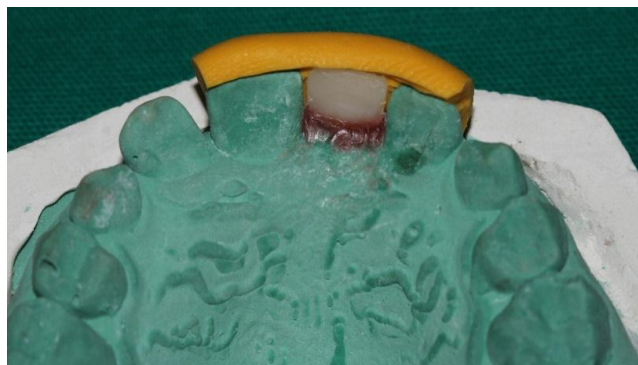
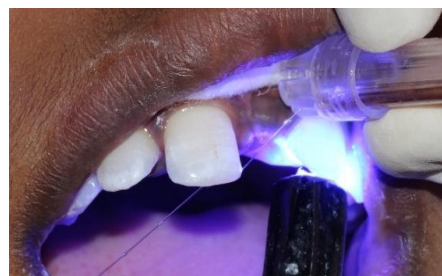
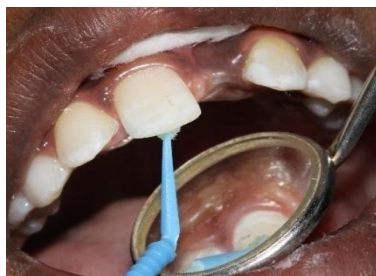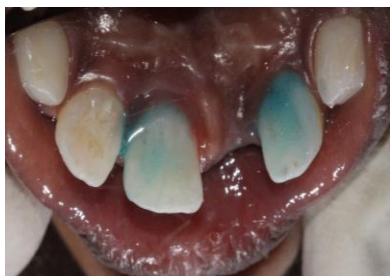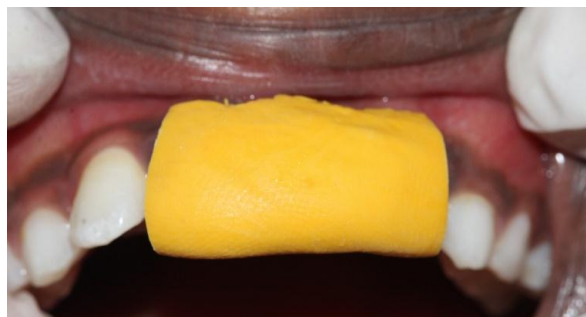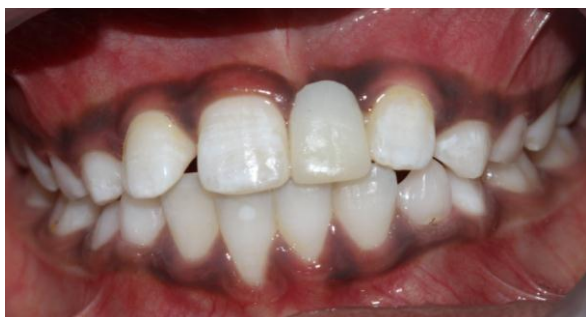Figure 7: Putty index prepared to restore the proper position of artificial tooth.



**Figure 8:** 37% phosphoric acid for 20 sec, rinsed for 15 sec and air-dried. The bonding agent was applied and light polymerized.



**Figure 9:** The indirect restoration with arm of composite fiber positioned with putty index.



**Figure 10:** Post Restoration photograph.

## CONCLUSION

FRC technique suggests an alternative treatment option for the temporarily replacement of a missing anterior tooth. Using this technique, it is possible to restore esthetics and function. It is more comfortable than a removable appliance, nonirritating, and hygienic. In the present case, FRC provided minimal preparation on the adjacent teeth. Clinical long-time studies have to show whether it can also serve as a permanent restoration.

## REFERENCES

1. Juneja P, Kulkarni S, Raje S. Prevalence of traumatic dental injuries and their relation with predisposing factors among 8-15 years old school children of Indore city, India. *Clujul Med.*, 2018; 91(3): 328-335.
2. Singh M, Khan A, Ansari A, Sharma K, Sharma S. Esthetic rehabilitation of anterior missing teeth by fiber-reinforced composite: A Case Report. *J. res. Adv. Dent.*, 2021; 12(3): 50-54.
3. Gupta A, Yelluri RK, Munshi AK. Fiber-reinforced composite resin bridge: a treatment option in

children. *Int. J. Clin. Pediatr. Dent.*, Jan, 2015; 8(1): 62.

4. Song K, Nam O, Kim M, Lee H, Choi S. Management of premature loss of primary molars with flexible denture. *J. Korean acad. pediatr. dent.*, 2016; 43(2): 187-91.
5. Kramer FJ, Baethge C, Tschernitschek H. Implants in children with ectodermal dysplasia: a case report and literature review. *Clin. Oral Implants Res.*, Feb, 2007; 18(1): 140-6.
6. Al Nuaimi R, Mansoor M. Prosthetic rehabilitation with fixed prosthesis of a 5-year-old child with Hypohidrotic Ectodermal Dysplasia and Oligodontia: a case report. *J. Med. Case Rep.*, Dec, 2019; 13(1): 1-6.
7. Pankratz V, Zimmer S, Marković L. Anterior fiber-reinforced ribbon composite resin bridge—A case report. *Clinical case reports*, Oct, 2018; 6(10): 1941.
8. Vulićević Z, Beloica M, Kosanović D, Radović I, Juloski J, Ivanović D. Prosthetics in paediatric dentistry. *Blak J Dent Med.*, 2017; 21(2): 78-82.
9. Cevik P, Eraslan O. Rehabilitation of an extracted anterior tooth area using bondable reinforcement ribbon and the artificial tooth *J Prosthodont*, 2006; 15: 316-20.