

**ALLERGIC BRONCHOPULMONARY ASPERGILLOSIS MISDIAGNOSED AS
PULMONARY TUBERCULOSIS****Dr. Tushar Bansal*, Dr. N. C. Kajal**, Dr. Kunal Bansal*** Dr. Shagun* and Dr. Satish Oberol******

*Junior Resident, Department of Pulmonary Medicine, Govt. Medical College, Amritsar.

**Professor, Department of Pulmonary Medicine, Govt. Medical College, Amritsar.

***Medical Officer (M.D Medicine), Civil Hospital Amritsar.

****Intern, Govt. Medical College, Amritsar.

***Corresponding Author: Dr. Tushar Bansal**

Junior Resident, Department of Pulmonary Medicine, Govt. Medical College, Amritsar.

Article Received on 26/04/2022

Article Revised on 16/05/2022

Article Accepted on 06/06/2022

ABSTRACT

Allergic bronchopulmonary aspergillosis (ABPA) is frequency misdiagnosed as pulmonary tuberculosis. The differential diagnosis of ABPA should be considered before diagnosis and treatment of smear-negative pulmonary tuberculosis. Undiagnosed allergic bronchopulmonary aspergillosis (ABPA) can lead to chronic persistent symptoms. Due to chronicity of symptoms in countries like India where tuberculosis (TB) is widespread, a considerable number of ABPA patients are misdiagnosed as smear negative TB before being diagnosed with ABPA. This results in empiric use of ATT (Anti-tuberculous therapy) and delay in initial diagnosis of ABPA. Here we present a case of ABPA which was misdiagnosed as smear negative pulmonary tuberculosis before reaching our hospital.

KEYWORDS: Allergic bronchopulmonary aspergillosis; asthma; pulmonary tuberculosis.**INTRODUCTION**

Aspergillus presents with variety of clinical syndromes in the lung, ranging from aspergilloma in patients with lung cavities, to chronic necrotizing aspergillosis in those who are mildly immunocompromised or having chronic lung disease, but most commonly presents as ABPA.

Allergic bronchopulmonary aspergillosis (ABPA) is a hypersensitive reaction to a fungus known as *Aspergillus fumigatus*. Allergic bronchopulmonary aspergillosis is a rare disease in which cystic bronchiectasis is a common feature with prevalence ranging from 5 to 15%.^[1-7] It is most commonly found in patients with long standing asthma (1-5%) and cystic fibrosis (2-15%) and present with recurrent attacks of fever, malaise, hemoptysis, bronchial obstruction, expectoration of brownish mucous plugs and peripheral eosinophilia.^[8,9] It occurs due to exposure of the asthmatic bronchial tree to *Aspergillus Fumigatus* (AF) which may lead to hypersensitivity reaction resulting in eosinophilic infiltration of the bronchial wall and mucoid impaction or granulomatous inflammation.^[10,11] Repeated episodes of bronchial obstruction, inflammation and mucoid impaction can lead to bronchiectasis, fibrosis and respiratory impairment.^[12] Therefore ABPA should be kept as one of the differentials in mind in patients who presents with uncontrolled asthma. Haemoptysis is a common symptom of ABPA and is seen in almost 31% of people with ABPA. Haemoptysis in the presence of radiological

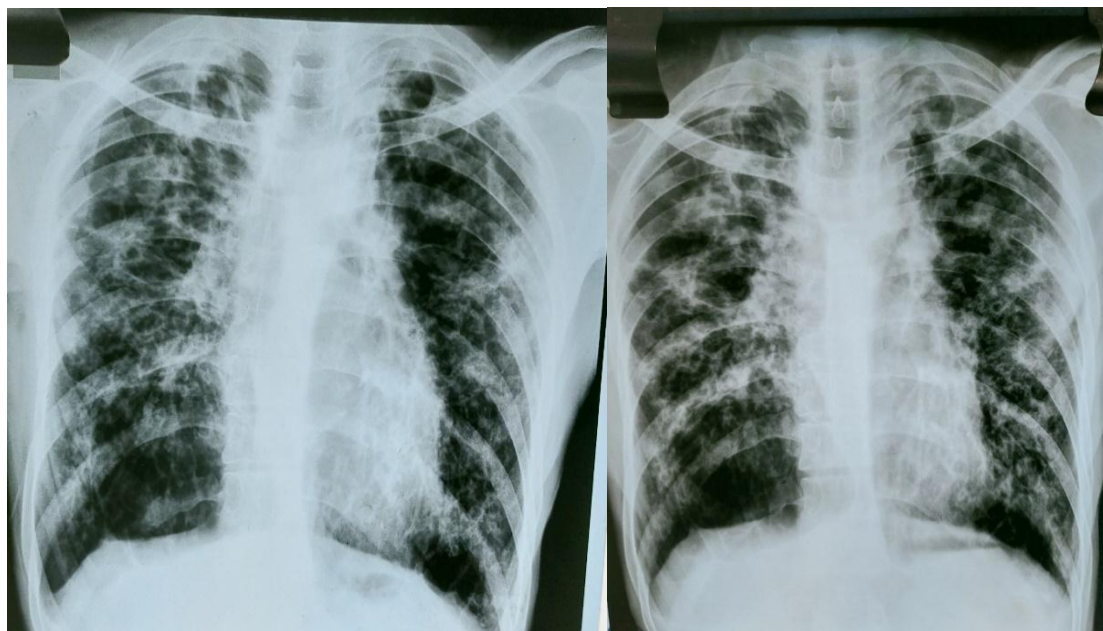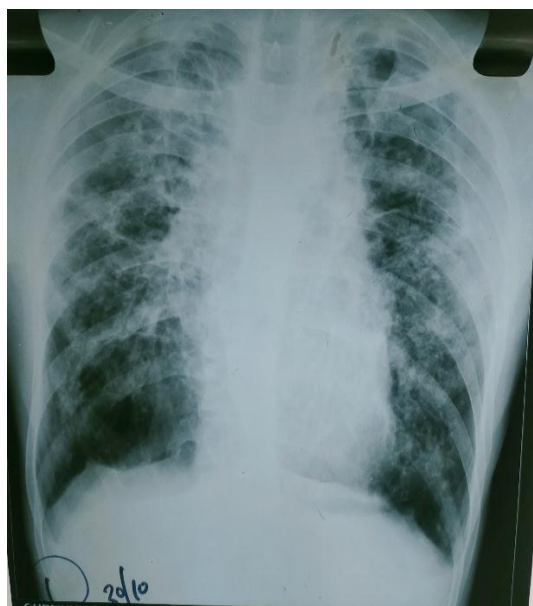
cavitating lesions due to bronchiectasis looks like pulmonary tuberculosis and also since pulmonary tuberculosis is much more common than ABPA, some patients with ABPA are misdiagnosed and are treated as a case of smear negative pulmonary tuberculosis. In one study from India almost one 3rd of the 35 patients with ABPA were misdiagnosed as pulmonary tuberculosis and were treated with antitubercular therapy for long period of time.^[13] ABPA was first described by Hinson et al in 1957.^[14] A delayed diagnosis of ABPA due to misdiagnosis as a case of pulmonary tuberculosis not only exposes the patient unnecessarily to ATT but can also lead to a number of ABPA associated complications including bronchiectasis, pulmonary fibrosis, respiratory failure and progressive lung damage eventually leading to death.^[15]

CASE REPORT

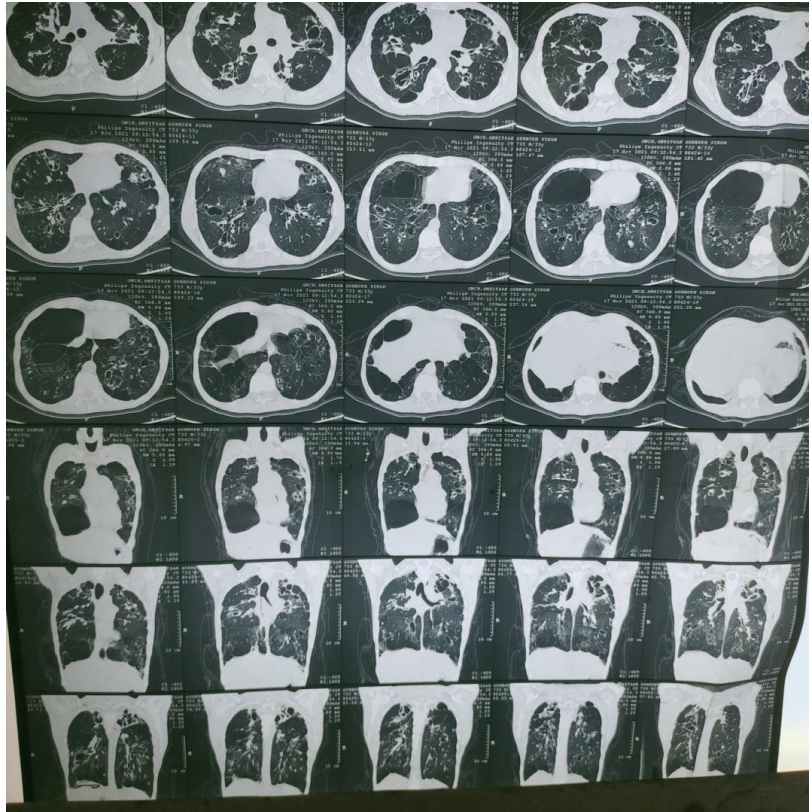A 33 years old male patient was referred to this hospital with chief complaints of cough, breathlessness, whistling of chest and fever for the last 1 month. There was no history of haemoptysis. The patient was put on ATT on the basis of clinicoradiological findings for the last 15 days. The patient also has history of taking antitubercular treatment 15 years back. We got the CT chest done which reveals multiple centriacinar nodular opacities arranged in linear branching pattern forming "tree in bud appearance" in right upper lobe, right middle lobe, superior segments of bilateral lower lobes. Fibronodular

changes in bilateral lung fields with cylindrical, varicose and cystic type of bronchiectatic changes. Paraseptal emphysematous changes bilaterally with bulla formation in right middle lobe measuring 8.2*6.4 cm in size. f/s/o old pulmonary koch's with reactivation. Patient's Sputum for AFB was negative and in sputum for CBNAAT mycobacterium tuberculosis was not detected. Sputum for G/S and C/S showed normal flora. RTPCR for covid was negative. There was no history of I.V. drug abuse. Viral markers were negative. Patient was non-alcoholic, non-smoker. Detailed history from patient revealed history of seasonal variations. On auscultation bilateral rhonchi with occasional crepts were present.

Since there was no relief of symptoms after tuberculosis treatment and history of seasonal variations diagnosis of allergic bronchopulmonary aspergillosis (ABPA) was considered. Sputum for fungus showed thin septate hyphae suggestive of aspegillus species. Total serum IGE levels were >2500. Aspergillus fumigatus serum levels (FEIA) were 14.40 KUA/lt. Aspergillus fumigatus specific IGE levels were 298mgA/lt. Serum AEC levels were 324. Diagnosis of ABPA was made and anti-tubercular treatment was stopped and patient was started on cap itraconazole 200mg b.d. and tab prednisolone 30 mg OD and was nebulized with ICS and LABA.

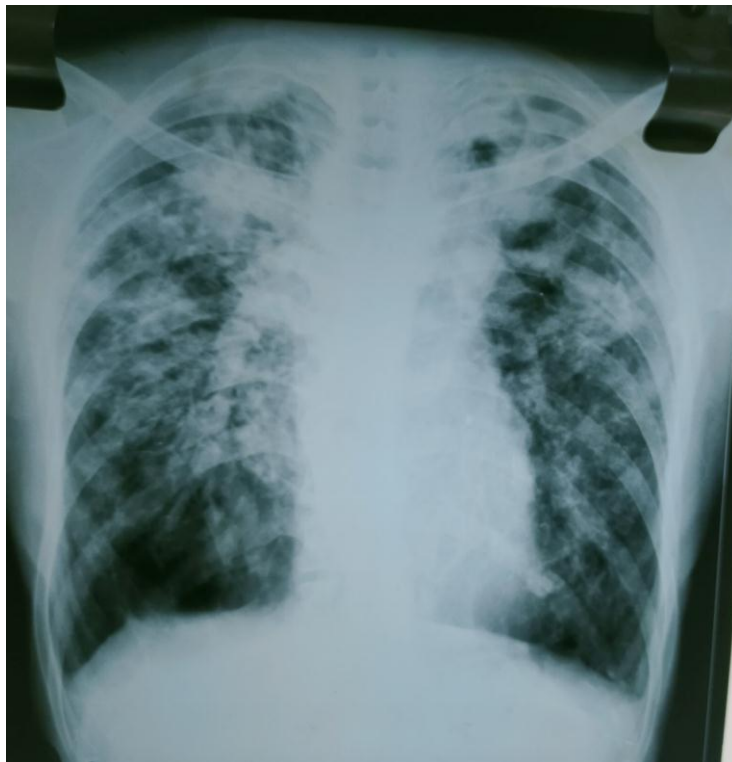

X-RAY CHEST SHOWS BILATERAL HETEROGENOUS OPACITIES AND CAVITY IN RIGHT MIDDLE ZONE AND WAS STARTED ON ATT AS A CASE OF SMEAR NEGATIVE TUBERCULOSIS

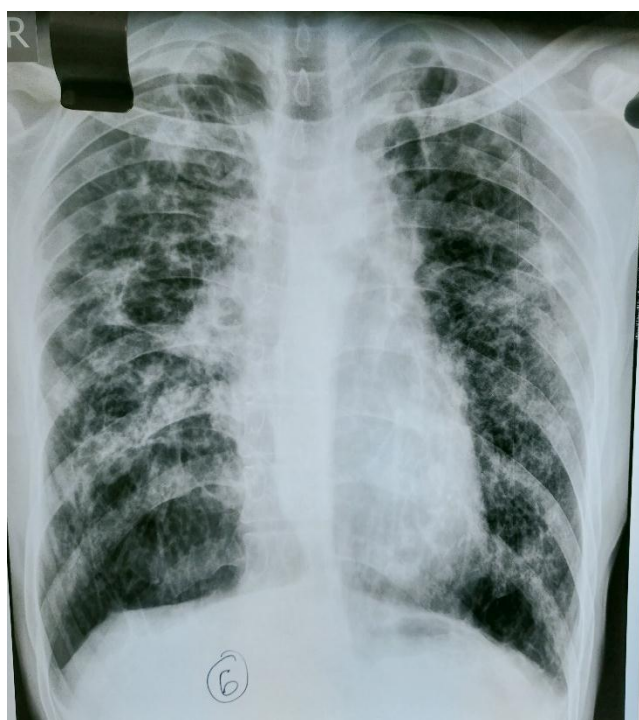
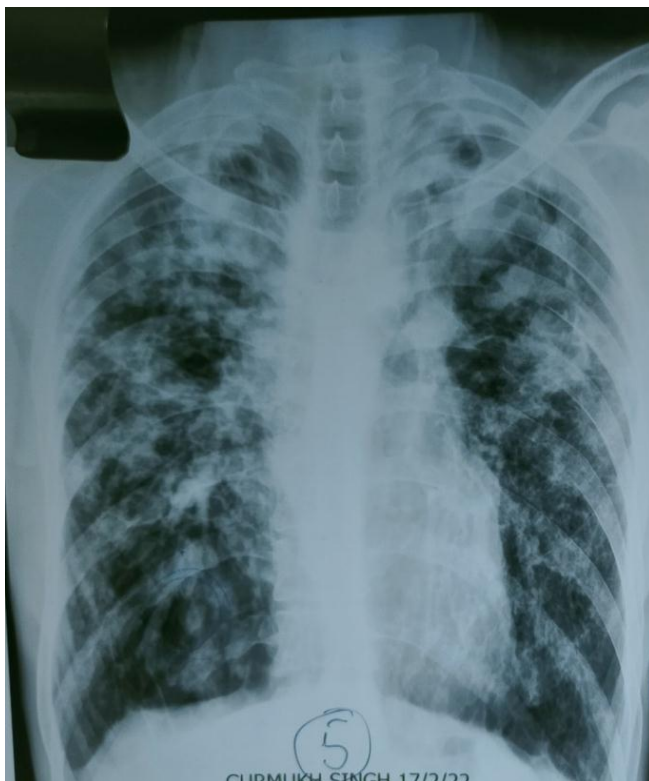

CECT CHEST - showed multiple centriacinar nodular opacities arranged in linear branching pattern forming "tree in bud appearance" in right upper lobe, right middle lobe, superior segments of bilateral lower lobes. Fibronodular changes in bilateral lung fields with

cylindrical, varicose and cystic type of bronchiectatic changes. Paraseptal emphysematous changes bilaterally with bulla formation in right middle lobe measuring 8.2*6.4 cm in size. f/s/o old pulmonary koch's with reactivation.



PATIENT CAME WITH DETERIORATION AFTER TAKING ATT.
HETEROGENOUS OPACITIES WERE INCREASED IN BILATERAL LUNG FIELDS.



PATIENT WAS DIAGNOSED AS A CASE OF ABPA AND WAS STARTED ON ANTI-FUNGAL AND SERIAL X-RAYS OF CHEST SHOWS IMPROVEMENT.

DISCUSSION

Allergic bronchopulmonary aspergillosis (ABPA) is a hypersensitive reaction to a fungus known as *Aspergillus fumigatus*. Allergic bronchopulmonary aspergillosis is a rare disease in which cystic bronchiectasis is a common feature with prevalence ranging from 5 to 15%.^[1-7] It is most commonly found in patients with long standing asthma(1-5%) and cystic fibrosis(2-15%) and presents

with recurrent attacks of fever, malaise, hemoptysis, bronchial obstruction, expectoration of brownish mucous plugs and peripheral eosinophilia.^[8,9] It occurs due to exposure of the asthmatic bronchial tree to *Aspergillus Fumigatus* (AF) which may lead to hypersensitivity reaction resulting in eosinophilic infiltration of the bronchial wall and mucoid impaction or granulomatous inflammation.^[10,11] *Aspergillus fumigatus* spores enter

the respiratory airways by inhalation and because to their larger size (3-5 μm) they impact in the larger bronchi which is the same site as of central bronchiectasis lesions. Although ABPA is more commonly occurs in young adults, but has also been recorded in children.^[16] The host factor determines the pathogenicity of ABPA in host. ABPA is caused by imbalance between Th1 and Th2 responses, causing predominant Th2 response to *Aspergillus* leading to ABPA. Around 25% patient of asthma are sensitised to *Aspergillus*, however only few percentage of them develop ABPA. Stage 1 (acute), Stage 2 (remission), Stage 3 (reoccurrence/exacerbation), Stage 4 (steroid dependent), and Stage 5 (fibrotic lung disease) are five phases of ABPA, but patient may not progress through them in that order.^[17] Based on radiological and serological investigations, patients are also classified as ABPA-central bronchiectasis, ABPA-seropositive, and ABPA-central bronchiectasis with other radiological abnormalities. The diagnostic criteria of ABPA is based on predisposing conditions, obligatory criteria and other criteria. The predisposing condition for diagnosis includes (one must be present) history of asthma or cystic fibrosis. Obligatory criteria (both should be present) includes total serum IgE level >1000 ng/ml and elevated serum IgG specific to *Aspergillus fumigatus* (>0.35 KUA/L) or immediate skin reactivity of AF antigen. Other criteria includes elevated serum IgG specific to *Aspergillus fumigatus* (>27 mgA/L) or precipitating serum antibodies to AF, peripheral blood eosinophilia >500 /microlitre, radiographic pulmonary infiltrate consistent with ABPA.

In this case, although the sputum and bronchial lavage was negative for AFB as well as tuberculin test of patient was negative, this patient was first misdiagnosed with pulmonary tuberculosis due to the appearance of the lung cavitating lesions (bronchiectasis) and constitutional symptoms. Since pulmonary tuberculosis is much more common than ABPA in our country, therefore, our physicians are more familiar with tuberculosis rather than ABPA.

Due to similarity in clinical symptoms of tuberculosis and ABPA i.e fever, chronic cough, weight loss, haemoptysis and chest x ray opacities and also because of endemicity of tuberculosis in India, it is difficult to diagnose or even suspect ABPA on first OPD visit and also lack of suspicion and awareness is an important cause for misdiagnosis of ABPA. There is a significant association between haemoptysis and the smear negative TB group treated with anti-tubercular treatment therapy. This finding can be explained by the progressive lung damage that occurs in ABPA patients who were misdiagnosed as pulmonary TB and were not appropriately treated for ABPA. Ideally, an acid-fast bacillus smear test can help distinguish between TB and ABPA, but the real problem arises in ruling out ABPA in patients who are both smear and Gene xpert negative for TB. The pattern of bronchiectatic changes in ABPA is different from that in pulmonary tuberculosis. The

bronchiectatic changes in ABPA involves the proximal segments of bronchi proximal or central bronchiectasis.^[18] while in pulmonary tuberculosis the bronchiectatic changes affects the distal segments and commonly affect the upper lobes and results in dry bronchiectasis.^[18,19] The bronchiectatic changes in ABPA are caused by an immunological process where as pulmonary tuberculosis is caused by an infectious process that causes damage of the lung parenchyma with replacement of alveoli by fibrous tissue, as a result this leads to parenchymal retraction and secondary bronchial dilatation. The differential diagnosis of a cavitating pulmonary lesion includes causes such as pneumonias, bronchogenic carcinoma, Wegner's granulomatosis, cystic bronchiectasis, lung abscess, septic emboli and ABPA, besides tuberculosis. In pulmonary tuberculosis the cavitating lesions usually occur in the apical and posterior segments of the upper lobes (80%-90% of the patients) followed by the apical segment of the lower lobes. In ABPA, the chest radiograph may show homogenous, finger like shadows in a bronchial distribution which are usually transient, usually affects the upper lobes and almost always in proximal bronchi rather than the distal ones. Resolution of the mucoid impaction may reveal cylindrical or sacular bronchiectasis. High resolution CT chest is more sensitive and may help to differentiate ABPA from pulmonary TB. In ABPA, CT may show widespread proximal bronchiectasis affecting 3 or more lobes, centrilobular nodules, and mucoid impaction.^[20] while in pulmonary tuberculosis it shows smaller cavitating lesions located at the apex of the lung and may also show the characteristic centrilobular lesions, nodules and branching linear densities called a "tree in bud" appearance. Sputum positivity for fungus examination for ABPA ranges from 15.3 to 82.6%.^[21] In this case radiological and serological investigations were sufficient to confirm the diagnosis. Serum IgE level were raised with raised *Aspergillus* specific IgE levels, but it may be low in fibrotic lung disease, during remission and patients on oral steroid.^[22] Immediate skin reactivity was not done because it was not available. Most important clue which was missed or ignored was wheeze on initial examination though endobronchial tuberculosis can also mimic as bronchial asthma.

Controlling inflammation that damages lung tissue with systemic corticosteroid treatment and reducing fungal antigen load by antifungal treatment (also acts as steroid sparing effect) are the two key components of ABPA treatment.^[23] Steroid treatment is started at 0.5-2 mg/kg/day (maximum daily dose 60 mg). After 1-2 weeks, the steroid dose is gradually reduced by evaluating symptoms, spirometric, and radiographic findings and serum IgE levels. A 30-50% reduction in IgE levels is considered significant. IgE levels need to be monitored throughout treatment. If the response to steroid therapy is poor, or relapse occurs, or if steroid-related side effects develop, itraconazole should be added to antifungal drugs. The use of itraconazole

reduces the need and duration of steroid use.^[23,24] Itraconazole is used as a dose of 5 mg/kg/day. The maximum dose is 400 mg/day, and the duration of treatment is 3-6 months. Liver function tests should be done one month after the initiation of itraconazole treatment and values should be monitored after every 3-6 months.^[23] Some doctors prefer to use voriconazole instead of itraconazole because voriconazole has better gastrointestinal tolerance. Omalizumab is another treatment option for ABPA, especially in poorly controlled asthmatic patients, which is given as 375 mg subcutaneously twice a month.

In one study from India almost one 3rd of the 35 patients with ABPA were misdiagnosed as pulmonary tuberculosis and were treated with antitubercular therapy for long period of time.^[9] A 2006 study in India showed that out of 126 patients presenting to a chest clinic with ABPA, 59 were initially misdiagnosed as pulmonary TB and received anti-tubercular treatment.^[25] Similarly, a 2009 retrospective study revealed that 91% of patients with ABPA were initially diagnosed with pulmonary TB and were prescribed anti-tubercular treatment.^[26]

CONCLUSION

ABPA is an under recognized entity in india and is often mistakenly diagnosed as smear negative pulmonary TB due to similar clinical and radiological features. Prolongation in diagnosis of ABPA can cause progressive lung damage which can lead to fibrosis and respiratory failure. We presented this case to emphasize that ABPA should be considered in differential diagnosis, especially in patients with asthma or cystic fibrosis before clinical and radiological diagnosis of smear- negative pulmonary tuberculosis is made, especially in uncontrolled asthma patients. 'All wheezes are not asthma' and 'Every cough more than 2 weeks should be evaluated for tuberculosis but should not be treated in hastel as smear negative tuberculosis.

REFERENCES

- Nelson LA, Callerame ML, Schwartz RH. Aspergillosis and atopy in cystic fibrosis. *Am Rev Respir Dis.*, 1979; 120: 863-873.
- Laufer P, Fink JN, Bruns WT, Unger GF, Kalbfleisch JH, Greenberger PA et al. Allergic bronchopulmonary aspergillosis in cystic fibrosis. *J Allergy Clin Immunol*, 1984; 73: 44-48.
- Mroueh S, Spock A. Allergic bronchopulmonary aspergillosis in patients with cystic fibrosis. *Chest*, 1994; 105: 32-36.
- Geller DE, Kaplowitz H, Light MJ, Colin AA. Allergic bronchopulmonary aspergillosis in cystic fibrosis. Reported prevalence, regional distribution, and patient characteristics. Scientific Advisory Group, Investigation, and Coordinators of the Epidemiological Study of Cystic Fibrosis. *Chest*, 1999; 116: 639-646.
- Schwartz HJ, Greenberger PA. The prevalence of allergic bronchopulmonary aspergillosis in patients with asthma, determined by serologic and radiologic criteria in patients at risk. *J Lab Clin Med*, 1991; 117: 138-142.
- Greenberger PA, Patterson R. Allergic bronchopulmonary aspergillosis and the evaluation of the patients with asthma. *J Allergy Clin Immunol*, 1988; 81: 646-650.
- Schwartz HJ, Citron KM, Chester EH, Kaimal J, Barlow PB, Bauma G et al. A comparison of the prevalence of sensitization to Aspergillus antigen among asthmatics in Cleveland and London. *J Allergy Clin Immunol*, 1978; 62: 9-14.
- Greenberger P A, Patterson R. Diagnosis and management of allergic bronchopulmonary aspergillosis. *Ann Allergy*, 1986; 56: 444-448.
- Wardlaw A, Geddes DM. Allergic bronchopulmonary aspergillosis: a review. *J R Soc Med*, 1992; 85: 747-751.
- Patterson R, Greenberger PA, Halwig JM, Liotta JL, Roberts M. Allergic bronchopulmonary aspergillosis. Natural history and classification of early disease by serologic and roentgenographic studies. *Arch Inter Med*, 1986; 146: 916-918.
- Lee TM, Greenberger PA, Patterson R, Roberts M, Liotta JL. Stage V (fibrotic) allergic bronchopulmonary aspergillosis. *Arch Intern Med*, 1987; 147: 319-323.
- Reiff DB, Wells AU, Carr DH, Cole PJ, Hansell DM. CT findings in bronchiectasis: Limited value in distinguishing between idiopathic and specific types. *American Journal of Radiology*, 1995; 165: 261-267.
- Behera D, Guleria R, Jindal SK, Chakrabarti A, Panigrahi D. Allergic bronchopulmonary Aspergillosis: a retrospective study of 35 cases. *Indian J Chest Dis Allied Sci.*, 1994; 36: 173-179.
- Hinson KF, Moon AJ, Plummer NS. Bronkopulmonary aspergillosis. a reviewand eight cases. *Thorax*, 1952; 7: 317-33.
- Al-Saleh AA, Farid E, Makhloq M, Mahdi M, Reda M, Zaid T, Al-Alawi S, Panjwani A, Salman N, Ali HR, Bindayna K. Allergic aspergillosis in asthmatic patients in a tertiary hospital in the Kingdom of Bahrain. *Journal of laboratory physicians*, 2019; 11(4): 373.
- Slavin RG, Laird TS, Cherry JD. Allergic bronchopulmonary aspergillosis in a child. *J Pediatr*, 1970; 76: 416-21.
- Greenberger PA. Allergic bronchopulmonary aspergillosis. *J Allergy Clin Immunol*, 2002; 110: 685-92. Back to cited text no. 5.
- Fraser RS, Paré JAP, Fraser RG, Paré PD. In: *Synopsis of Disease of the Chest*. 2nd ed. New York: WB Saunders Company, 1994; 677-683.
- Fraser RS, Paré JAP, Fraser RG, Paré PD. In: *Differential diagnosis of disesae of the chest*. New York: WB Saunders, 1991; 12-20.
- Ward S, Heyneman L, Lee MJ, Leung AN, Hansel DM, Muller NL. Accuracy of CT in the diagnosis of allergic bronchopulmonary aspergillosis in asthmatic

- patients. American Journal of Radiology, 1999; 173: 937-942.
21. Shivananda PG. Pulmonary aspergillosis and serologic studies. ICMR Bull, 1992; 22: 107-8.
 22. Eaton TM, Garret J, Milne D, Frankel A, Well AU. Allergic bronchopulmonary aspergillosis in asthma clinic: A prospective evaluation of CT in diagnostic algorithm. Chest, 2000; 118: 66-72.
 23. Antibiotic Treatment for Cystic Fibrosis. 3rd edition. Report of the UK Cystic Fibrosis Trust Antibiotic Working Group, 2009.
 24. Hatziagorou E, Walsh TJ, Tsanakas JN, Roilides E. Aspergillus and the paediatric lung. Paed Respir Rev., 2009; 10: 178-85.
 25. Agarwal R, Denning DW, Chakrabarti A. Estimation of the burden of chronic and allergic pulmonary aspergillosis in India. PLoS One, 2014 Dec 5; 9(12): e114745.
 26. Prasad R, Garg R, Sanjay AD. Allergic bronchopulmonary aspergillosis: A review of 42 patients from a tertiary care center in India. Lung India: Official Organ of Indian Chest Society, 2009 Apr; 26(2): 38.