

TRICHOFOLLICULOMA OVER EYELID**Meenakshi Patial***

Medical Officer [Specialist], Civil Hospital, Nadaun, Himachal Pradesh, India.

***Corresponding Author: Meenakshi Patial**

Medical Officer [Specialist], Civil Hospital, Nadaun, Himachal Pradesh, India.

Article Received on 12/07/2022

Article Revised on 01/08/2022

Article Accepted on 21/08/2022

ABSTRACT

Trichofolliculoma is a benign follicular neoplasm, most commonly located on the nose, cheeks, ear. It has been reported in all age groups but more common in adults with exact etiology being unknown. It usually presents as skin colored nodule with central umbilication and tuft of hair arising from the centre. Management involves excision of the lesion. The case discussed presented in the OPD with dome shaped skin colored nodule over left upper eyelid with tuft of hair protruding from the centre seen on dermoscopy and was managed by complete surgical excision of the nodule.

KEYWORDS: Trichofolliculoma, Adnexal tumor, Follicular neoplasm.**INTRODUCTION**

Trichofolliculoma is rare benign adnexal tumor arising from the hair follicle tissue. It usually affects the head and neck region in adults.^[1] It typically presents as single whitish or skin colored dome shaped papule or nodule, with size varying from 0.5 cm to 1.8 cm in diameter, may be having central umbilication or tuft of hair protruding from the central pore.^[2] The exact etiology is not known. Histopathological examination is mostly used to confirm the diagnosis. Surgical excision of the adnexal tumor is the treatment of choice.

CASE

The patient was a 36-year-old male presented with a slowly growing painless skin colored nodule of size 0.5 x 1 cm on the left upper eyelid for 3 years [Figure 1]. Dermoscopic examination of the lesion showed well-defined skin colored nodule with tufts of hair protruding from the central whitish plug [Figure 2]. Complete surgical excision was done and histopathology was consistent with trichofolliculoma showing numerous vellus hair follicles. No recurrence was seen after 2 months follow-up.

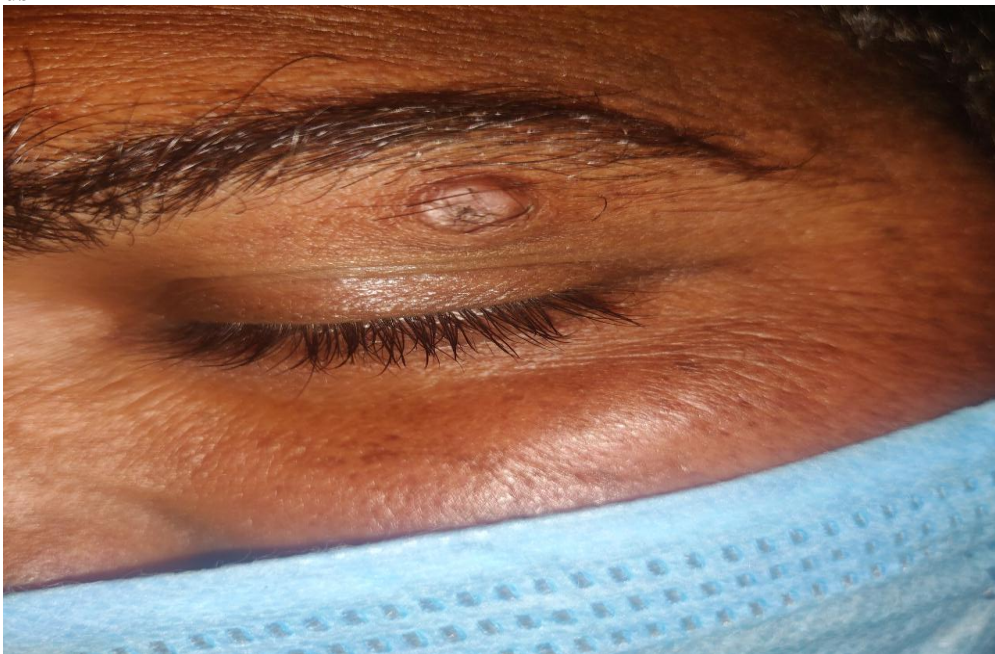
Figure legends**Figure 1: Skin colored dome shaped nodule over left eyelid with hair protruding from the centre of the nodule.**

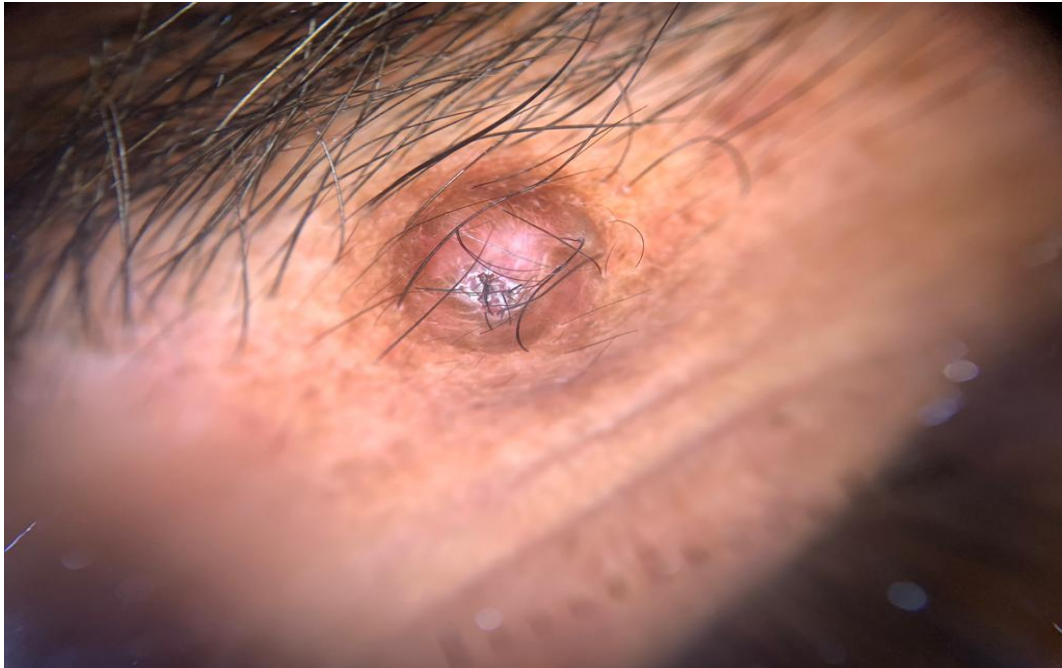

Figure 2: Dermoscopic evaluation showed a nodule with whitish central plug with tuft of hair arising from the centre.

DISCUSSION

Trichofolliculomas are benign follicular neoplasm, mostly found on the face with the most common locations being the nose, cheek, and ear. The exact etiology of trichofolliculoma is not known. It has not been shown to be associated with any systemic conditions. It has been reported in all age groups, but most reports involve adults.^[3] There are reports of trichofolliculoma appearing on the upper and lower eyelids, but it is a rare presentation.^[4] This case presented with skin colored nodular lesion over upper eyelid with complain of discomfort while lid movements. Patients with trichofolliculomas usually presented with a nodule on the eyelid, discomfort with blink, whitish discharge or abnormal hair growth. Management is simple and involves complete surgical excision of the lesion. The tumor is benign without a single report of metastasis and only one report of invasion. The prognosis for trichofolliculoma is good.^[5]

REFERENCES

1. Carreras B Jr., Lopez-Marin I Jr., Mellado VG, et al. Trichofolliculoma of the eyelid. *Br J Ophthalmol*, 1981; 65: 214–5.
2. Weedon D. *Weedon's skin pathology*. 3rd ed. China: Elsevier, 2010; 758.
3. Romero-Pérez D, García-Bustinduy M, Cribier B. Clinicopathologic study of 90 cases of trichofolliculoma. *Journal of the European Academy of Dermatology and Venereology*, 2016; 31(3).
4. Taniguchi S, Hamada T. Trichofolliculoma of the eyelid. *Eye.*, 1996; 10(6): 751-752.
5. Stern JB, Stout DA. Trichofolliculoma Showing Perineural Invasion: Trichofolliculocarcinoma? *Arch Dermatol*, 1979; 115(8): 1003–1004.