

CLINICO-RADIOLOGICAL OUTCOME OF PERCUTANEOUS VERTEBROPLASTY IN DORSO-LUMBAR OSTEOPOROTIC VERTEBRAL COMPRESSION FRACTURES (OVCFS)

Md. Yousuf Ali^{1*}, Shahida Akter², Chowdhury Iqbal Mahmud³, Md. Ali Faisal⁴, Md. Khorsherdul Alam⁵, Md. Muhibbur Rahman⁶, Nazmus Sakeb⁷, Samrat Parajuli⁸ and Md. Ruhul Amin⁹

¹Associate Professor, Spinal Surgery, Dept. of Orthopaedics, Bangabandhu Sheikh Mujib Medical University, Dhaka.

²Medical Officer, Dept. of Conservative Dentistry, Bangabandhu Sheikh Mujib Medical University, Dhaka, Bangladesh.

³Associate Professor, Orthopaedic Surgery, Dept. of Orthopaedics, Bangabandhu Sheikh Mujib Medical University, Dhaka, Bangladesh.

⁴Associate Professor, Orthopaedic Surgery, Dept. of Orthopaedics, Bangabandhu Sheikh Mujib Medical University, Dhaka, Bangladesh.

⁵Assistant Professor, Orthopaedic Surgery, Cumilla Medical College Hospital, Cumilla, Bangladesh.

⁶Junior Consultant, Physical Medicine and Rehabilitation, Government Employee Hospital, Dhaka, Bangladesh.

⁷Associate Professor, Orthopaedic Surgery, Dept. of Orthopaedics, Dhaka Community Medical College Hospital, Dhaka, Bangladesh.

^{8,9}Resident, Orthopaedic Surgery, Dept. of Orthopaedics, Bangabandhu Sheikh Mujib Medical University, Dhaka, Bangladesh.

*Corresponding Author: Prof. Md. Yousuf Ali

Associate Professor, Spinal Surgery, Dept. of Orthopaedics, Bangabandhu Sheikh Mujib Medical University, Dhaka.

Article Received on 21/08/2023

Article Revised on 11/09/2023

Article Accepted on 01/10/2023

ABSTRACT

Introduction: Vertebral compression fractures (VCFs) are the most common complication of osteoporosis where Percutaneous vertebroplasty is thought to immediately improve the pain and disability status via stabilization and reinforcement of the fractured body with polymethylmethacrylate (PMMA) injection. **Purpose:** To evaluate the clinical and radiological outcome of Percutaneous vertebroplasty in osteoporotic VCFs in Dorso-Lumbar (DL) Spine. **Materials and Methods:** It is a prospective study carried out in Bangabandhu Sheikh Mujib Medical University (BSMMU) and different private hospitals in Dhaka, from January 2010 to March 2023. Total number of patients was 121 i.e., 92 female 29 male patients (167 treated vertebrae), age ranged from 65-85 years with mean age 73.40 years. 10 cases at D₁₀ and D₁₁ each, 26 cases at D₁₂, 21 cases at L₁, 15 cases at L₂, 16 cases at D₁₂-L₁, 03 case at D_{9,12}, 05 cases at D_{10,11}, 07 cases at L_{1,2} and 03 case at D_{9,12}-L₁ and 05 cases at D₁₂-L_{1,2}. Follow up ranged from 24 to 36 months and outcome assessed regarding neurological status (Radiculopathy and Myelopathy), pain [Visual Analogue Score (VAS)] and disability [Oswestry Disability Index (ODI) questionnaire]. Radiological assessment of the treated spine was done to identify any vertebral height gain (McKiernan method), kyphosis correction (Cobb's method). **Results:** The mean age was 73.40 ± 03.75 years. 74(60.97%) patients were in 65-74 years age group. 105(63.41%) cases had single vertebral level, 49(29.26%) with 02 levels and 12(07.32%) with 03 levels involvement. D12 (n=53, 31.17%) and L1 (n=52, 31.13%) were most frequent. The age, sex, occupation, and the level of involvement had no significant difference (p>0.05, chi-squared test). VAS for pain had significantly improvement (p<0.05, paired t test) from preoperative 08.50±0.50 to 03.50±0.30 postoperatively and 02.80± 0.50 at 1 year. The preoperative ODI 71.11±09.69 improved significantly (p<0.05, paired t test) to 17.34±04.11 postoperatively and 09.76± 04.83% at 1 year. The kyphotic angle was corrected to 05°±02.50° at the 12 months follow up radiograph. One level (02.30%) had cement leakage which was evident on postoperative X-ray but was asymptomatic even on the last follow up. **Conclusion:** Percutaneous Vertebroplasty is a significantly effective technique for immediate and short-term pain relief, disability status improvement in Vertebral Compression Fractures (VCFs) with satisfactory radiological outcome in DL spine.

KEYWORDS: Percutaneous Vertebroplasty, Vertebral Compression Fractures.

INTRODUCTION

Vertebral Compression fracture (VCF) is the most common complication of osteoporosis^[1] and is associated with significant declines in health and functional activity.^[2] Its prevalence steadily increases with age, reaching 40% in 80-year-old women,^[3] having a 15% higher mortality rate.^[4] All the vertebrae could be affected but the Dorso lumbar region is the commonest and it typically occurs at the anterior third of the body resulting in altered biomechanics of the spine, making adjacent levels more vulnerable to further fracture and if left untreated, progressive spinal deformity may also be ensued.^[5] Moreover, one third of these fractures results in persistent pain,^[6] progressive loss of functional capability and ultimate loss of mobility.^[7] Primary modalities for the treatment of VCFs include: conventional medical management, reconstructive surgical intervention, and Percutaneous Vertebroplasty (PV).^[8]

after being introduced for the treatment of Vertebral Angiomas in 1984 by Galibert and Deramond,^[9] PV is being a useful intervention for osteolytic neoplasms^[10] and osteoporotic fractures.^[11] Reported pain relief is achieved in 70%–100%^[12] cases of osteoporotic fractures which are thought to be achieved via stabilization and reinforcement of the fractured body^[1] by Injection of polymethylmethacrylate (PMMA).^[13] This procedure leads to partial or complete pain reduction within 72 hours of injection^[14] and is particularly advantageous because of their brief surgical time, limited sedation, minimal recovery period, and short or no hospital stay^[15] as well as avoiding and minimizing the need for antero-posterior stabilization and their associated morbidities in elderly group of population.^[16]

Since being introduced into surgical practice in the late 1990s, vertebroplasty has become one of the preferred methods for treating Osteoporotic Vertebral Compression fractures (OVCF) for many spine surgeons.^[17] As the dorso-Lumbar (DL) Spine had been most affected in different series of literatures due to its unique biomechanical characteristics we have evaluated the clinical and radiological outcome of the procedure in OVCFs of the region.

METHODS

It is a prospective study carried out in Bangabandhu Sheikh Mujib Medical University (BSMMU) and different private hospitals in Dhaka, from January 2010 to March 2023. Total number of patients was 121 i.e., 92 female 29 male patients (167 treated vertebrae), age ranged from 65-85 years with mean age 73.40 years. All the patients were evaluated preoperatively by coagulation screening, X-ray DL spine A/P, standing and supine lateral views, Magnetic Resonance Imaging (MRI) of the DL spine and Computerized Tomography (CT) scan to delineate the vertebral anatomy and intra spinal neurological condition. The patients with painful OVCFs involving the DL spine refractory to medical

treatment or associated with osteonecrosis, unstable and multiple OVCFs were treated. Patients with i) back pain attributed to myelopathy or radiculopathy resulting from stenosis of the vertebral canal or narrowing of the intervertebral foramen, ii) Associated OVCF severe vertebral body collapse to more than one-third of its original height iii) CT documented interrupted posterior cortical outline, iv) OVCF involving spinal regions other than DL Spine and v) patients with coagulopathies were excluded.

Follow up ranged from 24 to 36 months and outcome assessed regarding neurological status (Radiculopathy and Myelopathy), pain [Visual Analogue Score (VAS)^[18]] and disability [Oswestry Disability Index (ODI) questionnaire^[19]] at day 10, 1 month, 3 months, 6 months and every 6 monthly thereafter. Radiological assessment of the treated spine was done to identify any vertebral height gain (by McKiernan^[20] method), kyphosis correction (by Cobb's^[21] method). Statistical analysis was done using SPSS software and chi-squared test and t-test done where applicable. Statistical significance were considered when the results were <0.05.

Operative Procedure: In the procedure room, after giving a prophylactic dose of injectable antibiotic the patients were carefully positioned prone to avoid new fractures over a Wilson frame with extra padding to avoid pressure points. Sedation was accomplished using fentanyl and propofol infusion at the discretion of the anesthesiologist to maintain adequate sedation. Following site preparation and sterile draping, the C-arm was rotated until the pedicles of the VBFs were in a proper view. Skin and subcutaneous tissues were anesthetized and a 0.5-cm stab skin incision was made. Under the C-arm guidance, an awl-tipped probe was inserted and gradually advanced through the pedicle (biportal) using continuous anterior-posterior (AP) and lateral C-arm views to ensure correct needle advancement. Once the probe was at the junction of the posterior third and the middle third of the vertebral body a 0.5 mm (OD) stainless steel threaded-tipped cannula was railroaded over the probe and rotated clockwise to advance the catheter into the cancellous bone, just past the cortical wall. The probe was then removed, leaving the cannula in place. The same procedure was performed on the opposite pedicle.

The cement mixture consisted of 40 ml powder methyl-methacrylate polymer mixed with 10 mL liquid methyl-methacrylate monomer and 12 g barium sulfate. The cement was allowed to reach the thin paste consistency and taken into a syringe. The cement was slowly injected into the cannula until the cavity was filled which was confirmed by C-arm. The same procedure was repeated in the opposite side (biportal). Injection was immediately discontinued if fluoroscopic evidence of cement extrusion was observed. In patients with extravasation of cement beyond the boundaries of the vertebral body, CT

imaging was used to detect leakage into the epidural space or neural foramen. One to three levels were treated during a single procedure, with a total amount injected per level of 2.5 to 5 mL of cement. The cannulas were then removed and the incision sites were closed. Total fluoroscopy time was 3 to 4 minutes per level treated.

The patients were discharged after 6 hours of recovery, and close contact was maintained with them over the next 72 hours. Patients returned to the office 10 days later for suture removal and postoperative evaluation by comprehensive neurologic examination, repeat VAS scoring of pain and disability assessment. Postoperatively all the cases were routinely treated with Bisphosphonates.

RESULTS

Total 121 cases, age ranging from 65 to 85 years, mean age 73.40 ± 03.75 years were included. Maximum 74(60.97%) patients were in 65-74 years age group. Out of these patients 92(76%) were female, male: female ratio 1:4 with a female predominance. All female patients were Housewives, and 18(14.63%) male patients were sedentary workers. Total 167 vertebra were involved in which 105(63.41%) cases had single vertebral level, 49(29.26%) with 02 levels and 12(07.32%) with 03 levels involvement. Maximum cases involved at D12 (n=53, 31.17%) and L1 (n=52, 31.13%),

L₂ (n=30, 17.96%) and D₁₀, D₁₁ each (n=15, 08.98%), and D₉ (n=06, 03.59%). The age, sex, occupation, and the level of involvement had no significant difference ($p>0.05$, chi-squared test) [Table-I]. The duration of the hospital stay was 6 hours to 1 day. No serious complications (e.g. infection, cement leakage related pulmonary embolism, radiculopathy or myelopathy) related to the procedure occurred except one vertebral level (02.30%) had mild cement leakage which was evident on postoperative X-ray but was asymptomatic even on the last follow up.

All the patients were followed up in a period for minimum 12 months. Table-II describes, the pain intensity of all the patients was assessed by Visual Analogue Score (VAS) and had significantly improvement ($p<0.05$, paired t test) at the 10th postoperative day (from mean 08.50 ± 0.50 to mean 03.50 ± 0.30) with similar improved pain status at even 1 year follow up (mean 02.80 ± 0.50). The mean preoperative disability score by Oswestry Disability Index (ODI) was 71.11 ± 09.69 (range 69.75% to 78.57%) which was improved significantly ($p<0.05$, paired t test) to 17.34 ± 04.11 (range 11.75% to 23.56%) at 10th postoperative day and even upto $09.76 \pm 04.83\%$ at 1 year follow up. All the patients returned to their normal daily living. The kyphotic angle was corrected to $05^\circ \pm 02.50^\circ$ at the 12 months follow up radiograph [Table-II].

Table-I: Demographic variables of the study population. (n=121)

Age		Sex		Level of involvement	
Groups	No (%)	Groups	No (%)	Groups	No (%)
65-75 years	74(60.97%)	Male	29 (24%)	01 vertebrae	105 63.41%
75-85 years	47(39.02%)	Female	92 (76%)	02 vertebra	49 29.26%
				03 vertebra	13 7.32%

Table-II: Outcome variables of the study population. (n=121)

Variables		Assessment	Follow ups				
			Pre-op	10 days	3 Months	6 Months	12 Months
Clinical And Radiological Outcome	Pain	Visual Analogue Score (VAS)	08.50 ± 0.50	03.50 ± 0.30	03.00 ± 0.80	03.00 ± 0.30	02.80 ± 0.50
	Disability	Oswestry Disability Index (ODI) Score	71.11 ± 09.69	17.34 ± 04.11	13.67 ± 03.37	11.76 ± 04.25	09.76 ± 04.83
	Kyphosis correction	Cobb's ²² method	$15^\circ \pm 05.50^\circ$	$10^\circ \pm 05.50^\circ$	$10^\circ \pm 05.50^\circ$	$07.50^\circ \pm 05.50^\circ$	$05^\circ \pm 02.50^\circ$

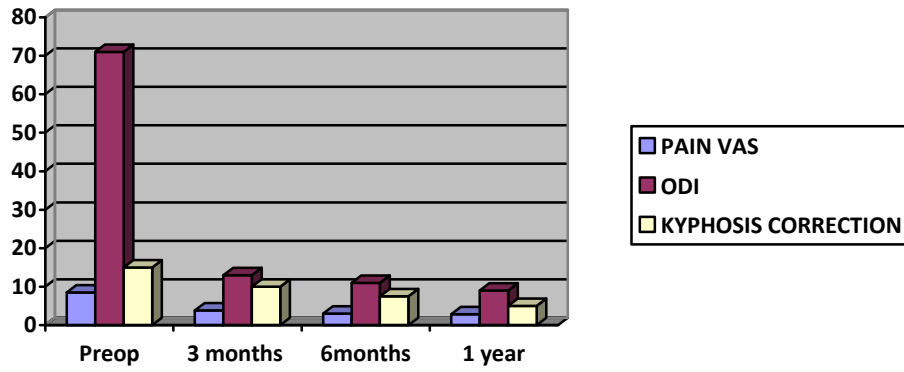
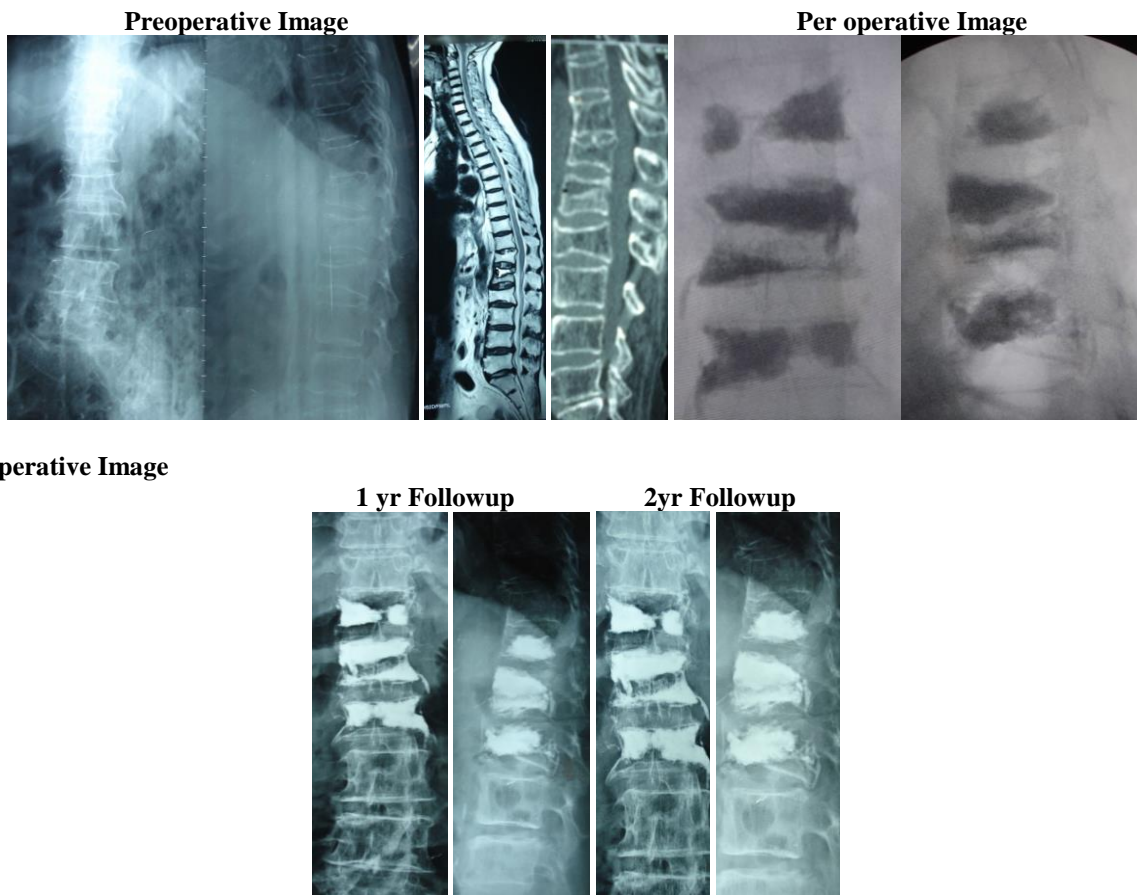


Chart: Outcome variables of the study population. (n=121)

Pictures



DISCUSSION

Conventional PV for OVCFs was originally developed in response to limited results of conservative and surgical modalities to stabilize and strengthen collapsed vertebral bodies.^[22-24] Conservative therapy included bed rest, external bracing, analgesics, or calcitonin therapy over several weeks for pain control,^[25] along with other treatments (e.g. hormone replacement or biphosphonates for the long-term), but often do not provide adequate immediate or short term pain relief.^[26] Moreover a long period of bed rest can lead to demineralization of bone and which may predispose to further fracture.^[27] For these reasons Stanford University underwent a

prospective randomized crossover trial comparing PV with conservative therapy for acute OVCFs and showed significant improvement with PV,^[28] that include reduced or eliminated fracture pain, less long-term pain or disability, prevention of further collapse, and an early return to mobility.^[29,30]

The demographic variables of our study were similar to Zoarski^[31] who performed a prospective analysis of 30 patients at 54 levels, with 18 months follow-up. Their mean age was 79 years with female predominance. Significant improvement of pain was noted by McGraw^[32] who prospectively evaluated 100 patients at

156 levels resulting significant pain relief by 24 hours that sustained even upto 21 months. Their VAS score dropped from 8.9 to 2.0. Cortet^[25] also had a significant improvement of pain (16 patients, 20 levels) but sustained only for 6 months. Significant disability level improvement was noted by Zoarski^[31] at 2 weeks post-procedure that continued up to 18-month whereas 93% of patients of McGraw^[32] noted an increased activity level almost similar to us. Mckiernan^[33] showed significant quality of life improvement.

Despite the benefits of conventional PV, cement extrusion has been most frequently associated with it^[34] (9% to 80% cases), probably due to the low viscosity and the pressure required to inject cement into the cancellous vertebral body matrix.^[35] It appears that even with a perfect technique, cement leakage up to a certain percentage is an inevitable and unpredictable complication.^[36] Although there had been very few reports of postoperative cement related neural complications (root compression,^[37] Cord compression^[38]) and fatal pulmonary embolisms^[39] one case of cardiovascular collapse requiring pulmonary embolectomy, one lethal pulmonary embolus, and one case of paradoxical cerebral arterial PMMA emboli have been reported.^[40] There are also several reports of osteomyelitis requiring corpectomy.^[41] Leakage into the paravertebral muscles (can causes severe localized pain), into the venous circulation (can produce generalized toxic reactions)^[39] but we did not encounter any of such complicated incidents. The rate of cement leakage of our study (9.2% in vertebroplasty procedures) compares favorably with published rates.^[35]

Perez-Higueras^[30] prospectively assessed radiographic outcomes in 12 patients over a 5-year period. Three patients suffered 04 new fractures over the 5-year follow-up period, two of which were adjacent to treated levels. Cortet^[25] was first to note increase in adjacent level fractures on long-term follow-up after PV but we had no such consequences in our 1 year follow up period. Kim^[42] noted 72 new fractures (7.9%) over a 3-year follow-up duration but the 1-year fracture-free rate was 93% according to Kaplan–Meier analysis. Re-fractures of already stabilized vertebrae^[43] had been reported but we did not encounter such condition. There are reports of persisting pain^[44] but it was also absent in our series.

The small number of our study population had no incidence of adjacent level fracture within only one year follow up. Even this small number of cases enrolled was not sufficient to properly assess the statistical outcome. We recommend the assessment in a larger study population with a longer follow up.

CONCLUSION

Percutaneous Vertebroplasty (PV) is significantly effective technique for immediate and short-term pain relief, disability status improvement in Osteoporotic

Vertebral Compression Fractures (OVCFs) with satisfactory radiological outcome.

REFERENCES

1. Deen HG, Fenton DS, Lamer TJ. Minimally invasive procedures for disorders of the lumbar spine. *Mayo Clin Proc.*, 2003; 78: 1249-56.
2. Phillips S, Fox N, Jacobs J, Wright WE. The direct medical costs of osteoporosis for American women aged 45 and older. *Bone*, 1988; 9: 271-79.
3. Kado DH, Browner WS, Palermo L, Nevitt MC, Genant HK, Cummings SR. Vertebral fractures and mortality in older women. A prospective study. *Arch Intern Med.*, 1999; 159: 1215-20.
4. Leech JA, Dulberg C, Kellie S, Pattee L, Gay J. Relationship of lung function to severity of osteoporosis in women. *Am Rev Respir Dis.*, 1990; 141: 68-71.
5. Vallejo R, Benyamin R, Floyd B, Casto JM, Joseph NJ, Mekhail N. Percutaneous cement injection into a created cavity for the treatment of vertebral body fracture: preliminary results of a new vertebroplasty technique. *Clin J Pain*, 2006; 22: 182-89.
6. Lieberman IH, Dudeney S, Reinhardt MK, Bell G. Initial outcome and efficacy of “kyphoplasty” in the treatment of painful osteoporotic vertebral compression fractures. *Spine*, 2001; 26: 1631-38.
7. He SC, Teng GJ, Deung G, Fang W, Guo JH, Zhu GY, et al. Repeat vertebroplasty for unrelieved pain at previously treated vertebral levels with osteoporotic vertebral compression fractures. *Spine*, 2008; 33: 640-47.
8. Shen M, Kim Y. Osteoporotic vertebral compression fractures: a review of current surgical management techniques. *Am J Orthop (Belle Mead NJ.)* 2007; 36(5): 241-48.
9. Galibert P, Deramond H, Rosat P, LeGars D. Note preliminaire sur le traitement des angiomes vertebraux par vertebroplastie acrylique percutanee. *Neurochirurgie*, 1987; 33: 166-68.
10. Alvarez L, Perez-Higueras A, Quinones D, Calvo E, Rossi RE. Vertebroplasty in the treatment of vertebral tumors: postprocedural outcome and quality of life. *Eur Spine J.*, 2003; 12: 356–60.
11. Diamond TH, Champion B, Clark WA. Management of acute osteoporotic vertebral fractures: a nonrandomized trial comparing percutaneous vertebroplasty with conservative therapy. *Am J Med*, 2003; 114: 257-65.
12. Garfin SR, Yuan HA, Reiley MA. New technologies in spine: kyphoplasty and vertebroplasty for the treatment of painful osteoporotic compression fractures. *Spine*, 2001; 26: 1511-15.
13. Amar AP, Larsen DW, Esnaashari N, Albuquerque FC, Lavine SD, Teitelbaum GP. Percutaneous transpedicular polymethyl-methacrylate vertebroplasty for the treatment of spinal compression fractures. *Neurosurgery*, 2001; 49: 1105-14.

14. Chin DK, Kim YS, Cho YE, Shin JJ. Efficacy of postural reduction in osteoporotic vertebral compression fractures followed by percutaneous vertebroplasty. *Neurosurgery*, 2006; 58: 695-700.
15. Bostrom MP, Lane JM. Future directions: augmentation of osteoporotic vertebral bodies. *Spine*, 1997; 22: 38S-42S.
16. Sappalainen AM, Rajaniemi R. Local neurotoxicity of methyl methacrylate among dental technicians. *Am J Ind Med.*, 1984; 5: 471-7.
17. Fourny DR, Schomer DF, Nader R, Chlan-Fourny J, Suki D, Ahrar K, et al. Percutaneous vertebroplasty and kyphoplasty for painful vertebral body fractures in cancer patients. *J Neurosurg Spine*, 2003; 98: 21–30.
18. Guyatt GH, Townsend M, Berman LB, Keller JL. A comparison of Likert and visual analogue scales for measuring change in function. *J Chronic Dis.*, 1987; 40: 1129-33.
19. Walsh TL, Hanscom B, Lurie JD, Weinstein JN. Is a condition-specific instrument for patients with low back pain/leg symptoms really necessary?: The responsiveness of the Oswestry Disability Index, MODEMS, and the SF-36. *Spine*, 2003; 28(6): 607-15.
20. McKiernan F, Jensen R, Faciszewski T. The dynamic mobility of vertebral compression fractures. *J Bone Miner Res.*, 2003; 18: 24-9.
21. Teng MM, Wei CJ, Wei LC, Luo CB, Lirng JF, Chang FC, et al. Kyphosis correction and height restoration effects of percutaneous vertebroplasty. *Am J Neuroradiol*, 2003; 24: 1893-1900.
22. Mathis JM, Petri M, Naff N. Percutaneous vertebroplasty treatment of steroid-induced osteoporotic compression fractures. *Arthritis Rheumatism*, 1998; 41: 171–75.
23. Watts NB, Harris ST, Genant HK. Treatment of painful osteoporotic vertebral compression fractures with percutaneous vertebroplasty or kyphoplasty. *Osteoporos Int.*, 2001; 12: 429–37.
24. Mathis JM, Barr JD, Belkoff SM, Barr MS, Jensen ME, Deramond H. Percutaneous vertebroplasty: a developing standard of care for vertebral compression fractures. *Am J Neuroradiol*, 2001; 22: 373–81.
25. Cortet B, Cotton A, Boutry N, Flipo RM, Duquesnoy B, Chastanet P, et al. Percutaneous vertebroplasty in the treatment of osteoporotic vertebral compression fractures: an open prospective study. *J Rheumatol*, 1999; 26: 2222-28.
26. Hsu YH, Hueng DY, Ma HI, Liu MY, Chiang YH. Treatment of Osteoporotic Vertebral Fracture by Percutaneous Vertebroplasty or Kyphoplasty. *J Med Sci.*, 2006; 26(1): 5-12.
27. Kim HW, Kwon A, Lee MC, Song JW, Kim SK, Kim IH. The Retrial of Percutaneous Vertebroplasty for the Treatment of Vertebral Compression Fracture. *J Korean Neurosurg Soc.*, 2010; 47: 278-81.
28. Do HM, Marcellus ML, Weir RU, Marks MP. Percutaneous vertebroplasty versus medical therapy for treatment of acute vertebral body compression fractures: a prospective randomized study. Proceedings of the ASNR 2002, and Proceedings of the AUR, 2002.
29. Do HM. Percutaneous vertebroplasty: rationale, clinical outcomes, and future directions. *Neuroimag Clin North Am.*, 2003; 13: 343–63.
30. Perez-Higueras A, Alvarez L, Rossi RE, Quinones D, Al-Assir I. Percutaneous vertebroplasty: long-term clinical and radiological outcome. *Neuroradiology*, 2002; 44: 950-54.
31. Zoarski GH, Snow P, Olan WJ, Stallmeyer MJ, Dick BW, Hebel JR, et al. Percutaneous vertebroplasty for osteoporotic compression fractures: quantitative prospective evaluation of long-term outcomes. *J Vasc Interv Radiol*, 2002; 13: 139-48.
32. McGraw JK, Lippert JA, Minkus KD, Rami PM, Davis TM, Budzik RF. Prospective evaluation of pain relief in 100 patients undergoing percutaneous vertebroplasty: results and follow-up. *J Vasc Interv Radiol*, 2002; 13: 883–86.
33. Mckiernan F, Faciszewski T, Jensen R. Quality of life following vertebroplasty. *J Bone Joint Surg Am*, 2004; 86: 2600-06.
34. Anselmetti GC, Zoarski G, Manca A, Masala S, Eminefendic H, Russo F, et al. Percutaneous vertebroplasty and bone cement leakage: clinical experience with a new high-viscosity bone cement and delivery system for vertebral augmentation in benign and malignant compression fractures. *Cardiovasc Intervent Radiol*, 2008; 31(5): 937-47.
35. Phillips FM. Minimally invasive treatments of osteoporotic vertebral compression fractures. *Spine*, 2003; 28: 545–53.
36. Gaughen JR, Jensen ME, Schweickert PA, Kaufmann TJ, Marx WF, Kallmes DF. Relevance of antecedent venography in percutaneous vertebroplasty for the treatment of osteoporotic compression fractures. *Am J Neuroradiol*, 2002; 23: 594–600.
37. Lee BJ, Lee SR, Yoo TY. Paraplegia as a complication of percutaneous vertebroplasty with polymethyl methacrylate: a case report. *Spine*, 2002; 27: E419–E422.
38. Ratliff J, Nguyen T, Heiss J. Root and spinal cord compression from methymethacrylate vertebroplasty. *Spine*, 2001; 26: E300–E302.
39. Francxois K, Taeymans Y, Poffyn B, Van Notten G. Successful management of a large pulmonary cement embolus after percutaneous vertebroplasty: a case report. *Spine*, 2003; 28: E424–E425.
40. Padovani B, Kasriel O, Brunner P, Peretti-Viton P. Pulmonary embolism caused by acrylic cement: a rare complication of percutaneous vertebroplasty. *Am J Neuroradiol*, 1999; 20: 375–77.
41. Syed MI, Avutu B, Shaikh A, Sparks H, Mohammed MI, Morar K. Vertebral osteomyelitis following vertebroplasty: is acne a potential contraindication

and are prophylactic antibiotics mandatory prior to vertebroplasty? *Pain Physician*, 2009 Jul-Aug; 12(4): E285-90.

42. Kim SH, Kang HS, Choi JA, Ahn JM. Risk factors of new compression fractures in adjacent vertebrae after percutaneous vertebroplasty. *Acta Radiol*, 2004; 45: 440-45.
43. Lin WC, Lee YC, Lee CH, Kuo YL, Cheng YF, Lui CC, et al. Refractures in cemented vertebrae after percutaneous vertebroplasty: a retrospective analysis. *Eur Spine J.*, 2008; 17: 592-99.
44. Georgy BA. Interventional techniques in managing persistent pain after vertebral augmentation procedures: a retrospective evaluation. *Pain Phys.*, 2007; 10: 673-76.