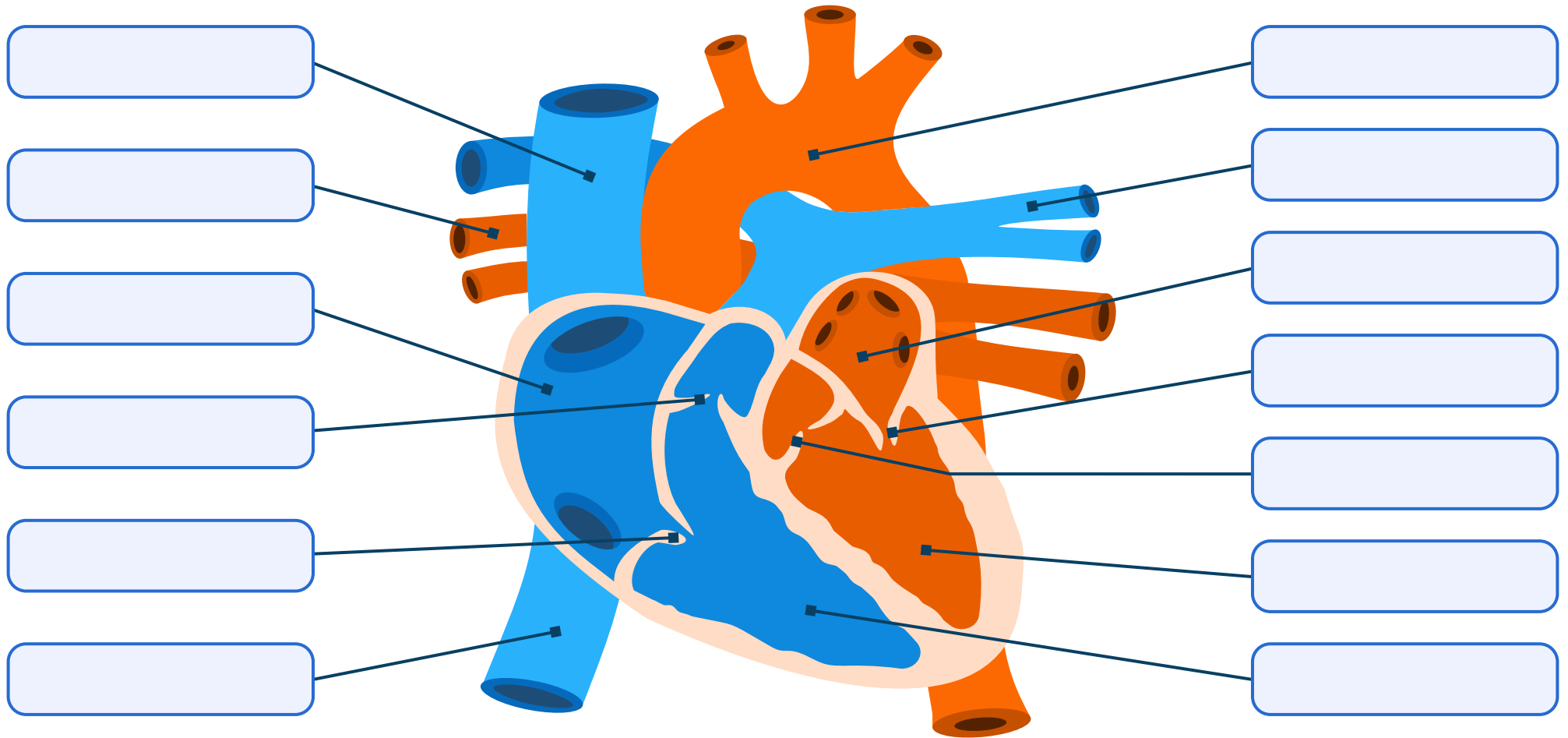


# The Human Heart



Aortic valve

Left atrium

Aorta

Tricuspid valve

Superior vena cava

Pulmonary vein

Mitral valve

Right ventricle

Pulmonary valve

Right atrium

Pulmonary artery

Inferior vena cava

Left ventricle