

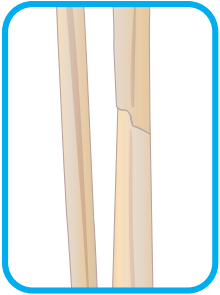
# Bone Doctor

X-ray imaging creates pictures of the inner body using electromagnetic radiation. Bones appear as translucent white shapes, and fractures manifest as dark marks and gaps. Read about the different types of bone fractures below. Look at the X-rays and circle the fractures in need of healing.

## Types of Fractures

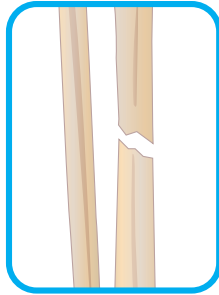
### Stable Fracture:

identified by the broken bone pieces being barely out of place



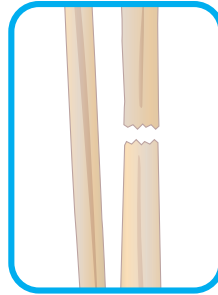
### Oblique Fracture:

identified by its angled fracture line



### Transverse Fracture:

identified by its horizontal fracture line



### Comminuted Fracture:

identified by the shattering of the bone into three or more pieces

