Review paper

Cite as: Albano D, Gitto S, Serpi F, Aliprandi A, Sconfienza LM, Messina C: Ultrasound-guided musculoskeletal interventional procedures around the hip: a practical guide. J Ultrason 2023; 23: e15–e22. doi: 10.15557/JoU.2023.0003

Submitted: 27.08.2022
Accepted: 17.11.2022
Published: 05.01.2023

Ultrasound-guided musculoskeletal interventional procedures around the hip: a practical guide

Domenico Albano[1], Salvatore Gitto[2], Francesca Serpi[2], Alberto Aliprandi[3], Luca Maria Sconfienza[1,2], Carmelo Messina[1,2]

[1] *Radiologia Diagnostica ed Interventistica, IRCCS Istituto Ortopedico Galeazzi, Milano, Italy*
[2] *Dipartimento di Scienze Biomediche per la Salute, Università degli Studi di Milano, Milano, Italy*
[3] *Radiology, Istituti Clinici Zucchi, Monza, Italy*

Corresponding author: Domenico Albano; e-mail: albanodomenico@me.com

DOI: 10.15557/JoU.2023.0003

Keywords
ultrasound; hip; interventional radiology; injections

Abstract

Several studies have shown that ultrasound guidance may contribute to improved safety, effectiveness and accuracy of musculoskeletal interventional procedures performed around the hip if compared to those performed with a landmark-guided technique. Different approaches and injectates can be used for treating hip musculoskeletal disorders. These procedures may involve injections in the hip joint, periarticular bursae, tendons, and peripheral nerves. Intra-articular hip injections are mostly used as a conservative approach for treating patients affected by hip osteoarthritis. Ultrasound-guided injection of the iliopsoas bursa is performed in patients with bursitis and/or tendinopathy, to treat those with painful prosthesis due to iliopsoas impingement, or when the lidocaine test is indicated to identify the iliopsoas as a source of pain. Ultrasound-guided interventions are routinely used in patients with greater trochanteric pain syndrome having as target the gluteus medius/minimus tendons and/or the trochanteric bursae. Ultrasound-guided fenestration and platelet-rich plasma injection are applied in patients with hamstring tendinopathy with good clinical outcomes. Last but not least, ultrasound-guided perineural injections can be used for peripheral neuropathies or blocks of the sciatic, lateral femoral cutaneous, and pudendal nerves. In this paper, we discuss the evidence and technical tips for musculoskeletal interventional procedures performed around the hip, highlighting the added value of ultrasound as an imaging guidance modality.

Introduction

Hip osteoarthritis is a major cause of hip pain, and total hip arthroplasty (THA) is one of the most frequent surgical procedures in orthopedic surgery, with the number of implants growing over time due to population aging[1]. However, several musculoskeletal conditions may contribute to hip pain, involving the joint and surrounding structures, including tendons, muscles, bursae, and peripheral nerves. In this setting, ultrasound-guided interventional procedures have gained much space for treating these conditions conservatively[2–4]. Most structures around the hip are superficial and can be approached using ultrasound for both diagnostic and therapeutic purposes[5,6]. Regardless of the technical approach (i.e. in-plane or out-of-plane) or delivered drug (i.e. steroid, local anesthetic (LA), hyaluronic acid (HA), platelet-rich-plasma (PRP)), ultrasound ensures safety in reaching the target with no radiation exposure. Furthermore, as recently highlighted by the latest evidence-based consensus recommendations by the European Society of Musculoskeletal Radiology (ESSR), ultrasound guidance allows for improving accuracy and effectiveness of most musculoskeletal interventional procedures in the upper and lower limbs[7–13].

In this paper, we discuss the evidence and technical tips of musculoskeletal interventional procedures performed around the hip, highlighting the added value of ultrasound as an imaging guidance technique.

Hip joint

Hip injections are generally used for treating patients with osteoarthritis[6,14,15]. Ultrasound-guided injections are significantly more accurate than those performed without guidance (67–88% versus 97%)[16]. The injection of corticosteroids (generally 1 ml) determines short-to-mid-term response (pain and function), but the efficacy of HA seems to be longer, similar to that of PRP, though controversial data have been reported about the actual superiority of HA to corticosteroids or placebo[10]. Further, ultrasound guidance can

© 2023 Authors. This is an open-access article distributed under the terms of the Creative Commons Attribution-NonCommercial-NoDerivatives License (CC BY-NC-ND). Reproduction is permitted for personal, educational, non-commercial use, provided that the original article is in whole, unmodified, and properly cited.

be used to inject contrast media for MR arthrography[17] or to perform diagnostic LA injection (10 ml of lidocaine 2%) to assess the source of pain[18], using a 20–22 G × 9 cm spinal needle. Ultrasound-guided joint aspiration is a crucial pre-operative step before revision of THA. LA hip injections in patients with femoroacetabular impingement may be used in the preoperative decision-making, as a negative response from an intra-articular hip injection may predict a negative surgical outcome[19]. Where there is no presence of effusion, reported in 50–60% of cases[20], ultrasound can be used as a guidance technique for periprosthetic synovial biopsy[21].

Technique

The patient is in supine position. The needle is generally inserted with in-plane caudal-to-cranial approach, with the convex probe being placed parallel to the femoral neck and the head-neck junction being the target of injection (or aspiration). Color Doppler can be used to follow the intra-articular diffusion of the injectate[4], but capsule distension is generally easily recognizable (Fig. 1).

Iliopsoas bursa

Ultrasound-guided injection has been shown to be a feasible and accurate modality for the treatment of iliopsoas bursitis and tendinopathy[10]. The intervention might be used both to aspirate and inject the bursa in patients with bursitis and to treat conservatively those with painful THA due to iliopsoas impingement. Ultrasound-guided injection of corticosteroids and LA in the iliopsoas bursa provides pain relief in the great majority of THA patients (more than 90%) with iliopsoas impingement[22]. Moreover, the LA test in iliopsoas bursa is a helpful diagnostic step to recognize the iliopsoas as source of pain in failed THA.

Technique

The intervention is performed with the patient in supine position and the hip in neutral rotation. A 20–22 G × 9 cm spinal needle is inserted using in-plane lateral-to-medial approach, with the probe in transverse position in order to scan the iliopsoas tendon in the short axis at the level of the acetabulum or the acetabular cup. Notably, the bursa is not visible using sonography, unless distended with fluid. When injecting the collapsed bursa, we target deep to the tendon (Fig. 2). A convex or a linear probe can be used on the basis of patient habitus. A volume of LA – 10 ml of lidocaine 2% – can be used for the LA test, while a mixture of 1 ml of LA and 1 ml of corticosteroid is injected for therapeutic purposes.

Trochanteric region

A common cause of lateral hip pain is greater trochanteric pain syndrome (GTPS), due to trochanteric bursitis associated with gluteus medius and/or minimus tendinopathy. The condition is approached conservatively, and interventional procedures can be part of the treatment. Ultrasound-guided injections of corticosteroids and LA determine pain improvement in the mid-term[10]. Despite the fact that similar results can be obtained with blinded injections, ultrasound-guided procedures seem to be superior when the injectate is administered within the greater trochanteric bursa[23]. Alternatively, ultrasound-guided gluteus tendons needling and/or PRP injections can be used with good results[10]. There is no clear superiority of one

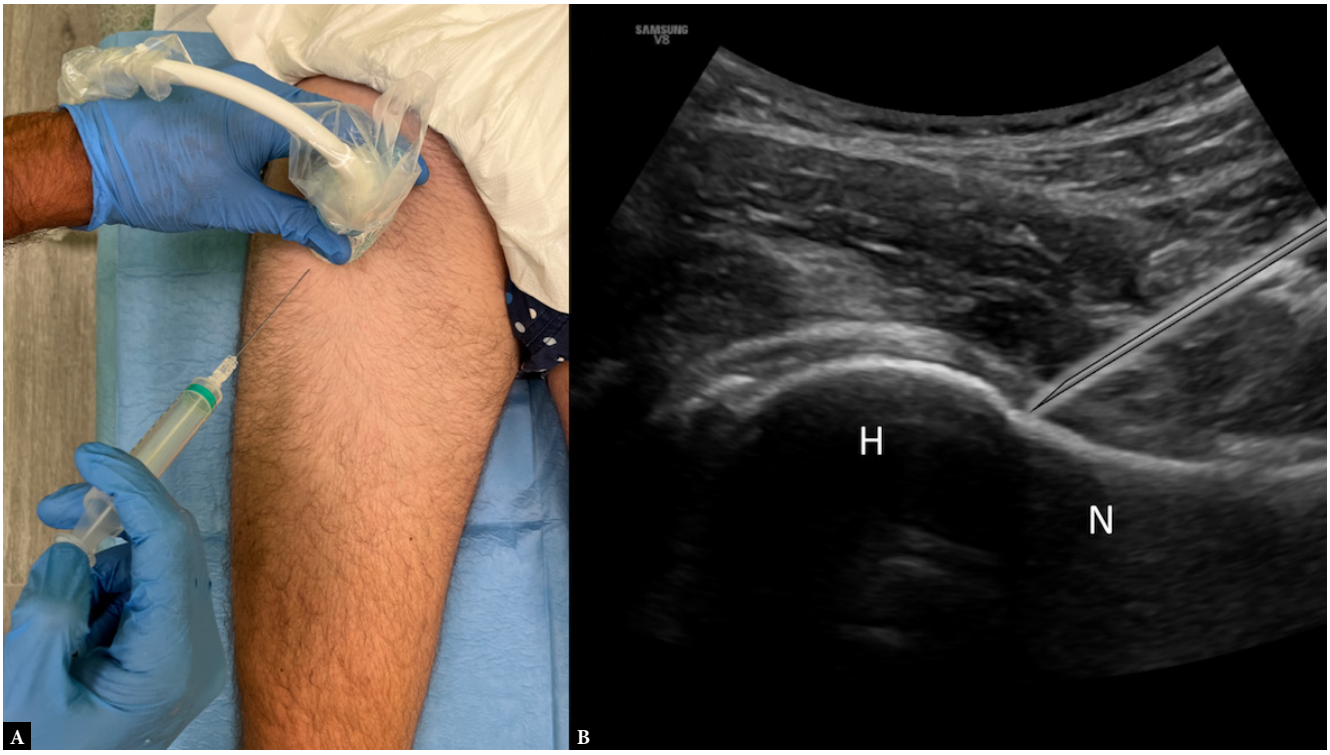

Fig. 1. *Ultrasound-guided hip joint injection.* **A.** *The patient is supine, and a convex transducer is positioned parallel to the femoral neck.* **B.** *The corresponding ultrasound image shows the needle inserted into the hip joint at the head-neck junction with in-plane technique. H – femoral head; N – femoral neck*

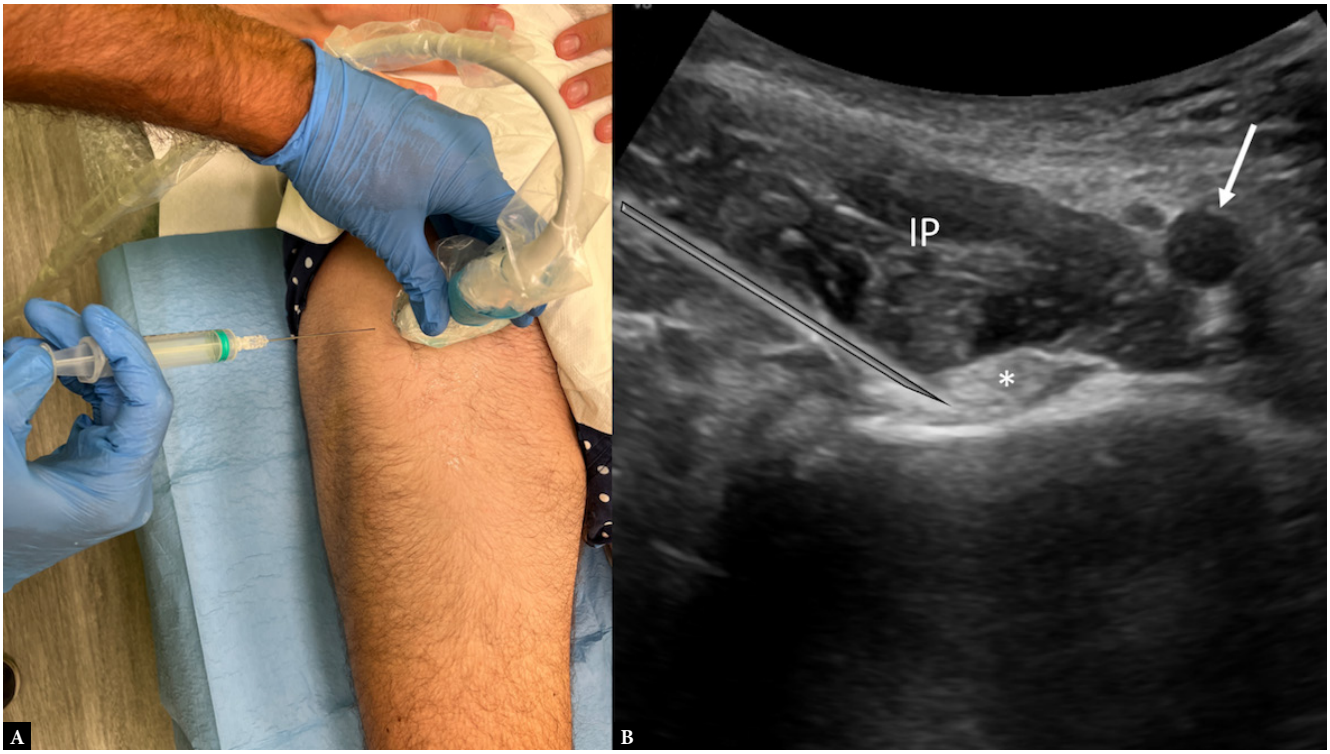

Fig. 2. *Ultrasound-guided iliopsoas injection.* **A.** *The patient is supine, and a linear transducer is positioned in transverse position at the level of the acetabulum to scan the iliopsoas tendon in the short axis.* **B.** *The corresponding ultrasound image shows how to insert the needle with in-plane lateral-to-medial approach to reach the deep aspect of the tendon (asterisk). With this approach, the femoral neurovascular bundle (arrow), in the medial aspect of the image, cannot be injured. IP – iliopsoas muscle*

procedure over the other one, but ultrasound-guided PRP injections may show longer pain improvement if compared with corticosteroids injections[24].

Technique

The trochanteric procedures are performed with the patient in lateral position on the contralateral side. A linear or convex probe is placed along the gluteus tendons or in the short axis along the middle trochanteric facet. A 20–22 G × 9 cm spinal needle can be inserted with in-plane or out-of-plane approach, with the former being generally preferred, and the tip advanced with lateral-to-medial or caudal-to-cranial direction to reach the tendons or the greater trochanteric bursa between the gluteus tendons and facets and the gluteus maximus muscle (Fig. 3).

Hamstrings

Ultrasound-guided fenestration and PRP injection can be used for treating patients with hamstring tendinopathy. Previous studies have shown pain relief and functional improvement in the short-to-mid-term, while others have reported no relevant clinical effectiveness[10,25]. At any rate, the procedure can be considered when other non-invasive treatments have failed, given that its safety is well-established. Concerning ultrasound-guided ischiogluteal bursa injection, this procedure has been reported to be feasible in cadaveric specimens[10]. However, no clinical data have been reported in vivo on the safety and efficacy of this intervention.

Technique

The patient is in prone position. The ischiatic insertion of hamstring tendons is generally reached with in-plane approach, advancing the needle in lateral-to-medial direction, placing the probe in the short axis of the tendons or in caudal-to-cranial direction shifting of 90 degrees to be parallel to the long axis of the tendons. After tendon fenestration, PRP can be injected within the tendon, generally using a spinal needle of at least 21–22 G (Fig. 4). The volume of PRP varies, also depending on the type of solution/gel.

Nerves

Sciatic nerve

Piriformis syndrome is determined by sciatic nerve compression due to hypertrophy, inflammation, or anatomical deformities of the piriformis muscle. Conservative treatment is recommended, reducing nerve compression with stretching exercises and massage. When these approaches are unsuccessful, ultrasound-guided perineural injection of the sciatic nerve with LA and corticosteroids can be used as a safe and effective procedure with good symptom relief,

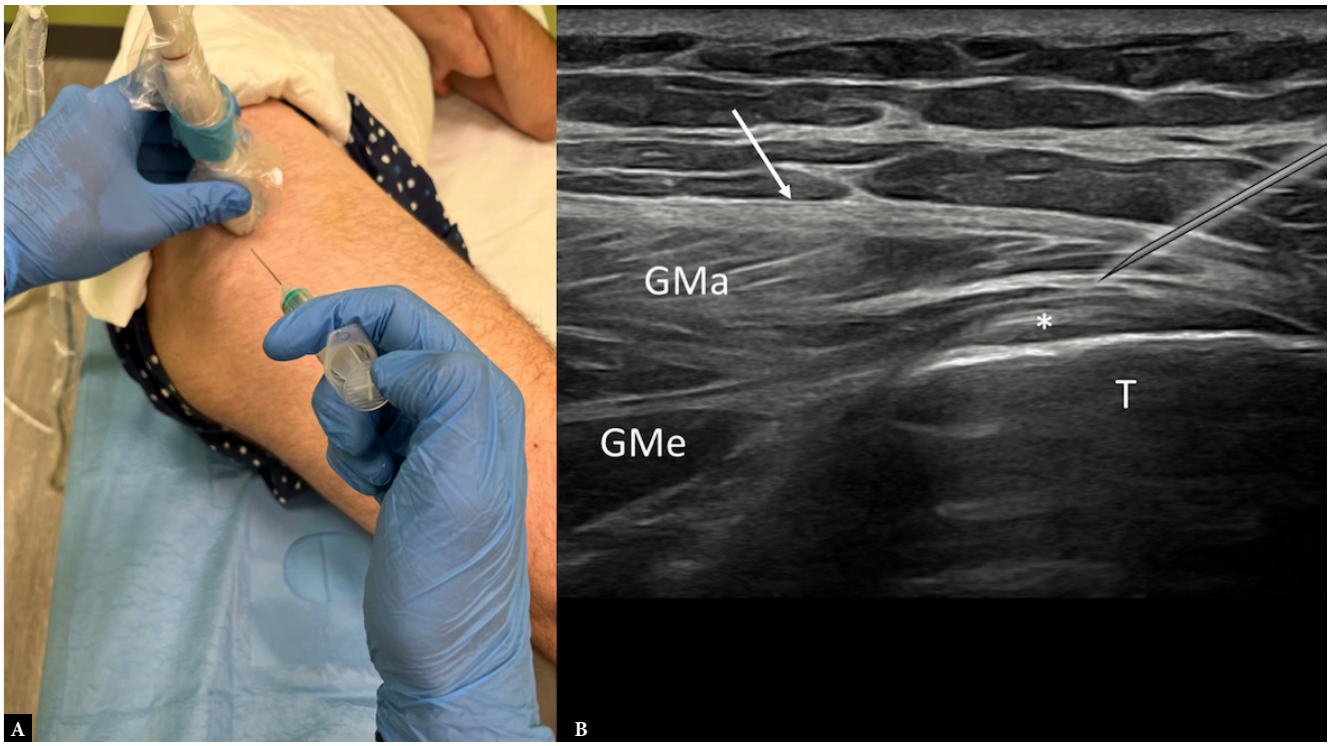

Fig. 3. *Ultrasound-guided greater trochanter injection.* **A.** *The patient is in lateral position on the unaffected side, with a linear probe placed in longitudinal position on the greater trochanter.* **B.** *The ultrasound image shows the middle facet of the greater trochanter (T), the insertion of the gluteus medius tendon (asterisk) and the needle that is advanced with in-plane caudal-to-cranial approach to reach the tendon beneath the fascia lata (arrow). GMa – gluteus maximus muscle; GMe – gluteus medius muscle*

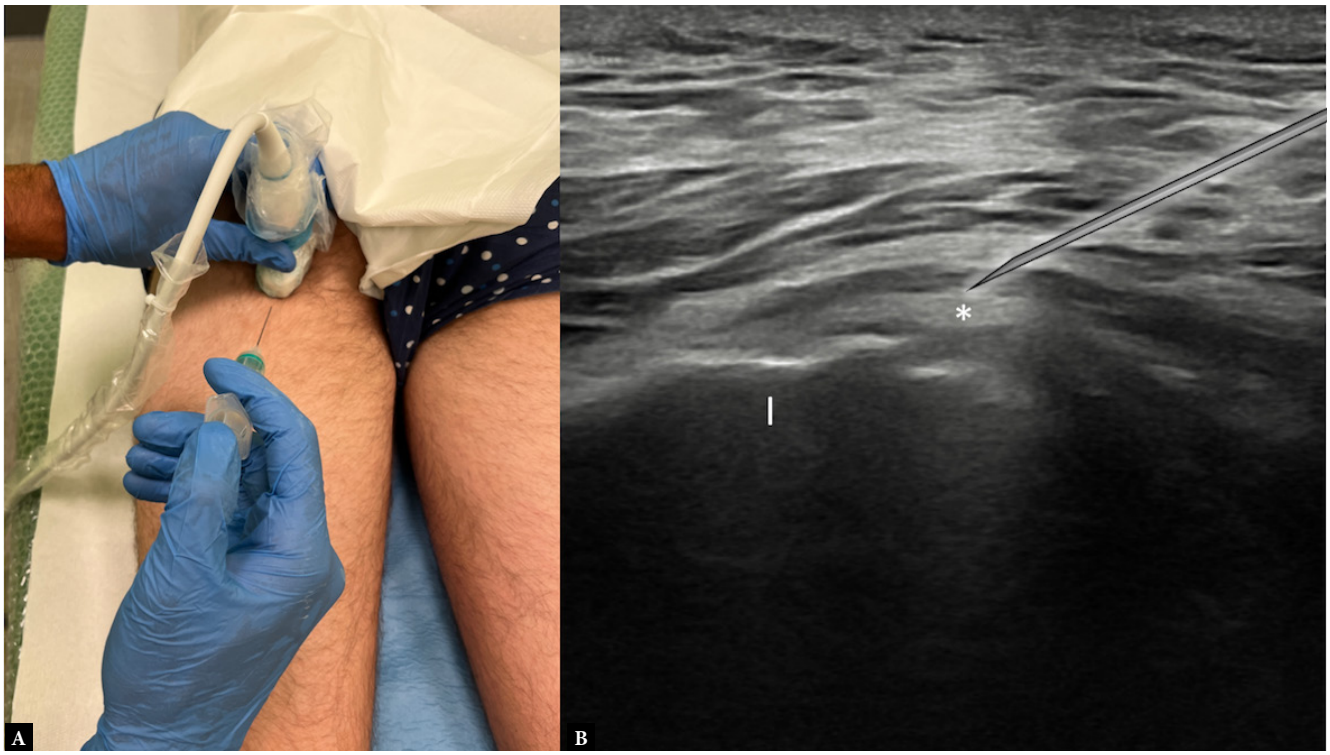

Fig. 4. *Ultrasound-guided hamstrings injection.* **A.** *The patient is prone, with the probe being placed in longitudinal position on the ischial tuberosity.* **B.** *The needle in inserted with in-plane caudal-to-cranial approach to reach the ischial insertion of hamstring tendons (asterisk). I – ischial tuberosity*

even though it is not clear if the addition of steroids to LA may improve the therapeutic efficacy of this intervention[13,26]. Alternatively, small cases series have highlighted the potential value of ultrasound-guided injection of botulinum toxin A in the piriformis muscle for treating this compression neuropathy, probably due to atrophy and fatty infiltration of the muscle[13,27]. Of note, ultrasound-guided sciatic nerve block is one of the most reliable diagnostic modalities to confirm the presence of piriformis syndrome[28]. The hydrodissection technique is a valuable interventional procedure which, by including more saline in the mixture, helps prevent immediate dense block and ensures the dissection of the nerve from the surrounding tissues. Indeed, this intervention has been shown to provide 84% immediate pain relief and 47% sustained pain relief[29].

Technique

The patient is in prone position and the probe (linear or convex based on patient habitus) is placed in the transverse plane to identify the sciatic nerve on the posterior proximal thigh between the long head of the biceps femoris muscle (laterally and superficially), the semimembranosus muscle (medially and superficially), and the adductor magnus (deeply). Then, sliding the probe proximally, the nerve should be followed cranially to the ischial tuberosity, where it is located between the gluteus maximus and pelvitrochanteric muscles (gemellus superior, gemellus inferior, obturator internus, and quadratus femoris) just before encountering the piriformis muscle in the ischiofemoral space. At this level, the nerve can be reached by advancing a 20–22 G × 9 cm spinal needle with in-plane lateral-to-medial approach (Fig. 5). Generally, a large volume of solution (20 ml of a mixture of corticosteroid, lidocaine and saline) is injected around the nerve to debride the perisciatic fascial planes, obtaining the hydrodissection of the nerve.

Lateral femoral cutaneous nerve

Patients with lateral femoral cutaneous nerve (LFCN) compression, namely meralgia paresthetica, present sensory symptoms and pain in the antero-lateral part of the thigh. Ultrasound-guided interventions can be considered when oral drugs and conservative therapies fail[30]. Hence, the block of the LFCN can be used as an alternative treatment of meralgia paresthetica with good results, particularly when injecting corticosteroids and LA at multiple levels along the LFCN, with complete response in about three quarters of patients[13,31,32]. This intervention can also be used for obtaining postoperative regional analgesia after reconstructive surgery with a skin graft or in patients subjected to THA[13]. LFCN ablation may be considered as an alternative option in patients with refractory meralgia paresthetica using ethanol neurolysis, cryoneurolysis, or pulsed radiofrequency ablation, but the evidence is still limited given that only small case series have been published.

Technique

The patient is in supine position. The linear probe is placed in the transverse plane at the level of the anterior superior iliac spine. Then,

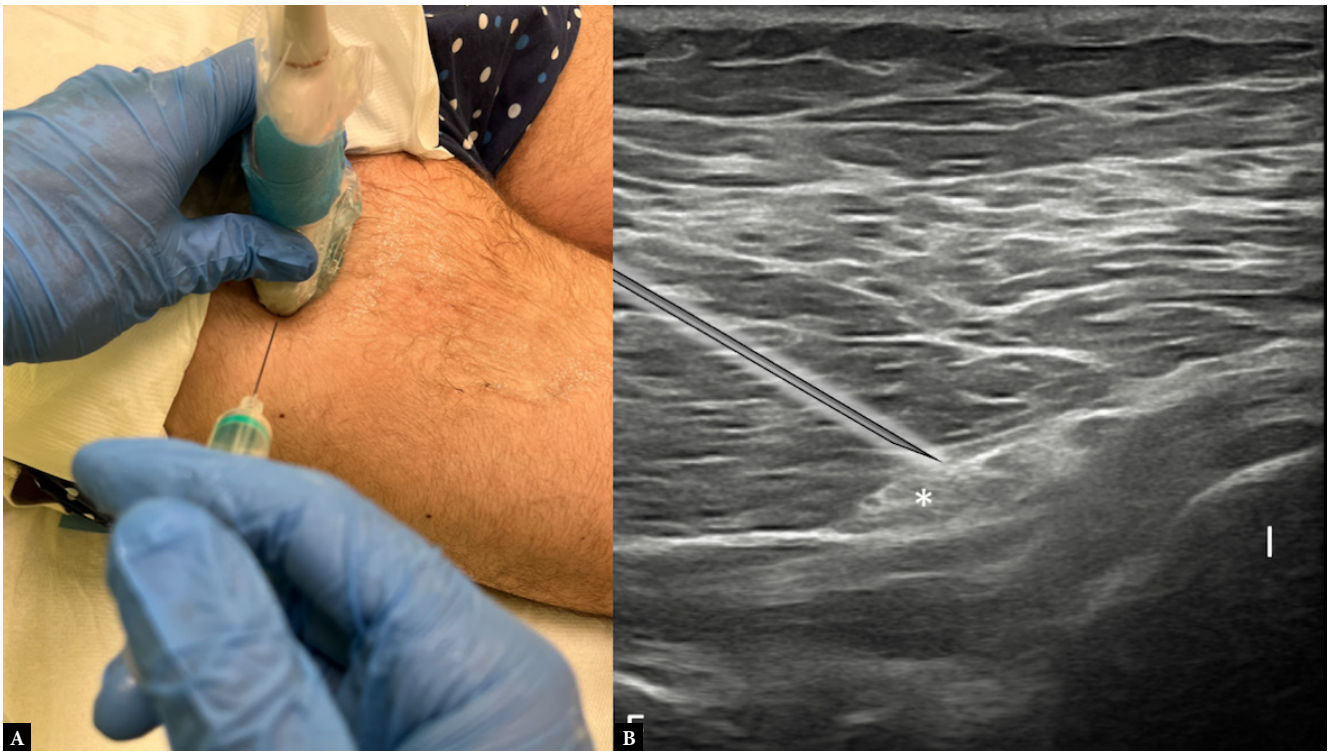

Fig. 5. *Ultrasound-guided sciatic nerve injection.* **A.** *The patient is prone, and the probe is placed in transverse position to scan the sciatic nerve on the posterior aspect of the buttock.* **B.** *The sciatic nerve is identified in the ischiofemoral space between the gluteus maximus (superficially) and pelvitrochanteric muscles (deeply and medially), with the needle being advanced with in-plane lateral-to-medial approach. I – ischium; F – femur*

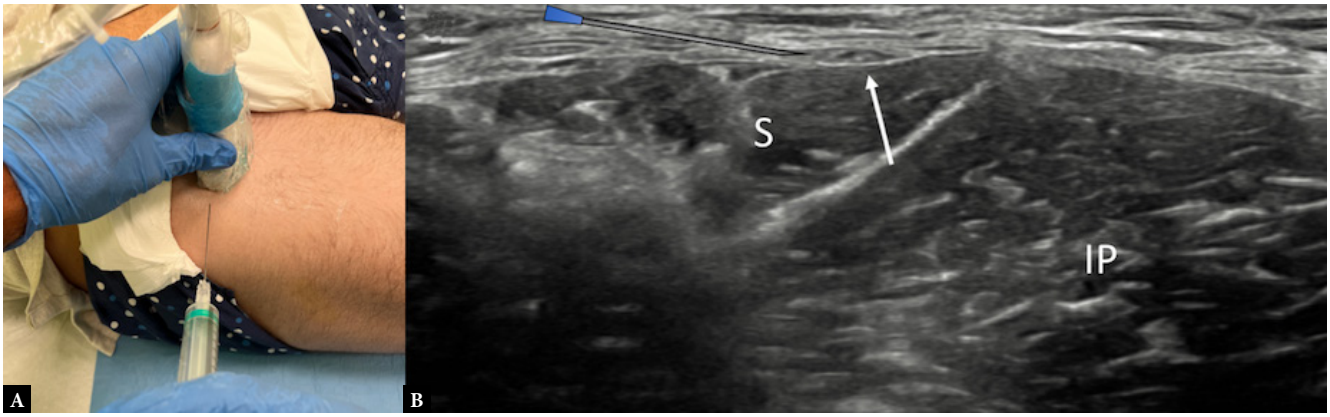

Fig. 6. *Ultrasound-guided injection of the lateral femoral cutaneous nerve.* **A.** *The patient is supine, and the linear probe is in transverse position at the level of the anterior superior iliac spine.* **B.** *The needle is advanced with in-plane lateral-to-medial approach to reach the lateral femoral cutaneous nerve (arrow) beneath the inguinal ligament and superficial to the sartorius muscle (S). IP – iliopsoas muscle*

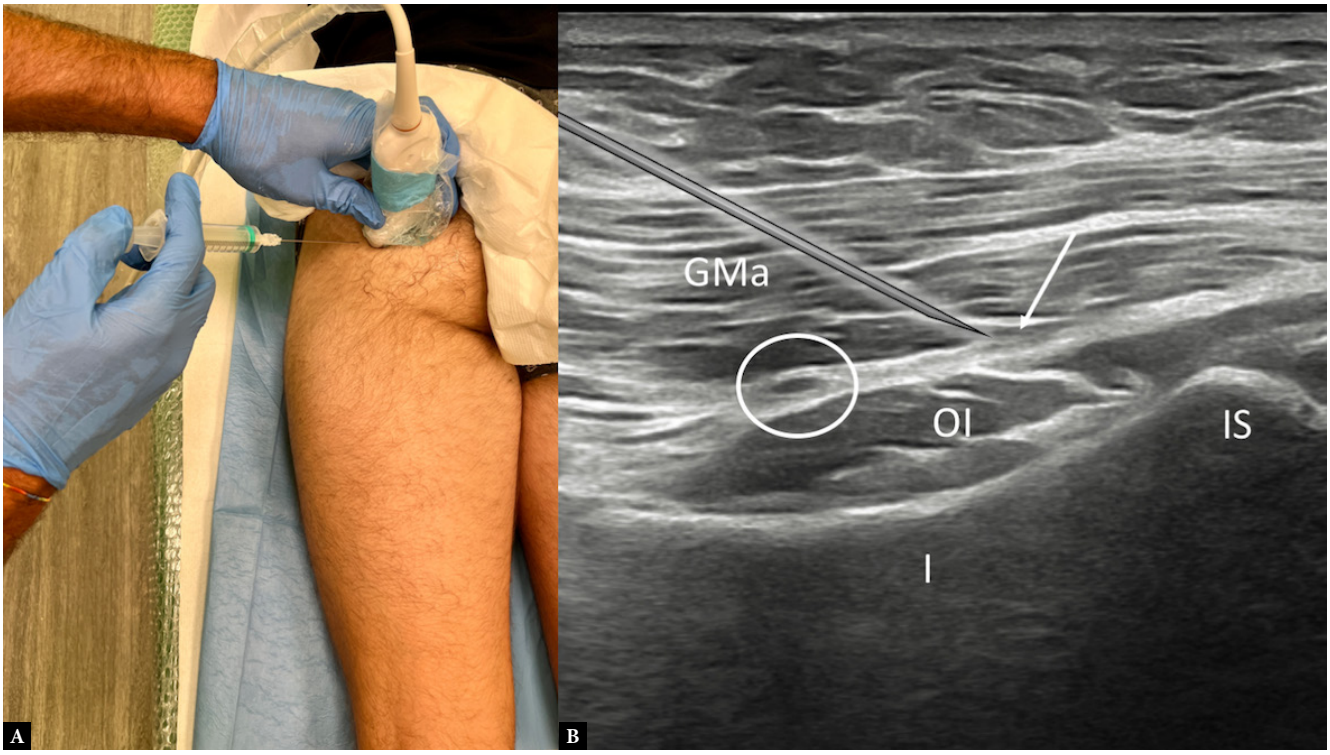

Fig. 7. *Ultrasound-guided injection of the pudendal nerve.* **A.** *The patient is prone, and the linear transducer is placed in oblique position at the level of the ischiatic spine.* **B.** *The pudendal nerve (arrow) is identified medial to the pudendal artery (within the circle) between the gluteus maximus muscle (GMa) and the obturator internus muscle (OI). Once identified, the needle can be advanced with in-plane lateral-to-medial approach. I – ischial bone; IS – ischial spine*

the transducer can be slightly rotated to be placed parallel to the inguinal ligament to identify the LFCN and its branches. The needle is inserted with in-plane lateral-to-medial approach and advanced to reach the nerve at the level of maximum thickening (Fig. 6). Then, a mixture of LA and corticosteroids can be injected.

Pudendal nerve

Patients with pudendal neuralgia generally present with pain from the anus to the penis or the clitoris, particularly when sitting. Ultrasound-guided pudendal perineural injection is a useful therapeutic procedure that can also be used to confirm the diagnosis in doubtful cases[33]. Previous randomized controlled studies have shown the safety and effectiveness of this intervention, without significant differences noted between ultrasound-guided and fluoroscopy-guided procedures[13,34].

Technique

The pudendal nerve can be approached in different ways, with the patient in prone position (with the posterior or medial approach) or in gynecological position (anterior approach)[35]. The most com-

monly used one is the posterior approach, with the patient prone, and the linear or convex probe at the level of the ischiatic spine. Here, the pudendal nerve can be identified medially, between the pudendal artery (located using color Doppler) and the sacrotuberous ligament. Once identified, the nerve can be reached by inserting the needle with in-plane lateral-to-medial approach (Fig. 7).

Conclusions

Ultrasound guidance improves safety and accuracy in providing access to the hip joint and tendons, bursae, and nerves of the hip area, and allows safe and effective management of several musculoskeletal conditions. Thorough knowledge of anatomy is key to correctly reaching the target and avoiding damage to the surrounding structures.

Conflict of interest

The authors do not report any financial or personal connections with other persons or organizations which might negatively affect the contents of this publication and/or claim authorship rights to this publication.

Author contributions

Original concept of study: DA, LMS, CM. Writing of manuscript: DA, SG, FS, CM. Analysis and interpretation of data: DA. Final approval of manuscript: DA, SG, FS, AA, LMS, CM. Collection, recording and/or compilation of data: DA. Critical review of manuscript: DA, SG, FS, AA, LMS, CM.

References

1. Kurtz S, Mowat F, Ong K, Chan N, Lau E, Halpern M: Prevalence of primary and revision total hip and knee arthroplasty in the United States from 1990 through 2002. J Bone Joint Surg Am 2005; 87: 1487–1497. doi: 10.2106/JBJS.D.02441.
2. Sconfienza LM, Chianca V, Messina C, Albano D, Pozzi G, Bazzocchi A: Upper limb interventions. Radiol Clin North Am 2019; 57: 1073–1082. doi: 10.1016/j.rcl.2019.05.002
3. Tortora S, Messina C, Gitto S, Chianca V, Serpi F, Gambino A *et al.*: Ultrasound-guided musculoskeletal interventional procedures around the shoulder. J Ultrason 2021; 21: e162–e168. doi: 10.15557/JOU.2021.0026.
4. Albano D, Chianca V, Tormenta S, Migliore A, Sconfienza LM: Old and new evidence concerning the crucial role of ultrasound in guiding intra-articular injections. Skeletal Radiol 2017; 46: 963–964. doi: 10.1007/s00256-017-2644-3.
5. Sconfienza LM, Albano D, Allen G, Bazzocchi A, Bignotti B, Chianca V *et al.*: Clinical indications for musculoskeletal ultrasound updated in 2017 by European Society of Musculoskeletal Radiology (ESSR) consensus. Eur Radiol 2018; 28: 5338–5351. doi: 10.1007/s00330-018-5474-3.
6. Chianca V, Orlandi D, Messina C, Albano D, Corazza A, Rapisarda S *et al.*: Interventional therapeutic procedures to treat degenerative and inflammatory musculoskeletal conditions: state of the art. Radiol Med 2019; 124: 1112–1120. doi: 10.1007/s11547-019-01018-8.
7. Sconfienza LM, Adriaensen M, Albano D, Allen G, Aparisi Gómez MP, Bazzocchi A *et al.*: Clinical indications for image-guided interventional procedures in the musculoskeletal system: a Delphi-based consensus paper from the European Society of Musculoskeletal Radiology (ESSR) – part I, shoulder. Eur Radiol 2020; 30: 903–913. doi: 10.1007/s00330-019-06419-x.
8. Sconfienza LM, Adriaensen M, Albano D, Aparisi Gómez MP, Bazzocchi A, Beggs I *et al.*: Clinical indications for image-guided interventional procedures in the musculoskeletal system: a Delphi-based consensus paper from the European Society of Musculoskeletal Radiology (ESSR) – part II, elbow and wrist. Eur Radiol 2020; 30: 2220–2230. doi: 10.1007/s00330-019-06545-6.
9. Sconfienza LM, Adriaensen M, Albano D, Allen G, Aparisi Gómez MP, Bazzocchi A *et al.*: Clinical indications for image guided interventional procedures in the musculoskeletal system: a Delphi-based consensus paper from the European Society of Musculoskeletal Radiology (ESSR) – part III, nerves of the upper limb. Eur Radiol 2020; 30: 1498–1506. doi: 10.1007/s00330-019-06479-z.
10. Sconfienza LM, Adriaensen M, Alcala-Galiano A, Allen G, Aparisi Gómez MP, Aringhieri G *et al.*: Clinical indications for image guided interventional procedures in the musculoskeletal system: a Delphi-based consensus paper from the European Society of Musculoskeletal Radiology (ESSR) – part IV, hip. Eur Radiol 2022; 32: 551–560. doi: 10.1007/s00330-021-07997-5.
11. Sconfienza LM, Adriaensen M, Albano D, Alcala-Galiano A, Allen G, Aparisi Gómez MP *et al.*: Clinical indications for image-guided interventional procedures in the musculoskeletal system: a Delphi-based consensus paper from the European Society of Musculoskeletal Radiology (ESSR) – part V, knee. Eur Radiol 2022; 32: 1438–1447. doi: 10.1007/s00330-021-08258-1.
12. Sconfienza LM, Adriaensen M, Albano D, Alcala-Galiano A, Allen G, Aparisi Gómez MP *et al.*: Clinical indications for image-guided interventional procedures in the musculoskeletal system: a Delphi-based consensus paper from the European Society of Musculoskeletal Radiology (ESSR) – part VI, foot and ankle. Eur Radiol 2022; 32: 1384–1394. doi: 10.1007/s00330-021-08125-z.
13. Sconfienza LM, Adriaensen M, Albano D, Alcala-Galiano A, Allen G, Aparisi Gómez MP *et al.*: Clinical indications for image-guided interventional procedures in the musculoskeletal system: a Delphi-based consensus paper from the European Society of Musculoskeletal Radiology (ESSR) – part VII, nerves of the lower limb. Eur Radiol 2022; 32: 1456–1464. doi: 10.1007/s00330-021-08283-0.
14. Atchia I, Kane D, Reed MR, Isaacs JD, Birrell F: Efficacy of a single ultrasound-guided injection for the treatment of hip osteoarthritis. Ann Rheum Dis 2011; 70: 110–116. doi: 10.1136/ARD.2009.127183.
15. Silvestri E, Barile A, Albano D, Messina C, Orlandi D, Corazza A *et al.*: Interventional therapeutic procedures in the musculoskeletal system: an Italian Survey by the Italian College of Musculoskeletal Radiology. Radiol Medica 2018; 123: 314–321. doi: 10.1007/s11547-017-0842-7.
16. Hoeber S, Aly AR, Ashworth N, Rajasekaran S: Ultrasound-guided hip joint injections are more accurate than landmark-guided injections: a systematic review and meta-analysis. Br J Sports Med 2016; 50: 392–396. doi: 10.1136/BJSPORTS-2014-094570.
17. Sconfienza LM, Albano D, Messina C, Silvestri E, Tagliafico AS: How, when, why in magnetic resonance arthrography: An international survey by the European society of musculoskeletal radiology (ESSR). Eur Radiol 2018; 28: 2356–2368. doi: 10.1007/s00330-017-5208-y.
18. Lynch TS, Steinhaus ME, Popkin CA, Ahmad CS, Rosneck J: Outcomes after diagnostic hip injection. Arthroscopy 2016; 32: 1702–1711. doi: 10.1016/J.ARTHRO.2016.02.027.
19. Ayeni OR, Farrokhyar F, Crouch S, Chan K, Sprague S, Bhandari M: Pre-operative intra-articular hip injection as a predictor of short-term outcome following arthroscopic management of femoroacetabular impingement. Knee Surg Sports Traumatol Arthrosc 2014; 22: 801–805. doi: 10.1007/S00167-014-2883-Y.
20. Albano D, Messina C, Zagra L, Andreata M, De Vecchi E, Gitto S *et al.*: Failed total hip arthroplasty: diagnostic performance of conventional MRI features and locoregional lymphadenopathy to identify infected implants. J Magn Reson Imaging 2021; 53: 201–210. doi: 10.1002/JMRI.27314.
21. Sconfienza LM, Albano D, Messina C, D'Apolito R, De Vecchi E, Zagra L: Ultrasound-guided periprosthetic biopsy in failed total hip arthroplasty: a novel approach to test infection in patients with dry joints. J Arthroplasty 2021; 36: 2962–2967. doi: 10.1016/J.ARTH.2021.03.029.
22. Adler RS, Buly R, Ambrose R, Sculco T: Diagnostic and therapeutic use of sonography-guided iliopsoas peritendinous injections. AJR Am J Roentgenol 2005; 185: 940–943. doi: 10.2214/AJR.04.1207.
23. McEvoy JR, Lee KS, Blankenbaker DG, del Rio AM, Keene JS: Ultrasound-guided corticosteroid injections for treatment of greater trochanteric pain syndrome: greater trochanter bursa versus subgluteus medius bursa. AJR Am J Roentgenol 2013; 201: W313–W317. doi: 10.2214/AJR.12.9443.
24. Ali M, Oderuth E, Atchia I, Malviya A: The use of platelet-rich plasma in the treatment of greater trochanteric pain syndrome: a systematic literature review. J Hip Preserv Surg 2018; 5: 209–219. doi: 10.1093/JHPS/HNY027.
25. Nasser AM, Vicenzino B, Grimaldi A, Anderson J, Semciw AI: Proximal hamstring tendinopathy: a systematic review of interventions. Int J Sports Phys Ther 2021; 16: 288–305.
26. Misirlioglu TO, Akgun K, Palamar D, Erden MG, Erbilir T: Piriformis syndrome: comparison of the effectiveness of local anesthetic and corticosteroid injections:

a double-blinded, randomized controlled study – PubMed. Pain Physician 2015; 18: 163–171.

27. Rodríguez-Piñero M, Vargas VV, Jiménez Sarmiento AS: Long-term efficacy of ultrasound-guided injection of incobotulinumtoxinA in piriformis syndrome. Pain Med 2018; 19: 408–411. doi: 10.1093/pm/pnx135.
28. Siahaan YMT, Tiffani P, Tanasia A: Ultrasound-guided measurement of piriformis muscle thickness to diagnose piriformis syndrome. Front Neurol 2021; 12. doi: 10.3389/FNEUR.2021.721966.
29. Burke CJ, Walter WR, Adler RS: Targeted ultrasound-guided perineural hydrodissection of the sciatic nerve for the treatment of piriformis syndrome. Ultrasound Q 2019; 35: 125–129. doi: 10.1097/RUQ.0000000000000360.
30. Burica Matičič U, Šumak R, Omejec G, Salapura V, Snoj Ž: Ultrasound-guided injections in pelvic entrapment neuropathies. J Ultrason 2021; 21: e139–e146. doi: 10.15557/JOU.2021.0023.
31. Klauser AS, Abd Ellah MMH, Halpern EJ, Sporer I, Martinoli C, Tagliafico A *et al.*: Meralgia paraesthetica: ultrasound-guided injection at multiple levels with 12-month follow-up. Eur Radiol 2016; 26: 764–770. doi: 10.1007/s00330-015-3874-1.
32. Tagliafico A, Serafini G, Lacelli F, Perrone N, Valsania V, Martinoli C: Ultrasound-guided treatment of meralgia paresthetica (lateral femoral cutaneous neuropathy): Technical description and results of treatment in 20 consecutive patients. J Ultrasound Med 2011; 30: 1341–1346. doi: 10.7863/jum.2011.30.10.1341.
33. Drakonaki EE, Adriaensen MEAPM, Al-Bulushi HIJ, Koliarakis I, Tsiaoussis J, Vanderdood K: Sonoanatomy of the ilioinguinal, iliohypogastric, genitofemoral, obturator, and pudendal nerves: a practical guide for US-guided injections. J Ultrason 2022; 22: e44–e50. doi: 10.15557/JOU.2022.0008.
34. Bellingham GA, Bhatia A, Chan CW, Peng PW: Randomized controlled trial comparing pudendal nerve block under ultrasound and fluoroscopic guidance. Reg Anesth Pain Med 2012; 37: 262–266. doi: 10.1097/AAP.0b013e318248c51d.
35. Tagliafico A, Perez MM, Martinoli C: High-resolution ultrasound of the pudendal nerve: normal anatomy. Muscle Nerve 2013; 47: 403–408. doi: 10.1002/MUS.23537.