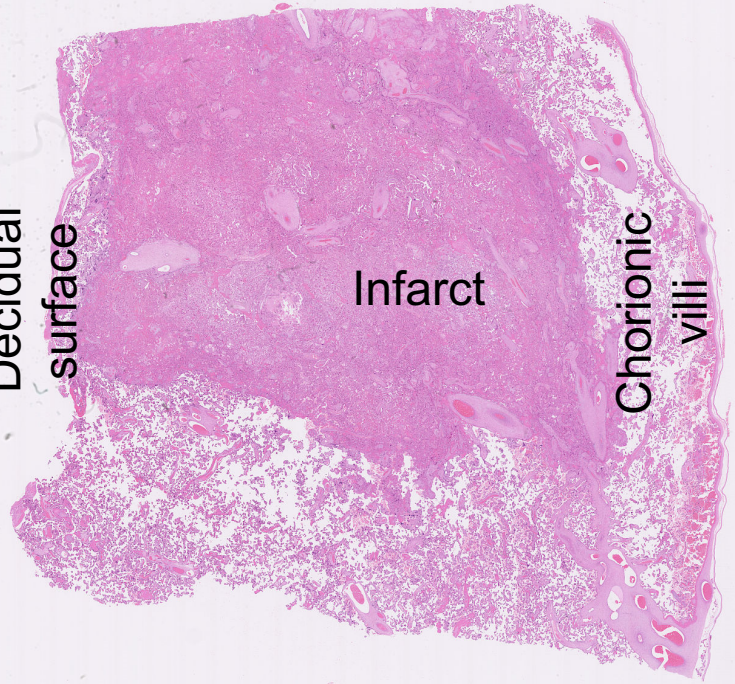


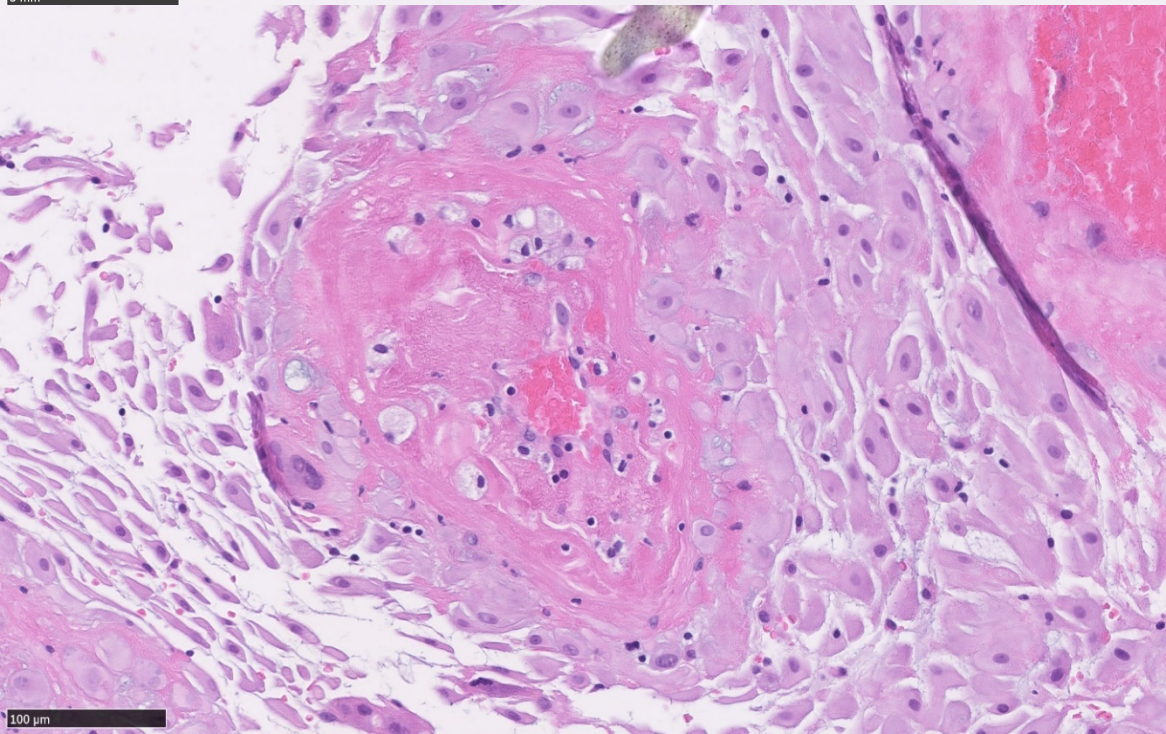
Decidual surface

Infarct

Chorionic villi



5 mm



100 µm