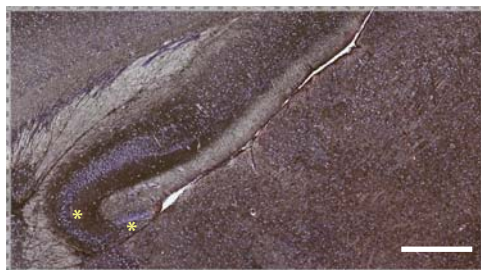



A

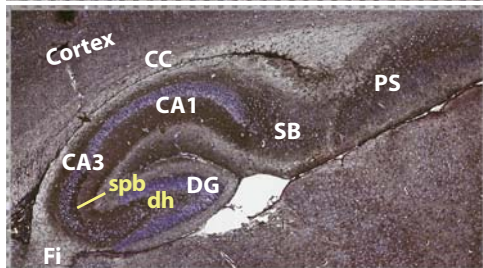
Control

bKO

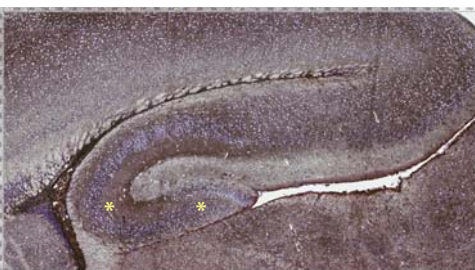
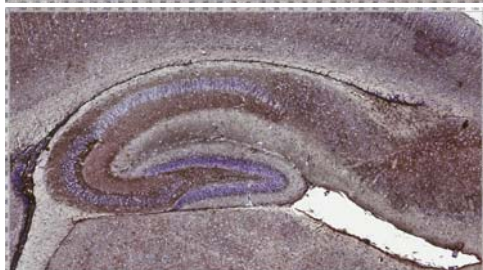
Medial

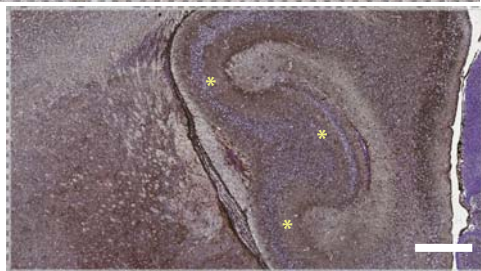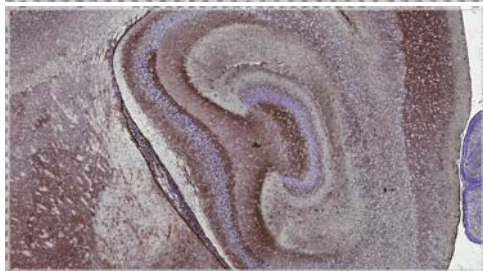B



C



D



Lateral

Sagittal Sections

E

