

Issue 6 at a glance >>>

- *Topic of the issue*
- *Practical tip*
- *Case of the issue*
- *ENMUS news*



A Periodical insight into the Neuromuscular Ultrasound field & the Egyptian Neuromuscular Ultrasound Society

ENMUS Bulletin


ISSUE 6 - OCTOBER 15, 2021

Practical tip >>>

To ensure optimum nerve imaging:

- 1-Adjust the depth, focus & frequency as you trace the nerve along its course & moving from one level to another.
- 2-Keep your target nerve in the middle of the screen at all times.
3. Make sure the probe is orthogonal to the nerve.
4. Make sure that you are in a true axial view before taking measurements.
5. Nerve tracing is all about visual tracking, so follow the nerve on the screen at all times. With practice, you will achieve good eye-hand coordination ..**ENJOY TRACING!**

Quote of the issue >>>



'Be the reason someone smiles. Be the reason someone feels loved and believes in the goodness in people'
Roy T. Bennet

Topic of the issue

The clinical-EDX-NMUS correlation

By Dr. Eman Tawfik, Professor of PMR, Faculty of Medicine, ASU & the President of the Egyptian Neuromuscular Ultrasound Society

Neuromuscular ultrasound is a tool that allows structural assessment of the nerves & muscles. As such, it complements the electrodiagnostic tests (EDX) that provide the functional assessment. It is well-known that EDX tests are considered as extension of the clinical examination. Similarly, NMUS is considered an extension of both the clinical and the EDX assessments.^{1,2} Consequently, the neuromuscular ultrasound findings should be interpreted in the context of the clinical and electrodiagnostic findings and as always recommended, the ideal NMUS report is a report that combine the NMUS and EDX and the final conclusion should correlate them together.

So, what are the qualifications you need for accurate interpretation of NMUS?

In a 'Position Statement' issued by the AANEM³ and addresses neuromuscular ultrasound qualifications, the panel provided

9 prerequisites for the performance and interpretation of NMUS to achieve proficiency in this field.

These prerequisites are distinct from those needed for musculoskeletal ultrasound.³ As stated in the statement, 6 out of these 9 prerequisites are also required for proficiency in electrodiagnostic medicine. Thus, many physiatrists and neurologists already possess many of the skills needed for NMUS.³ Based on this fact, the physicians who work in the EDX field are best suited to perform NMUS and are the most capable of correlating the clinical-EDX-NMUS findings. Moreover, since patients with neuromuscular disorders are routinely referred for electrodiagnostic testing, the EMG laboratory is an ideal setting for physicians to acquire, refine and apply skills in neuromuscular ultrasound.³

The approach towards optimum interpretation of NMUS in the correct context:

1. History taking
2. Meticulous neurological examination is a must.
3. The common approach is to start with the electrodiagnostic tests

Then plan the NMUS scanning protocol based on the EDX findings. However, you may need to perform further EDX tests after NMUS if another unexpected lesion or more widespread lesion is found in NMUS. This is another reason why the same physician should perform both tests because of this need to modify the EDX approach or vice versa and why the ideal setting of the ultrasound machine is inside the EMG labs.

4. In some situations, you may need to start with NMUS prior to EDX tests as in cases of ALS to screen for fasciculations to increase the yield of finding them in EMG study, or in cases with multifocal motor neuropathy or CIDP to increase the yield of finding sites of focal conduction block. Moreover, you may use NMUS first in children or in patients who are phobic to EDX tests or cannot tolerate the electrical stimulation.⁴

References

1. Gonzalez NL, Hobson-Webb LD. Neuromuscular ultrasound in clinical practice: A review. *Clin Neurophysiol Pract.* 2019;4:148-163.
2. Suk JI, Walker FO, Cartwright MS. Ultrasonography of peripheral nerves. *Curr Neurol Neurosci Rep.* 2013;13:328.
3. Walker FO, Alter KE, Boon AJ, Cartwright MS, Flores VH, Hobson-Webb LD, Hunt CH, Primack SJ, Shook SJ. Qualifications for practitioners of neuromuscular ultrasound: position statement of the American Association of Neuromuscular and Electrodiagnostic Medicine. *Muscle Nerve.* 2010;42:442-4.
4. Walker FO, Cartwright MS, Alter KE, Visser LH, Hobson-Webb LD, Padua L, Strakowski JA, Preston DC, Boon AJ, Axer H, van Alfen N, Tawfik EA, Wilder-Smith E, Yoon JS, Kim BJ, Breiner A, Bland JDP, Grimm A, Zaidman CM. Indications for neuromuscular ultrasound: Expert opinion and review of the literature. *Clin Neurophysiol.* 2018;129:2658-79.

Case of the Issue

By Prof. Eman Tawfik

A 35-year-old man was referred to the EMG lab for hand and wrist weakness after an extensive burn injury of the right arm and forearm (Photo) of 3 months duration. He was treated with skin grafting. NCS of the median, ulnar and radial nerves failed to elicit CMAPs and SNAPs from the 3 nerves at all stimulation sites. Needle EMG showed profuse denervation in all studied muscles (APB, ADM, FCU, EI, ED) and no MUAPs could be recorded, except from the extensor digitorum from which scanty small MUAPs could be recorded but no signs of reinnervation. Ultrasound scanning of the median, ulnar and radial nerves was performed. The nerves were traced along their entire course from the wrist to the axilla. There was continuity of all nerves with no evidence of transection at any point, and no evidence of neuroma. The provided panels show clear visualization of the ulnar nerve along its entire course from the wrist to the axilla. The median and radial nerve were also visualized along their entire courses. Of note, the muscles of the forearm compartments showed altered echogenicity with focal areas of hyperechogenicity due to the thermal injury.

EDX-NMUS correlation: The above electrodiagnostic picture can be seen in both severe axonotemesis and neurotemesis. The continuity of the nerves as revealed in ultrasound denotes that the above EDX findings reflect severe axonotemesis rather than neurotemesis. This case is an applied example of the above topic about EDX-NMUS correlation and shows how to interpret the EDX findings in the context of NMUS findings...

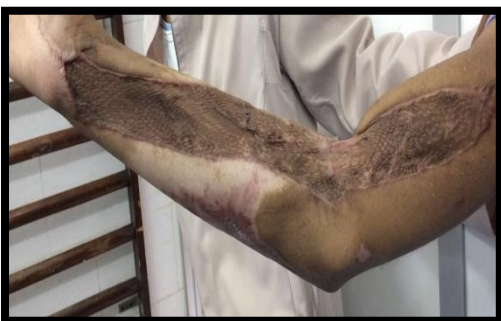

Figure 1: Extensive burn area with lost muscle bulk and elbow flexion deformity.

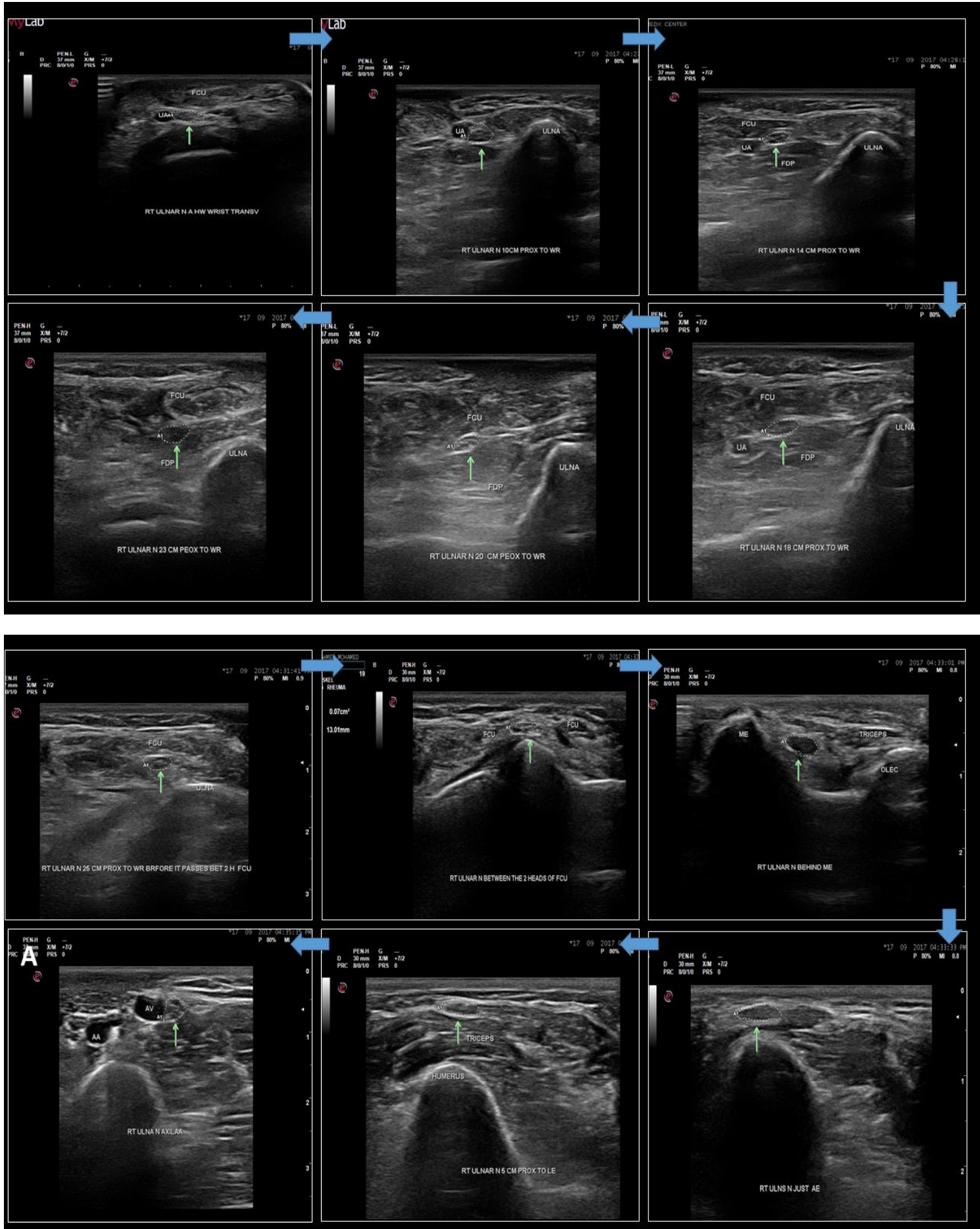




Figure 2: Ulnar nerve tracing

1. **A manuscript addressing the virtual NMUS courses that were planned by the ENMUS during the COVID-19 pandemic has been published last month in Muscle & Nerve**
<https://onlinelibrary.wiley.com/doi/10.1002/mus.27415>

MUSCLE & NERVE

ISSUES & OPINIONS |  Free Access

Virtual neuromuscular ultrasound courses during COVID-19 pandemic: Leveraging technology to enhance learning opportunities

Eman A. Tawfik MD , Nens van Alfen MD, PhD, Michael S. Cartwright MD, MS, Peter Inkpen MD, Antonios Kerasnoudis MD, PhD, Doris Lieba-Samal MD, Natalie Winter MD, Francis O. Walker MD,

First published: 10 September 2021 | <https://doi.org/10.1002/mus.27415>

2. **Renewal of ENMUS membership for the year 2022.**

Because of the social distancing we all experienced during the Covid-19 pandemic, the Egyptian Neuromuscular Ultrasound Society (ENMUS) exempted its members from the membership fees for the last 2 years (2019 & 2020).

As we hope things get better in 2022 and as the ENMUS aims to resume its in-person training courses and scientific activities in full power in 2022, the society membership is now open for the year 2022 starting mid-October and until Mid-January.

- *New members are required to fill out the application form (you can find it in the 'files' section in NMUS Facebook group and send it via email to egyptiannmus@gmail.com*
- *Current members are required to renew their membership and pay the annual fees to preserve their position as society members.*

Follow the educational activities on Fb through >>>>

- Neuromuscular ultrasound group: www.facebook.com/groups/1612728358760236
- The ENMUS page www.facebook.com/EGYPTIANNMUS