

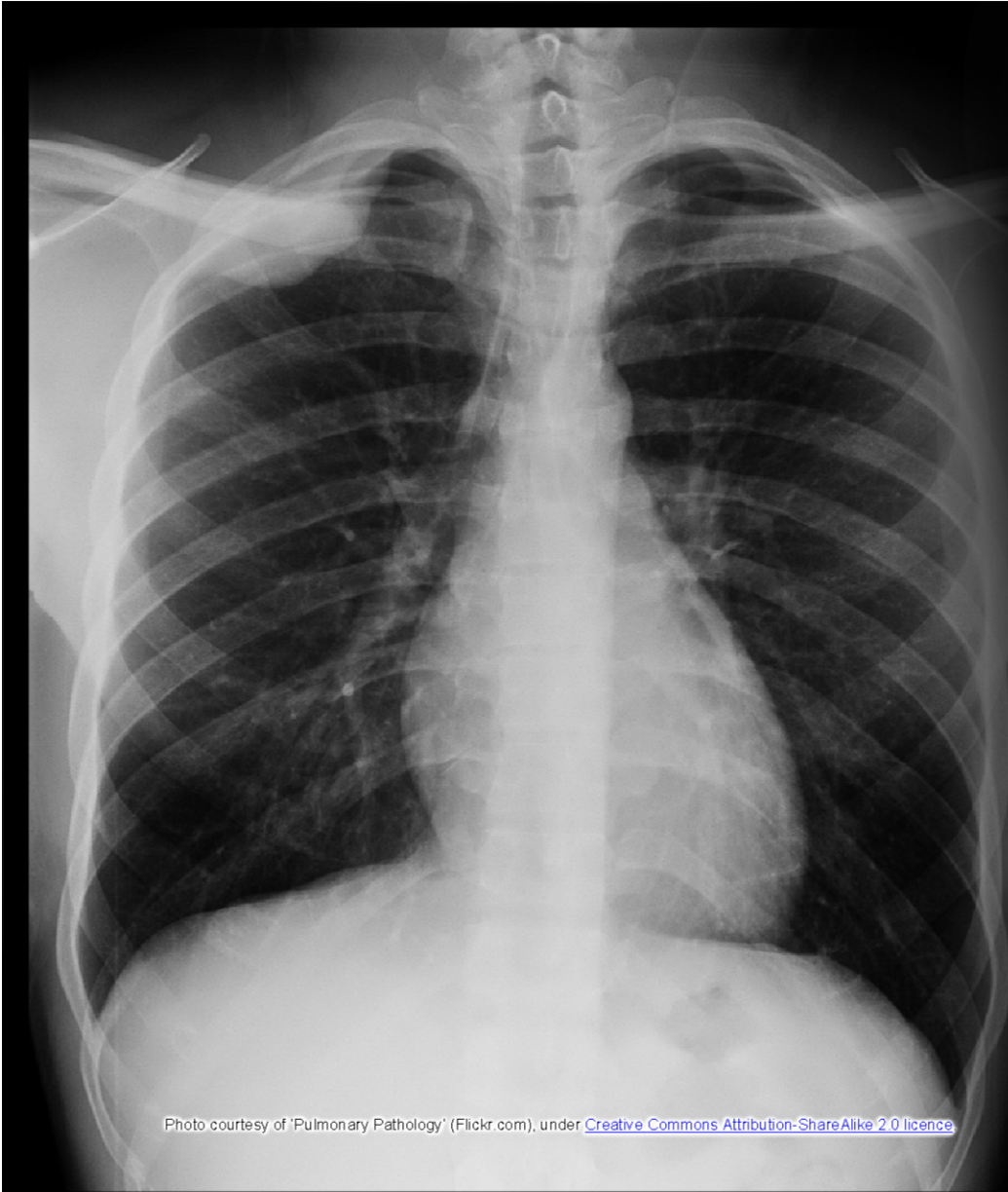

Photo courtesy of 'Pulmonary Pathology' (Flickr.com), under [Creative Commons Attribution-ShareAlike 2.0 licence](https://creativecommons.org/licenses/by-sa/2.0/)

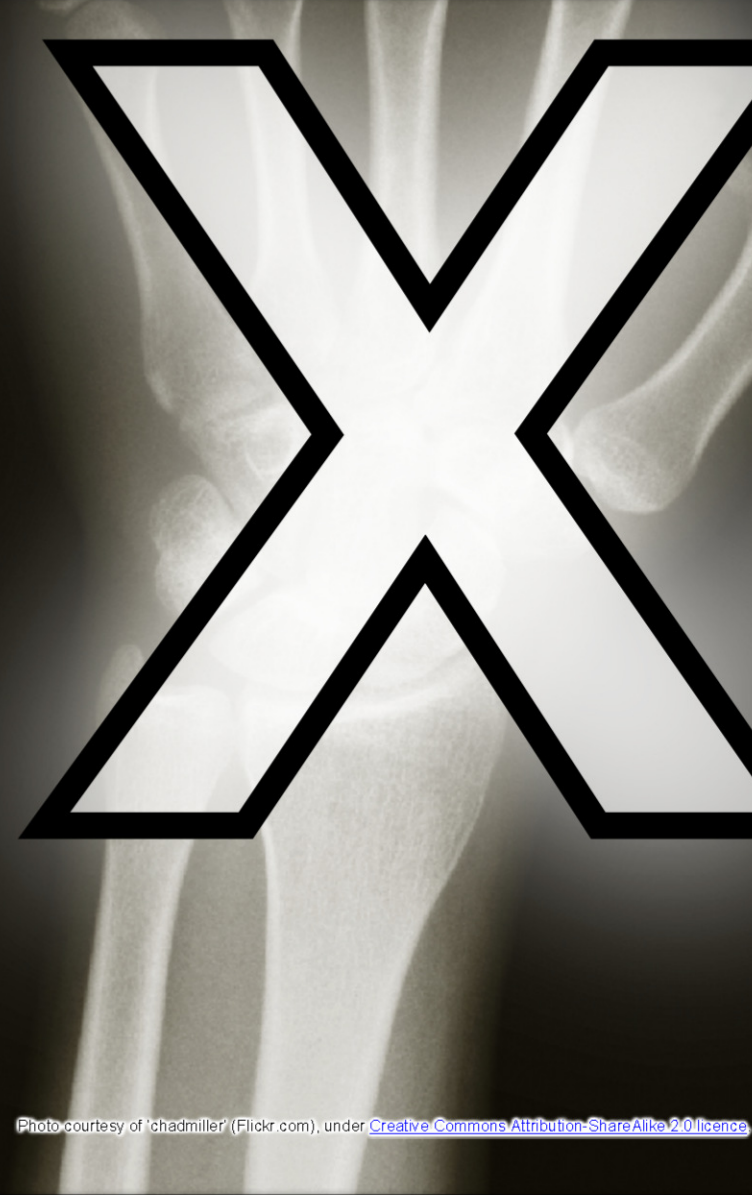

Photo courtesy of 'chadmiller' (Flickr.com), under [Creative Commons Attribution-ShareAlike 2.0 licence](https://creativecommons.org/licenses/by-sa/2.0/)

Se: 1/3

Im: 0/1

Mag: 1.0x

Acc:

2007 May 22

10:38:14.000

# K-Raw

[2.0 licence](#)

Photo courtesy of Minnaert (Flickr.com), under [Creative Commons Attribution-ShareAlike 2.0 licence](#)

W-8101 1-1006

U

S

R

Study 1  
Study 2

COJGR

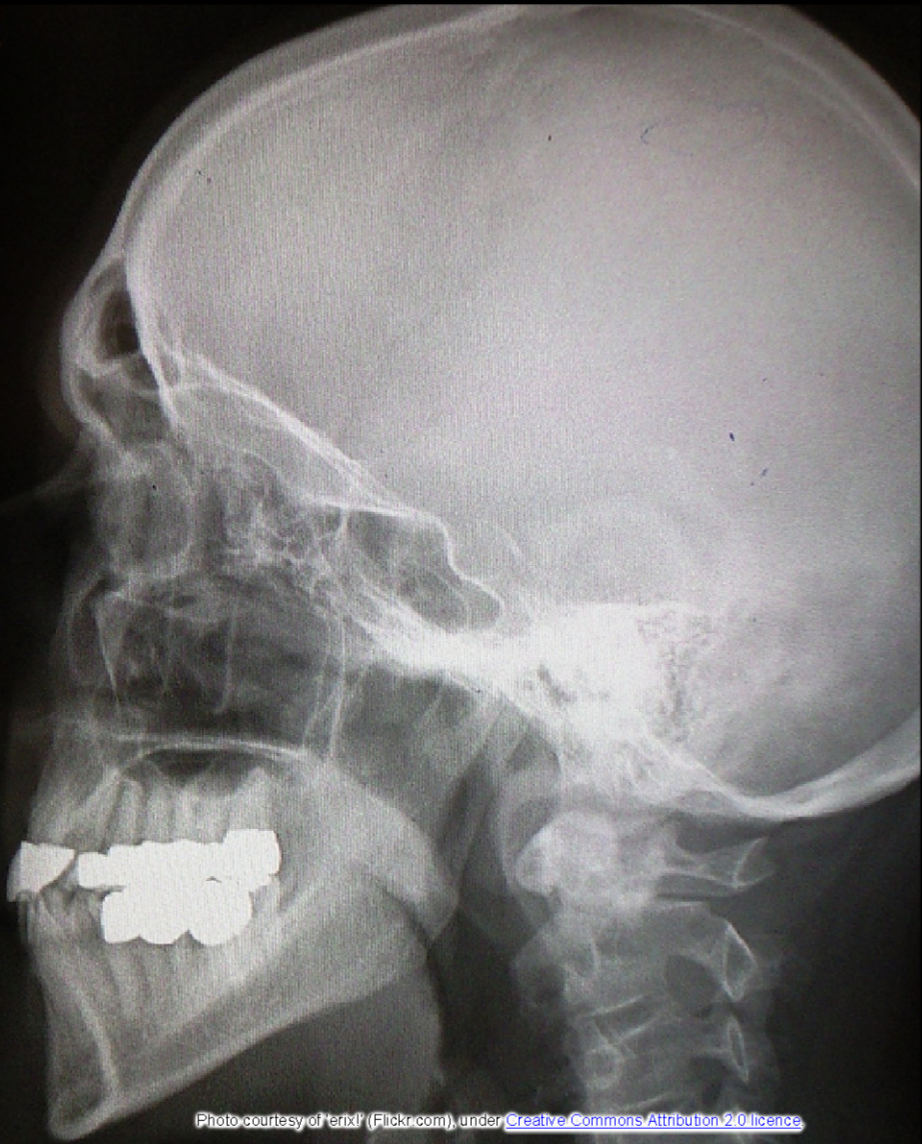


Photo courtesy of 'Laurel Fan' (Flickr.com), under [Creative Commons Attribution-ShareAlike 2.0 licence](#)

Photo courtesy of 'erixl' (Flickr.com), under [Creative Commons Attribution 2.0 licence](#)

© Copyright 2012, [www.sparklebox.co.uk](http://www.sparklebox.co.uk)