

# Venomous Snake Bites in Taiwan

CHI-WEN JUAN<sup>1,2</sup>

*There are six kinds of poisonous snakes with epidemiological significance in Taiwan. Three species induce hemorrhagic symptoms (*Trimeresurus mucrosquamatus*, *Trimeresurus stejnegeri*, and *Deinagkistrodon acutus*), two species induce neurotoxic symptoms (*Naja atra* and *Bungarus multicinctus*) and one species induces hemorrhagic and neurotoxic symptoms (*Vipera russelli formosensis*). The hemorrhagic venom causes disorders of the clotting cascade such as prolonged bleeding, primary fibrinolysis and disseminated intravascular coagulopathy. The neurotoxic venom provokes respiratory distress from weakened respiratory muscles, blurred vision, diplopia, dysarthria, dysphagia, dysphonia and paralysis of muscles of the extremities. Mixed envenomation manifests as a combination of these neurotoxic and hemorrhagic effects as well as rhabdomyolysis and acute renal failure. Identification of the snake species is important if antivenom is to be used. Therefore, guidelines for snakebite identification based on clinical symptoms and laboratory analysis are important to improve the clinical diagnosis of snakebites. In Taiwan, *Trimeresurus stejnegeri* bites are the most common and *Deinagkistrodon acutus* the least common. Aggressive antivenom treatment can reduce the mortality rate for snakebites, but for *Bungarus multicinctus* bites, additional measures such as maintaining the patient's airway and supporting ventilation are vital. Patients with dry bites or bites with no envenomation should be observed for at least 6-12 hours. The emergency physician should determine the severity of envenomation and predominating venom activity before deciding on the type, dosage and duration of antivenin treatment. The history of exposure, local effects and systemic syndromes of envenomation, progression of symptoms and signs, and laboratory data obtained in the emergency department should guide decisions about antivenom therapy. The dosage most toxicologists use for treating pediatric patients with snakebites is the same as that for adults. In general, 6-12 vials of antivenom against neurotoxic venom are used for *Naja atra* bites and two vials are used for *Bungarus multicinctus*. One vial of antivenom against hemotoxic venom is used for both *Trimeresurus stejnegeri* and *Trimeresurus mucrosquamatus* bites. Two vials of anti-*Deinagkistrodon acutus* are used for *Deinagkistrodon acutus* bites and 2-4 vials of anti-*Vipera russelli formosensis* are used for *Vipera russelli formosensis* bite. During the infusion, the blood pressure, level of consciousness and skin reaction should be monitored. The varied clinical manifestations of snake bite must be considered for effective management. Ready availability and appropriate use of antivenom, close monitoring of patients and the institution of ventilatory support all help reduce mortality.*

**Key words:** snake bites, antivenom, hemorrhagic venom, neurotoxic venom

## Introduction

Snakes are poikilotherms, which accounts for their distribution and activity, and they are

mostly active around 25-35°C. They are distributed throughout most of the earth's surface, including fresh and salt water, with only a few exceptions. Snakebites are encountered worldwide. Of the

---

Received: September 1, 2012 Accepted for publication: September 29, 2012  
 From the <sup>1</sup>Department of Emergency Medicine, Kuangtien General Hospital, Taichung  
<sup>2</sup>Department of Nursing, Hungkuang University, Taichung  
 Address reprint requests and correspondence: Dr. Chi-Wen Juan  
 Department of Emergency Medicine, Kuangtien General Hospital, Taichung  
 117 Shatian Road, Shalu District, Taichung City 433, Taiwan (R.O.C.)  
 Tel: (04)26625111 ext 2001 Fax: (04)26655050  
 E-mail: juanchiwen@yahoo.com.tw

3,000 species of snakes, about 10% to 15% are venomous. Of the 14 families of snakes, 5 contain venomous species<sup>(1)</sup>. Venom injected into local tissue causes local and systemic reactions. Clinical findings may vary according to the species and age of the snake, the depth of the bite, the amount of injected venom, and the age, gender and general health status of the victim<sup>(2)</sup>. In 1998, Chippaux published an appraisal of the global situation quoting 114 publications, based mainly on hospital records and health authority statistics. He speculated that the total number of snakebites worldwide each year might exceed five million, with 125,000 deaths from snakebite annually. In Asia there are four million snakebites, two million snakebite envenomings, and 100,000 deaths each year. The incidence of snakebite mortality is particularly high in South-East Asia<sup>(3)</sup>. There are 300 to 600 snakebites reported in Taiwan annually, causing in 20-30 deaths. Males are bitten more frequently than females. Ninety-seven percent of snakebites are on the extremities, and 85% are predominately hematoxin<sup>(1)</sup>. Snakebites are medical emergencies in many parts of the world, especially in rural areas. Agricultural workers and children are most frequently affected. A snakebite is an occupational disease of farmers, plantation workers, herdsmen, fishermen, snake restaurant workers and other food producers<sup>(4)</sup>.

The two major venomous snake families are the vipers and the elapids. The viper family, among which are copperheads and rattlesnakes, typically have a triangle-shaped head, which elapids do not have. Elapids include the death adders, cobras, mambas, sea snakes, and coral snakes. They possess hollow fixed fangs, unlike vipers which have folding fangs. The fangs of viperids are hypodermic (solenoglyphous), situated at the posterior extremity of the maxilla, and are much larger than those of elapids. The most distinct feature of viperid fangs is that they can

be folded back along the roof of the mouth when not in use. The fangs of elapids are generally shorter than those of viperids. They are situated at the front of the maxilla, a condition known as proteroglyphous. The fangs in elapids are always fixed in an erect position and fit into a pocket in the gum tissue on the outside of the mandible, but inside the lip when the jaw is closed. The base of the fang, attached to the maxilla, is expanded and known as the pedestal. On the anterior surface of the fang there is an opening just below the pedestal, which is called the entrance lumen. The venom duct of the venom gland does not attach directly to the fang, but expands into a small cavity in the gum above the entrance lumen. The discharge orifice, near the distal end of the fang, is used for discharging venom<sup>(5)</sup>. Spitting cobras, African ringhals (*Hemachatus haemachatus*), black-necked cobras (*N. nigricollis*), *N. mossambica*, and some Asian cobras (*Naja naja*), can "spit" venom from their fangs. Loveridge<sup>(6)</sup> reported that *N. nigricollis* can eject venom a maximum of about six feet, and the venom is expelled in separate jets, as illustrated by Bogert<sup>(7)</sup>. Venom in the eyes causes intense pain and inflammation of the conjunctiva and cornea, and may lead to blindness. The spitting technique may be a useful defense mechanism against large animals which attack or accidentally tread on the snake<sup>(8)</sup>. Normally there are two fangs side by side on each maxilla. One of them, either the inner or the outer one, is firmly attached and used for striking, and thus it is called the functional fang. If the functional fang drops off, the one on the other side can be used. The shed fang may fall out of the mouth or pass through the alimentary canal and appear in the feces. Behind each fang there is a series of reserve fangs in successive stages of development<sup>(9,10)</sup>.

Taiwan is located at the juncture of tropical and subtropical regions and has a warm, humid climate with abundant precipitation and food,

which coupled with the island's diverse vegetation and landscape, makes it a suitable environment for many snake species<sup>(11)</sup>. Twenty three of the 62 known species of snakes in Taiwan are venomous<sup>(12)</sup>. They include nine species of sea snakes and fourteen species of land snakes. Only six of the fourteen venomous land snakes are commonly encountered and cause significant morbidity and mortality. These six species can be divided further into subgroups according to the characteristic clinical features that they produce. *Trimeresurus stejnegeri* (Taiwan bamboo viper), *Trimeresurus mucrosquamatus* (Taiwan habu) and *Deinagkistrodon acutus* are classified under the hemotoxic group. *Vipera russelli formosensis* is considered to belong to the hemoneurotoxic group. The last two species, *Naja atra* and *Bungarus multicinctus* are considered to belong to the neurotoxic group<sup>(12,13)</sup>. The mortality rate from venomous snakebites in Taiwan was estimated to be 6.1% from 1904 to 1971. *Bungarus multicinctus* and *Deinagkistrodon acutus* caused the most mortality earlier in this period<sup>(13,14)</sup>. However, according to the 1986 to 1994 statistical records of the National Poison Control Center, the mortality rate from venomous snakebites has decreased to 2.4%, but the mortality rate from bites by *Bungarus multicinctus* remains high at 25%<sup>(14-15)</sup>.

### ***Trimeresurus stejnegeri* (Taiwan bamboo viper)**

*Trimeresurus stejnegeri*, it is also called the red tail bamboo viper because of its green body and red tail. Nontoxic green snakes have a green tail. The head is triangular with a pit between each eye and the nose containing blood vessels and the trigeminal nerve distribution. This acts as a temperature probe which can detect subtle ambient temperature changes which the snake uses when searching for prey such as small mammals. The mouth has a pair of solenoglyphic teeth, which leave obvious fang marks on the victim. The snake is about 50 cm long and its body color is common in tree snakes. It has a hemorrhagic toxin, and the mechanism of action remains unknown. The main toxic components affect bleeding (hemorrhagic factors HR1 and HR2), coagulation components (platelet aggregoserpentin), and anti-clotting components (platelet aggregation inhibitor, 5'-nucleotide enzyme), and show high concentrations of procoagulant effects (like the thrombin effect), low concentrations with hemolysis. The snake is found in southeastern mainland China and Taiwan. It tends to attack ferociously and the bite area can have swelling, bleeding, and blisters (Fig. 1-2). It is the most

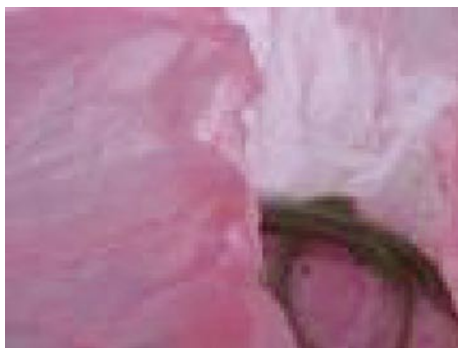

Fig. 1 The *Trimeresurus stejnegeri* bite in the patient in Fig. 2

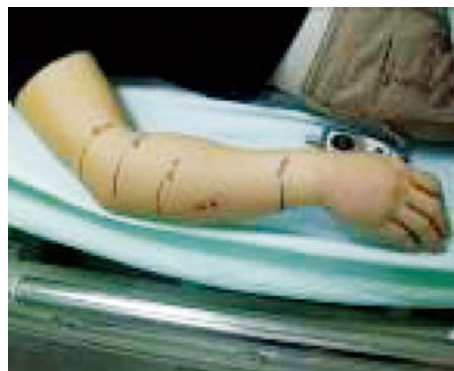

Fig. 2 Swelling of the forearm in a patient bitten by *Trimeresurus stejnegeri*

widely distributed snake in Taiwan and has the highest bite rate, but because its venom is less lethal than other snakes the death rate from its bite is low<sup>(16-18)</sup>.

### **Trimeresurus mucrosquamatus (Taiwan habu)**

*Trimeresurus mucrosquamatus* is a venomous pit viper species found from India (Assam) and Bangladesh, to Myanmar, China and Taiwan. The toxicity of its venom is not as high as the other 5 major venomous snakes in Taiwan<sup>(12)</sup>, but it has second highest rate of biting. *Trimeresurus mucrosquamatus* frequently bites patients on the lower limbs, and bites generally occur near houses and footpaths. The venom of *Trimeresurus mucrosquamatus* and *Trimeresurus stejnegeri* contain various components, including phospholipase A2 isoenzymes, prothrombin activation inhibitors, platelet aggregation inhibitors, and fibrinogenases, all of which have complex effects on blood coagulation and platelet aggregation<sup>(19-20)</sup>. *Trimeresurus mucrosquamatus* envenoming results in severe local manifestations (limb necrosis and compartment syndrome), which might be explained by the large amount of venom injected and the high magnitude of myotoxicity (Fig. 3-4).

The general clinical manifestations of *Trimeresurus mucrosquamatus* and *Trimeresurus*

*stejnegeri* envenoming in Taiwan are largely similar to those of other pit vipers in Southeast Asia<sup>(4)</sup>. Nevertheless, *Trimeresurus mucrosquamatus* envenoming causes more severe clinical manifestations than *Trimeresurus stejnegeri*, reflecting the differences in the amount, potency, and constituents of the venom in these two pit vipers. Because of the higher toxicity, patients with *Trimeresurus mucrosquamatus* envenoming are more likely to develop life-threatening complications and needed higher doses of antivenom and longer hospitalizations than patients bitten by *Trimeresurus stejnegeri*. Culprit snakes can be identified and documented by emergency physicians by either identifying the snake brought in by the patient and or having the patient identify a picture of the snake. The two species are easily distinguishable because of their markedly different color patterns and lengths. *Trimeresurus stejnegeri* averages about 70 cm (ranging from 50 to 90 cm) long, and is bright to dark green over the dorsal side and pale green to whitish on the ventral side. *Trimeresurus mucrosquamatus* is longer, with an average length of about 120 cm (ranging from 100 to 150 cm). It is grayish or olive brown on the dorsal side, with a pattern of shells of continuous large brown, black-edged patches, and a whitish belly heavily powdered with light brown. There are no other pit vipers with a similar appearance

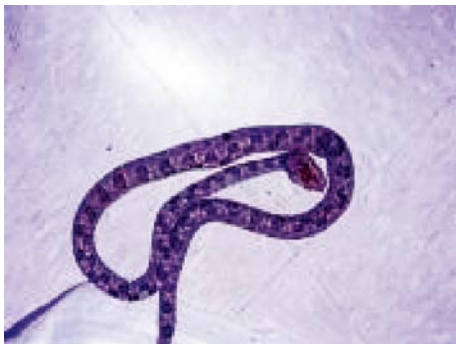

Fig. 3 The *Trimeresurus mucrosquamatus* which bit the patient in Fig 4

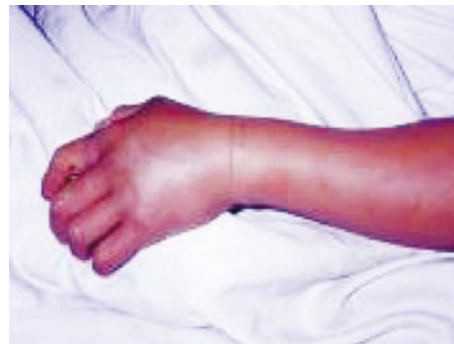

Fig. 4 Swelling of the forearm after a *Trimeresurus mucrosquamatus* bite

in Taiwan<sup>(21)</sup>. The Taiwan habu (*Trimeresurus mucrosquamatus*) and green habu (*Trimeresurus stejnegeri*) are responsible for most cases of envenoming among these 6 indigenous venomous snakes<sup>(11)</sup>. Clinically, however, in the absence of specific immunodiagnostic tests, it is still difficult to distinguish between envenoming by *Trimeresurus mucrosquamatus* and *Trimeresurus stejnegeri* because of the similarities of early local symptoms and signs. Thus, it is practical and safe to use bivalent antivenom that covers both *Trimeresurus mucrosquamatus* and *Trimeresurus stejnegeri*. An equine-derived bivalent F(ab')<sub>2</sub> fragment antivenom has been produced and marketed in Taiwan since 1980. Although *Trimeresurus mucrosquamatus* and *Trimeresurus stejnegeri* are currently classified into different genera, the bivalent antivenom remains the treatment of choice for envenoming by both pit vipers<sup>(21-22)</sup>.

### ***Deinagkistrodon acutus* (hundred pacer snake, sharp-nosed pit viper)**

*Deinagkistrodon acutus* is one of the most common venomous snakes in southern and eastern Taiwan. The venom of this snake has proteolytic and hemorrhagic effects. The manifestations of snakebite with hemorrhagic venom include local

or systemic hemorrhage, necrosis of the skin, muscle, and subcutaneous tissue, respiratory collapse and possible death. Maintaining stable life signs is the chief strategy of treatment<sup>(23)</sup>. This is a medium-sized snake that grows to a maximum length of 150 cm. The body is slightly thick with a triangular head and upturned rostrum. There are triangular black marks on both sides of the body, so it is easy to identify. Dangerous animals often have exaggerated reputations and this species is no exception. The popular name “hundred pacer” refers to a local belief that, after being bitten, the victim will only be able to walk 100 steps before dying. In some areas, it is even called the “fifty pacer.” This species is considered dangerous, and fatalities are not unusual. According to the US Armed Forces Pest Management Board, the venom is a potent hemotoxin that is strongly hemorrhagic. The toxic substances include ADPase, 5'-nucleotide, phospholipase A2 and fibrinogenase, with ADPase causing significant inhibition of platelet aggregation, resulting in a decrease in platelets and bleeding tendencies. Bite symptoms include severe local pain and bleeding that may begin almost immediately. This is followed by considerable swelling, blistering, necrosis, and (Fig. 5-6) ulceration. Systemic symptoms, which



Fig. 5 *Deinagkistrodon acutus*

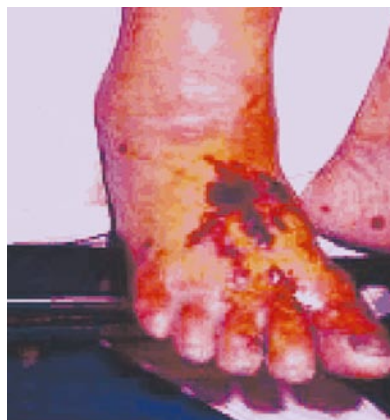

Fig. 6 Swelling of the dorsum of the foot with a blood blister in a patient bitten by *Deinagkistrodon acutus*

often include heart palpitations, may occur suddenly and relatively soon after the bite. Because of its body size and large hinged fangs, which permit effective delivery of large quantities of venom, victims bitten by this snake should be treated with antivenom and platelet preparations. The death rate has been greatly reduced<sup>(24-25)</sup>.

### **Bungarus multicinctus (Taiwan banded krait)**

*Bungarus multicinctus* is an elapid and its venom is classified as the neurotoxic type. It has a skin pattern of alternating black and white bands and a small, rounded, non-triangular head. Its distribution is mainly in Burma, southern China, and Taiwan<sup>(26)</sup>. The characteristic manifestations of envenomation by *Bungarus multicinctus* are due to bungarotoxin acting on neuromuscular junctions to inhibit transmission of nerve impulses and muscle contraction. There are two types of bungarotoxin, alpha and beta. Alpha-bungarotoxin competes with acetylcholine in the binding of neuromuscular junction receptors. Beta-bungarotoxin binds presynaptically and hinders the release of acetylcholine. After envenomation, victims may present with local numbness and varying degrees of

systemic muscle paralysis, e.g. ptosis (Fig. 7-11). When acting on respiratory muscles, it can cause cessation of spontaneous respiration, hypoxia, and death<sup>(27)</sup>. The Taiwan National Poison Control Center reports that the chief cause of deaths from snakebites during the past decade was respiratory failure, 80% of which was caused by *Bungarus multicinctus* bites. Previous reports have suggested that for immediate and delayed respiratory failure, prompt treatment of respiratory symptoms, such as with artificially assisted ventilation, results in eventual complete recovery of most patients, no matter how severe the symptoms. Therefore, active respiratory support is the most important part of treatment in cases of envenomation by *Bungarus multicinctus*. The mortality rate by *Bungarus multicinctus* bites is as high as 25% in Taiwan because patients often ignore wounds without significant swelling and pain and do not seek medical treatment. Therefore, patients with ptosis or chest tightness should be given antivenom as soon as possible and intubation with ventilator assistance should be considered to maintain breathing<sup>(26-27)</sup>.

### **Naja atra (Taiwan cobra)**

Cobra is the common name for members

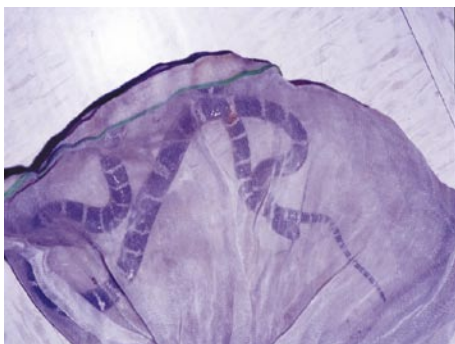

Fig. 7 A *Bungarus multicinctus* snake caught at the scene

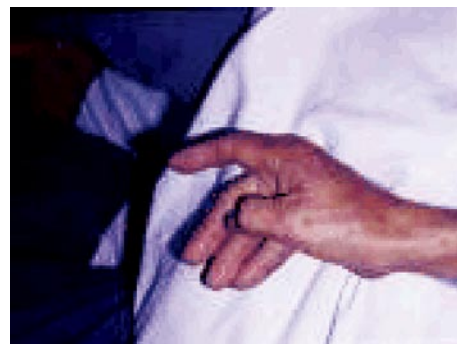

Fig. 8 No obvious symptoms are noted on this patient's right hand after a *Bungarus multicinctus* snakebite

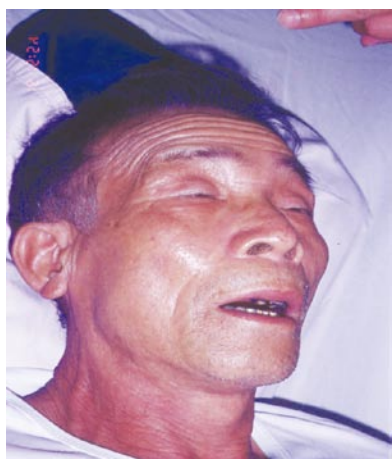

Fig. 9 Bilateral ptosis is noted on upward gaze after envenomation by *Bungarus multicinctus*

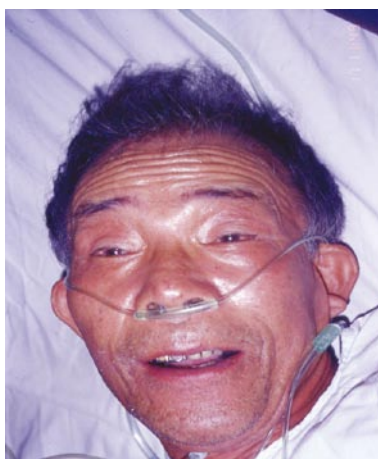

Fig. 10 This patient has received an endotracheal tube and ventilator treatment

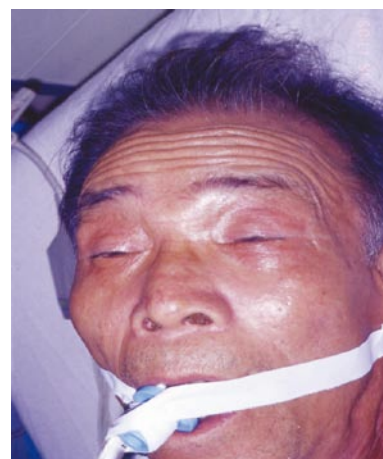

Fig. 11 Ptosis of the eyelids has disappeared after antivenom and ventilator treatment

of the elapidae family of venomous snakes, which are known for their intimidating looks and deadly bite. The hood of a cobra is created by the extension of the ribs behind its head. It is found in the Philippines, Malaysia, southern China, Burma, and the Malay Peninsula. This snake can spray its venom from a distance of about 2.4 meters (about 8 ft) accurately into the eyes of its victims, causing temporary blindness and great pain<sup>(4-5)</sup>. Venom coming in contact with human eyes causes an immediate and severe irritation of the conjunctiva and cornea that if untreated may cause corneal ulcerations, urethritis and permanent blindness. The venom of *Naja atra* is classified as neurotoxic and has neurotoxic, cardiotoxic and hemotoxic properties. The clinical features of a cobra bite vary depending on the species and the ratio of the various components of the venom. Envenomation of some species can cause profound neurological abnormalities. Philippine cobra venom is a neurotoxin which affects cardiac and respiratory function and can cause neurotoxicity and respiratory paralysis and death in thirty

minutes. The bite causes only minimal tissue damage. The venom of the African spitting cobra (*Naja nigricollis*) does not cause neurological signs, such as cranial nerve lesions and respiratory paralysis, expected following elapid poisoning. Almost all of these bites show local swelling, followed by local tissue necrosis. The venom of the Taiwan cobra (*Naja atra*), known to possess a relatively large percentage of cardiotoxin, causes local tissue swelling and necrosis. Bites by the Taiwan cobra produce a distinctive clinical picture characterized by prominent local effects with little neurotoxicity. The Poison Control Center reported 43 patients who had Taiwan cobra bites from 1996 to 1998, of which 94.4% had local swelling, 38.9% had necrosis or wound poor healing, and 19.4% had non-specific systemic symptoms. There were no deaths or typical signs of neurotoxicity<sup>(28)</sup>. The cause of local tissue necrosis can be attributed to a direct toxin effect and vascular thrombosis of the surrounding tissue. Soon after the bite, there is extreme pain, swelling and local tissue necrosis in the affected area. In addition to antivenin, skin

grafting or measures to fill the flap are often required (Fig. 12-15). The venom of the eastern Taiwan cobra is twice as toxic as that of the western Taiwan cobra, so a double dose of antivenom is needed<sup>(29-31)</sup>.

Snakes bites are generally found on the sole of the foot and also, in rare cases, on the tongue. There is a case report of a death from a snakebite on the tongue in Russia in 1971<sup>(32)</sup>. Gerkin et al. described another case of a rattlesnake bite on the tongue which resulted in life-threatening obstruction of the upper airway secondary to massive edema of the tongue, and other soft tissue structures quickly following envenomation. Therefore, poisonous snakebites are medical emergencies, and can be deadly if not treated quickly<sup>(33)</sup>. Pradhan et al reported two cases in which snake venom intoxication by a cobra bite on

the tongue was a habit associated with addiction to heroin, cannabis and mandrax<sup>(34)</sup>. We reported a snake charmer with an unusual presentation of a Taiwan cobra (*Naja atra*) snakebite with significant local tissue injury and necrosis of the tongue. The patient received polyvalent snake antivenom almost 1 hour after the bite. The patient had no respiratory insufficiency, neurotoxicity, or renal failure. Tongue damage rapidly resolved after early and aggressive antivenom treatment. The tongue remained well perfused and viable, and tongue mobility was good. The tongue possesses a rich blood supply that provides resistance to necrosis, allows lacerations to heal quickly, and offers these patients the potential for tongue preservation. Tongue snakebite damage rapidly responds to polyvalent snake antivenom, so the sequelae of tongue amputation and loss of ability to speak can



Fig. 12 The *Naja atra* bite in the patient in Fig. 13

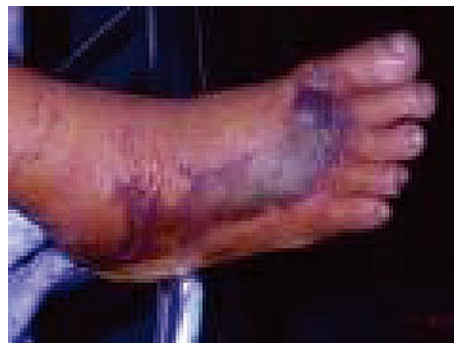

Fig. 13 Swelling of the dorsum of the foot after a *Naja atra* bite

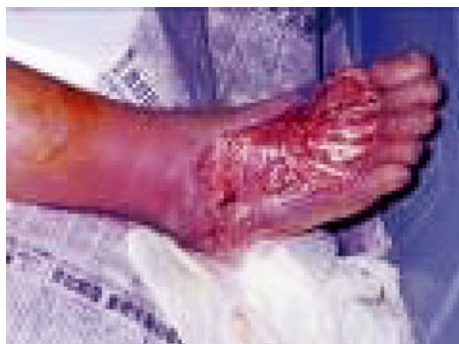

Fig. 14 Surgical debridement to remove necrotic tissue on the foot

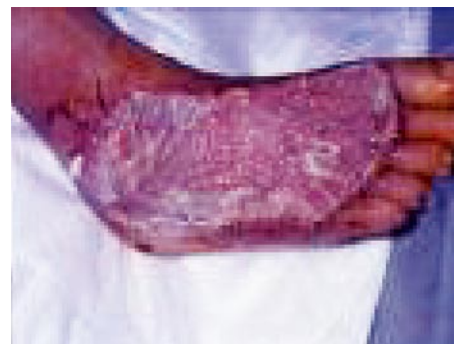

Fig. 15 Split-thickness skin grafting



be avoided<sup>(35)</sup> (Fig. 16-20).

### ***Vipera russelli formosensis* (Russell's pit viper, chain snake)**

Russell's viper is widely but irregularly distributed throughout South and East Asia, including Taiwan. *Vipera russelli formosensis* is relatively rare and is restricted to southeastern Taiwan. About 0.4% of snakebites in Taiwan are attributed to it, making it the sixth most frequent type of snakebite on the island<sup>(13,36-37)</sup>. Despite its distinct appearance, this snake is frequently mistaken for *Trimeresurus mucrosquamatus* (Formosan habu), a common, widely dispersed snake in Taiwan, because of its dark-brown patches.

The venom of *Vipera russelli formosensis* contains several toxic components, including two major procoagulant factors, factor V and X activators, protease inhibitor, hemorrhagins, phospholipase A2 and several other enzymes<sup>(38-42)</sup>. The clinical effects caused by *Vipera russelli formosensis* venom, such as coagulopathy, hemolysis, renal failure, a generalized increase in capillary permeability, rhabdomyolysis and neurotoxicity, vary with the different subspecies<sup>(43)</sup>. The clinical manifestations following *Vipera russelli formosensis* bites vary from local symptoms to extensive systemic reactions. Local symptoms include pain and swelling at the site. In severe poisoning, the swelling can even extend to the

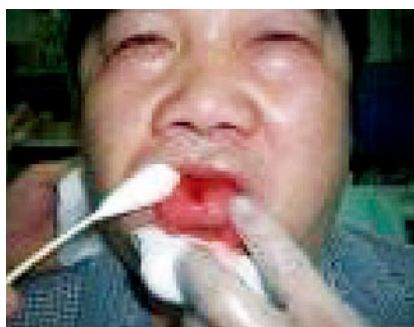

Fig. 16 Bloody fluid exuding from fang punctures on the dorsum of the tongue

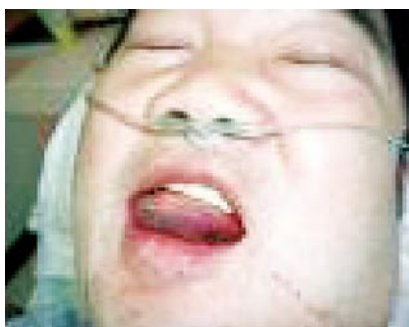

Fig. 17 Swelling, ecchymosis and myonecrosis of the tongue base 2 hours later

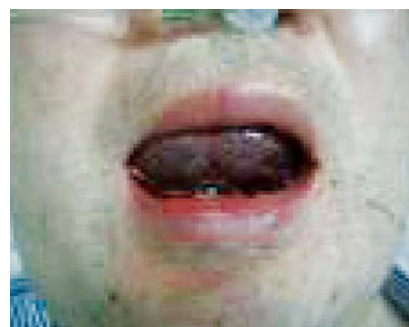


Fig. 18 Swelling, ecchymosis and myonecrosis of the whole tongue 2 hours later. Tongue excision is being considered

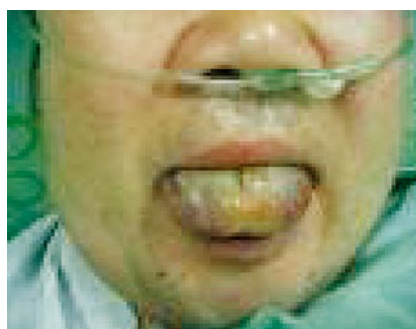

Fig. 19 Blood flow to the tongue tip has been restored 4 hours later

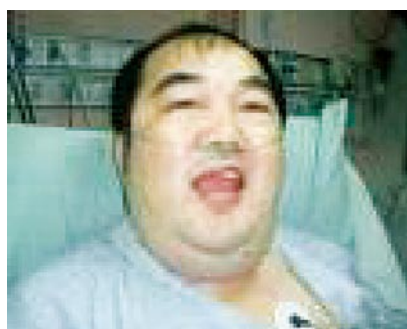

Fig. 20 Good viability, mobility and blood supply in the tongue 2 days later after quick antivenom treatment

whole limb. A major effect of systemic viper poisoning is hemorrhage, which occurs in about 65% of patients<sup>(44)</sup>. Blood can ooze from the bite and a variety of other sites as well. Subsequently, hematemesis, melena, hemoptysis, hematuria, and shock resulting from excessive bleeding may be observed (Fig. 21-22). Most remarkably, *Vipera russelli formosensis* bites can result in coexisting bleeding and coagulation defects. *Vipera russelli formosensis* venom selectively activates Factor X promoting coagulation. However, it also prevents stabilization of fibrin and stimulates the plasminogen system. The coagulation defects can persist for two weeks or longer, although hemorrhage usually resolves within a week<sup>(45)</sup>. Renal abnormalities such as anuria or oliguria may also develop after a *Vipera russelli formosensis* bite and usually occur within a few hours or as late as 96 hours<sup>(46-49)</sup>. The pathological changes are predominantly in the tubulointerstitium, and acute tubular necrosis occurs in 70% to 80% of patients<sup>(44)</sup>. The renal pathology, and clinical and experimental observations give clues to the cause of acute renal failure. The implicated factors include bleeding, hypotension, intravascular hemolysis, myoglobinuria, disseminated intravascular coagulation, nephrotoxicity from the

venom, sepsis, and hypersensitivity to venomous or antivenomous protein. The therapy used for acute renal failure after snakebite is the same as for acute renal failure from any other cause. It consists of adequate hydration, avoidance of nephrotoxic agents, correction of electrolyte imbalances and acid/base abnormalities and dialysis. Several other abnormalities must be corrected as well, including bleeding, coagulation defects, shock and sepsis. Mandatory platelet and plasma transfusions, antibiotics, and colloid or crystalloid fluid infusions have to be justified. Early administration of antivenin is a vital therapeutic measure. Polyvalent antivenin for *Trimeresurus mucrosquamatus* and *Trimeresurus stejnegeri* are not effective. Therefore, it is important to identify the snake, so the appropriate antivenin for *Vipera russelli formosensis* is employed. To prevent further cases of acute respiratory failure after a *Vipera russelli formosensis* bite, timely administration of appropriate antivenin is required<sup>(45,50-53)</sup>.

## Treatment

Any snake bite in Taiwan should be treated very seriously. Although there are more non-venomous than venomous snakes, some of the



Fig. 21 *Vipera russelli formosensis*

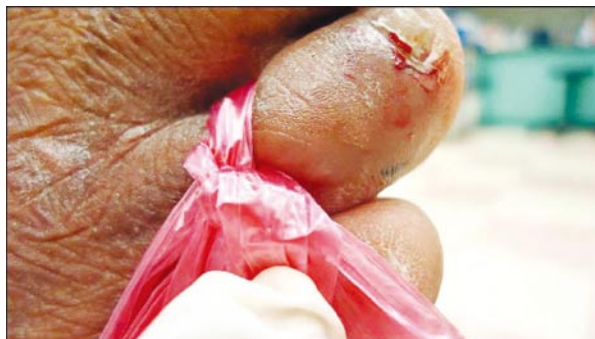

Fig. 22 A *Vipera russelli formosensis* bite on a right toe of a middle-aged man, who died after immediate antivenom treatment (photograph provided by Hengchun Hospital)

venomous ones can, in severe cases, be deadly. Medical management of snake bites includes first aid, emergency care, antivenom therapy and monitoring for possible complication. Attempts to identify the snake by appearance, color and characteristics should be made. The patient should rest as soon as possible, and keep calm and warm. Physical activity should be minimal. The affected extremity should be immobilized and placed in a functional position below the level of the heart with a compressive dressing and splint. Although recommended in the past, first-aid measures such as tourniquets, incisions and suction, cryotherapy(ice water immersion), and electric shock therapy are strongly discouraged. Any suspected snakebites should prompt the initiation of first aid, investigation and observation. The first priority is maintaining vital signs and advanced life support. If a snakebite is confirmed or highly suspected, the next step is to differentiate a dry bite from envenomation. Patients with dry bites or no envenomation should be observed for at least 6-12 hours. Prompt antivenom therapy, aggressive supportive resuscitation and treatment of complications greatly reduce mortality of snakebites<sup>(1)</sup>.

The wound should be cleansed with soap and water, and the patient should have a tetanus immunization. Wound culture and antibiotic therapy should be initiated only if signs of infection are present. If there is no necrosis, prophylactic antibiotics are not indicated in the routine treatment of patients with snakebites from non-venomous or venomous snakes<sup>(54-55)</sup>.

Antivenom is the mainstay of therapy for poisonous snakebites. In the 1980's, the fragment antigen-binding (Fab) type of antivenom was produced using a pepsin digestion approach at the Centers for Disease Control in Taiwan, and made universally available to primary and secondary hospitals<sup>(56)</sup>. Therefore, most envenomated patients

could be promptly treated within a few hours of being bitten. The first snakebite poison consultation center in Taiwan was established at Taipei Veterans General Hospital in 1986 to provide clinical physicians with round-the-clock consultation on how to correctly diagnose snakebites and treat them with the appropriate antivenom. The establishment of this center has greatly improved the propagation of knowledge on snakebite treatment, and has resulted in favorable outcomes after poisonous snakebites in Taiwan<sup>(57)</sup>.

Envenomation grading is helpful in determining the need for antivenom. Progression of signs and symptoms indicates a need for antivenom therapy even several days after a snakebite. Antivenom is most effective if given within 4 hours, and is less effective after more than 8 hours. Nevertheless, in severe envenomation, antivenom should be considered even after 3-4 days. Intramuscular and digital injections should not be used. Observation for progression of edema and systemic signs should be continued during and after antivenom infusion. The limb circumference should be measured at several sites above and below the bite. Antivenoms are prepared by immunizing horses after snake envenomation. Each vial of antivenom contains over 1,000 Tanaka units (mean, 1200). Each unit can neutralize one minimum lethal dose of 12 to 14 g of mouse body weight<sup>(6)</sup>. A skin test dose of 0.1 mL of a 1:100 solution is intradermally injected in the forearm of the patient. Epinephrine should be available prior to the test dose injection. Patients are given diphenhydramine and corticosteroids if there is evidence of an allergic reaction. Before administration, the antivenom is diluted in 300 to 500 mL of normal saline and infused over 30 to 60 minutes.

There are four types of antivenom available currently in Taiwan.

1. Polyvalent hematropic antivenom for *Trimeresurus mucrosquamatus* and *Trimeresurus*

stejnegeri.

2. Polyvalent neurotoxic antivenom for *Bungarus multicinctus* and *Naja atra*.
3. Monovalent antivenom for *Deinagkistrodon acutus*.
4. Monovalent antivenom for *Vipera russelli formosensis*.

Most toxicologists use the same dosage for adults and children. Because the mechanism of Fab antivenom neutralization of venom is based primarily on the principles of stoichiometry, the effective dose for an adult or child is directly determined by the molar dose of venom protein, not a mg/kg dose<sup>(58-60)</sup>. In general, 6-12 vials of antivenom against neurotoxic venom are used for *Naja atra* bites and two vials for *Bungarus multicinctus*. One vial of antivenom against hemotoxic venom is used for both *Trimeresurus stejnegeri* and *Trimeresurus mucrosquamatus* bites. Two vials of anti-*Deinagkistrodon acutus* are used for *Deinagkistrodon acutus* and 2-4 vials of anti-*Vipera russelli formosensis* are used for *Vipera russelli formosensis* bites<sup>(61-63)</sup>. During the infusion, the blood pressure, level of consciousness and skin reaction should be monitored. The varied clinical manifestations of snake bites should be considered for effective management. The ready availability and appropriate use of antivenin, close monitoring of patients and the institution of ventilatory support all help reduce mortality.

## References

1. Ong JR, Ma HP, Wang TL. Snake bites. *Ann Disaster Med* 2004;2:S80-S88.
2. Chang KP, Lai CS, Lin SD. Management of poisonous snake bites in southern Taiwan. *Kaohsiung Journal of Medical* 2007;23:511-8.
3. Chippaux JP. Snake-bites: appraisal of the global situation. *Bull World Health Organ* 1998;76:515-24.
4. Warrell DA. WHO/SEARO Guidelines for the clinical management of snakebite in the Southeast Asian Region. *SE Asian J Trop Med Pub Hlth* 1999;30:1-85.
5. Mao SH. Common Terrestrial Venomous Snakes of Taiwan. Special Publication Number 5, National Museum of Natural Science 1993.
6. Loveridge A. Field notes on vertebrates collected by the Smithsonian-Chrysler East African expedition of 1926. *Proc US Natl Mus* 1928;73:731-69.
7. Bogert CM. Dentitional phenomena in cobras and other elapids with notes on adaptive modifications of fangs. *Bull Amer Mus Nat Hist* 1943;81:285-360.
8. Bellairs A. The life of reptiles, New York, Universe Books 1970.
9. Mao SH. Bite patterns of Taiwan venomous and non-venomous snakes. Part I. *Bull. Ins. Zool. Academia Sinica* 1966;5:7-22.
10. Mao SH. Bite patterns of Taiwan venomous and non-venomous snakes. Part II. *Bull. Ins. Zool. Academia Sinica* 1967;6:17-27.
11. Hung DZ. Taiwan's venomous snakebite: epidemiological, evolution and geographic differences. *Transactions of the Royal Society of Tropical Medicine and Hygiene* 2004;98:96-101.
12. 毛壽先，殷鳳儀。台灣常見陸地毒蛇簡介。台灣省立博物館 1990。
13. Sawai Y. Snakebites on Taiwan. *The Snake* 1969;1:9-18.
14. 洪東榮。台灣常見的毒蛇及咬傷之治療。毒藥物季刊，行政院衛生署臨床毒藥物諮詢中心 1996。
15. Miao BL, Huang RJ, Hu MS, et al. Venomous snakebite in Taiwan (1988-1991). *Chinese Journal of Public Health (Taipei)* 1995;4:455-60.
16. Liao WB, Lee CW, Tsai YS, et al. Influential factors affecting prognosis of snakebite

- patients' management: Kaohsiung Chang Gung Memorial Hospital experience. *Chang Gung Medical Journal* 2000;23:577-83.
17. Ovadia M. Isolation and characterization of three hemorrhagic factors from the venom of *Vipera palaestinae*. *Toxicon* 1978;16:479-87.
  18. Tsai IH, Wang YM, Chen YH, Tsai TS, Tu MC. Venom phospholipase A2 of bamboo viper (*Trimeresurus stejnegeri*): molecular characterization, geographic variations and evidence of multiple ancestries. *Biochemical Journal* 2004;377:215-23.
  19. Ouyang C, Teng CM. Fibrinolytic enzymes of *Trimeresurus mucrosquamatus* venom. *Biochimica et Biophysica Acta* 1976;420:298-308.
  20. Ouyang C, Teng CM. The action mechanism of the purified platelet aggregation principle of *Trimeresurus mucrosquamatus* venom. *Thrombosis and Haemostasis* 1979;41:475-90.
  21. Chen YW, Chen MH, Chen YC, et al. Differences in clinical profiles of patients with *Protobothrops mucrosquamatus* and *Viridovipera stejnegeri* envenoming in Taiwan. *Am J Trop Med Hyg* 2009;80:28-32.
  22. Huang RJ, Liao MY, Chen SW, Chen CK. Preparation of highly potent hemorrhagic antivenin. *Chin Med J* 1986;37:410-5.
  23. Chen CC, Yang CM, Hu FR, Lee YC. Penetrating ocular injury caused by venomous snakebite. *Am J Ophthalmol* 2005;140:544-6.
  24. Ouyang C, Huang TF. Platelet aggregation inhibitors from *Agkistrodon acutus* snake venom. *Toxicon* 1986;24:1099-106.
  25. Chen RH, Chen YC. Isolation of an acidic phospholipase A2 from the venom of *Agkistrodon acutus* (five pace snake) and its effect on platelet aggregation. *Toxicon* 1989;27:675-82.
  26. Juan CW, Wu FS, Chang WH, Lee CN, Chou CC. A case of envenomation by *Bungarus multicinctus*. *J Emerg Crit Care Med* 1999;10:109-13.
  27. Hung DZ, Wu TC, Deng JF. The painful experience of inappropriate therapy of snake bites: a report of two cases. *Chin Med J (Taipei)* 1997;60:326-30.
  28. Gian-Kaw L, Ming-Ling W, Jou-Fang D, et al. Taiwan cobra (*Naja atra*) injury, cases analysis of Poison Control Center. *J Emerg Med (ROC)* 2000;2:46-58.
  29. Lee CY. Elapid Neurotoxins and their mode of action. *Clinical Toxicology* 1970;3:457-72.
  30. Lai MK, Wen CY, Lee CY. Local lesions caused by cardiotoxin isolated from Formosan cobra venom. *J Formos Med Assoc* 1972;71:328-32.
  31. Hung DZ, Liao MY, Lin-Shiau SY. The clinical significance of venom detection in patients of cobra snakebite. *Toxicon* 2003;41:409-15.
  32. Shaglydzhov K, Pepchuk TA. Death from a snake bite on the tongue. *Sud Med Ekspert* 1971;14:55-6.
  33. Gerkin R, Sergeant K, Curry SC, et al. Life-threatening airway obstruction from rattlesnake bite to the tongue. *Ann Emerg Med* 1987;16:813-6.
  34. Pradhan PV, Shah LP, Ghodke PR, Nayak PR. Snake venom habituation in heroin (brown sugar) addiction: (report of two cases). *J Postgrad Med* 1990;36:233.
  35. Kao TL, Juan CW. Tongue viability after snakebite-an unusual occupational hazard. *Am J Emerg Med* 2007;25:1083.e5-7.
  36. Sawai Y, Koba K, Okonogi T, Mishima S, Kawamura Y. An epidemiological study of snakebites in the Southeast Asia. *Jpn J Exp Med* 1972;42:283-307.
  37. Kuo TP, Wu CS. Clinico-pathological studies on Snakebites in Taiwan. *J Formos Med Assoc* 1972;71:447-66.
  38. Schiffman S, Threodor I, Rapaport S.

- Separation from Russell's viper venom of one fraction reacting with factor X and another reacting with factor V. *Biochemistry* 1969;8:1397-405.
39. Lindquist PA, Fujikawa K, Davie EW. Activation of bovine factor IX (christmas factor) by factor XIa (activated plasma thromboplastin antecedent) and a protease from Russell's viper venom. *J Biol Chem* 1978;253:1902-9.
  40. Chakraborty D, Bhattacharyya D, Sarkar S, Lahiri SC. Purification and partial characterization of hemorrhagin (VRH-1) from *Vipera russelli* venom. *Toxicon* 1993;31:1601-14.
  41. Huang HC, Lee CY. Isolation and pharmacological properties of phospholipase A2 from *Vipera russelli* (Russell's viper) snake venom. *Toxicon* 1984;22:207-17.
  42. Kasturi S, Gowda TV. Purification and characterization of a major phospholipase A2 from Russell's viper (*Vipera russelli*) venom. *Toxicon* 1989;27:229-37.
  43. Myint-Lwin, Warrell DA, Phillips RE, Tin-Nu-Swe, Tun-Pe, Maung-Maung-Lay. Bites by Russell's viper (*Vipera russelli siamensis*) in Burma: haemostatic, vascular and renal disturbance and response to treatment. *Lancet* 1985;ii:1259-64.
  44. Chugh KS. Snakebite-induced acute renal failure in India. *Kidney Int* 1989;35:891-907.
  45. Chen JB, Leung J, Hsu KT. Acute Renal Failure after Snakebite: A Report of Four Cases. *Chin Med J (Taipei)* 1997;59:65-9.
  46. Chugh KS, Pal Y, Chakravarty RN, Datta BN, Mehta R, Sakhuja V, Mandal AK, Sommers SCI. Acute renal failure following poisonous snake bite. *Am J Kidney Dis* 1984;4:30-8.
  47. Chugh KS, Alkat BK, Sharma BK, Dash SC, Mathew T, Das KC. Acute renal failure following snake bite. *Am J Trop Med Hyg* 1975;24:692-97.
  48. Dasilva OA, Lopez M, Godoy P. Intensive care unit treatment of acute renal failure following snake bite. *Am J Trop Med Hyg* 1979;28:401-7.
  49. Sitprija V, Benyajati C, Boonpucknavig PV. Further observations of renal insufficiency in snake bite. *Nephron* 1974;13:396-403.
  50. Hung DZ, Wu ML, Deng JF, Lin-Shiau SY. Russell's viper snakebite in Taiwan: Differences form other Asian countries. *Toxicon* 2002;40:1291-8.
  51. Chou TS, Lin TJ, Kuo MC, Mee-Sun T, Hung DZ, Tsai JL. Eight cases of acute renal failure from *Vipera russelli formosensis* venom after administration of antivenom. *Veterinary and Human Toxicology* 2002;44:278-82.
  52. Hung DZ, Yu YJ, Hsu CL, Lin TJ. Antivenom treatment and renal dysfunction in Russell's viper snakebite in Taiwan: a case series. *Transactions of the Royal Society of Tropical Medicine and Hygiene* 2006;100:489-94.
  53. Hung DZ, Wu ML, Peng JF, Yang DY, Lin-Shiau SY. Multiple thrombotic occlusions of vessels after Russell's Viper Envenoming. *Pharmacology Toxicology* 2002;91:106-10.
  54. Polly Terry. Antibiotics in non-venomous snakebite. *BMJ* 2002;19:142.
  55. Polly Terry. The use of antibiotics in venomous snakebite. *BMJ* 2002;19:48-9.
  56. Liau MY, Huang RJ. Toxoids and antivenoms of venomous snakes in Taiwan. *J Toxicol* 1997;16:163-75.
  57. Wang JD, Tsan YT, Mao YC, Wang LM. Venomous snakebites and antivenom treatment according to a protocol for pediatric patients in Taiwan. *J Venom Anim Toxins incl Trop Dis* 2009;15:668.
  58. Lopoo JB, Bealer JF, Mantor PC, Tuggle DW. Treating the snakebitten child in North America: a study of pit bites. *J Pediatr Surg* 1998;33:1593-5.

59. Parrish HM, Goldner JC, Silberg SL. Comparison between snakebites in children and adults. *Pediatrics* 1965;36:251-6.
60. Weber RA, White RR. Crotalidae envenomation in children. *Annals of Plastic Surgery* 1993;31:142-5.
61. Chang KP, Lai CS, Lin SD. Management of poisonous snake bites in southern Taiwan. *Kaohsiung Journal of Medical* 2007;23:511-8.
62. Chen CF, Lin TJ, Hsu WC, Yang HW. Appropriate antivenom doses for six types of envenomations caused by snakes in Taiwan. *J Venom Anim Toxins incl Trop Dis* 2009;15:479-90.
63. Yu CM, Huang WC, Tung KY, Hsiao HT, Ou SY. Prognostic factors of local necrosis due to poisonous snakebite-a clinical review in Mackay Memorial Hospital. *The Journal of Plastic Surgical Association R.O.C.* 2005;14:31-40.

# 台灣毒蛇咬傷經驗

阮祺文

台灣有6種毒蛇咬傷較為常見且有流行病學上的意義。赤尾鯪、龜殼花及百步蛇咬傷主要以出血症狀為主，一般稱之出血性毒蛇。眼鏡蛇和雨傘節咬傷因其具神經毒性，故稱之為神經性毒蛇。鎖鍊蛇兼具神經及出血症狀歸為兩者兼有之毒蛇。出血性毒毒素可造成全身性出血症狀；嚴重時並可導致全身擴散性血管內凝血病變。神經性毒毒素可以作用於運動神經與肌肉接合處，造成複視、構音及吞嚥困難、肌肉無力，甚至導致呼吸麻痺。混合性毒毒素具有神經毒性、溶血、橫紋肌溶解及腎毒性等症狀。赤尾鯪的咬傷是台灣最常見的毒蛇咬傷，百步蛇咬傷個案在六大毒蛇中反而最少。毒蛇咬傷後有臨床症狀出現，此時應儘速給予正確的抗蛇毒血清，雨傘節咬傷尚需考慮插管使用呼吸器維持呼吸，若毒蛇咬傷後未出現症狀，則最好觀察6-12小時確定無症狀再離院。抗蛇毒血清使用的劑量依咬傷的嚴重度、病人體重及咬傷後的時間長短給予不同的劑量，根據大多數毒物專家建議大人與小孩毒蛇咬傷應給予相同劑量，飯匙倩咬傷為6-12瓶、雨傘節咬傷為2瓶、龜殼花咬傷為1瓶、赤尾鯪咬傷為1瓶、百步蛇咬傷為2瓶、鎖鍊蛇咬傷為2-4瓶。急診醫護人員應根據毒蛇咬傷的病史，臨床進展的症狀及實驗室的檢查報告來決定適時給予何種抗蛇毒血清的注射量，滴注期間應密切注意病患各種生理現象的變化，才能降低毒蛇咬傷的死亡率。

關鍵詞：毒蛇咬傷，抗蛇毒血清，出血性毒毒素，神經性毒毒素

---

收件：101年9月1日 接受刊載：101年9月29日

<sup>1</sup>光田醫療社團法人光田綜合醫院急診醫學部 <sup>2</sup>弘光科技大學護理系

通訊及抽印本索取：阮祺文醫師 光田醫療社團法人光田綜合醫院急診醫學部

台中市沙鹿區沙田路117號

電話：(04)26625111轉2001 傳真：(04)26655050

E-mail: juanchiwen@yahoo.com.tw