

Blowout Fracture

WHAT IS A “BLOWOUT” FRACTURE?

A blowout fracture is a break of one or more of the 7 bones that surround the eye. Like a box, these bones make up walls that protect the eye. [see figure 1] The bottom of the box (orbital floor) and the inner wall closer to the nose have the thinnest and most easily broken bones.

When an object strikes the eye, force is transmitted into the eye compartment or socket (called the orbit), and the thinnest bones will buckle or break from the pressure generated by the force of the trauma. This is referred to as a “blowout” fracture. The release of this force may protect the eye from more serious injury.

Due to more stretchiness in their bones, children are at risk for a special type of orbital fracture called a “trapdoor” or “white-eye fracture”. In this type of fracture, a flap of bone is created by the trauma. Increased pressure then pushes soft tissue like muscle through the opening and then the flap of bone snaps closed. Tissue caught in the fracture instantly loses its blood supply and severely limits movement of the eye, resulting in nausea and vomiting.

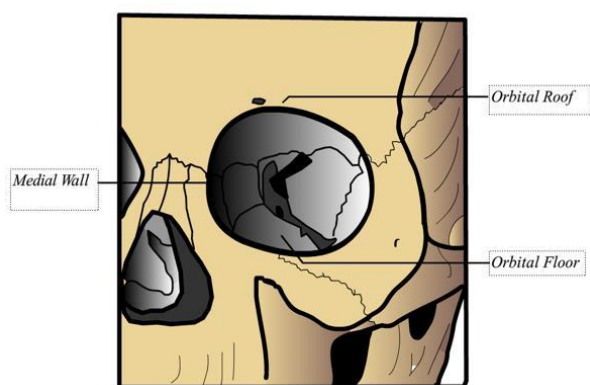


Figure 1. Bones of the orbit which form the roof, inside (medial) wall, outside (lateral) wall and floor.

Following a fracture, the muscles, fat and connective tissue can be bruised and displaced. If enough tissue is lost from the orbit, the eye sinks back into the orbit (enophthalmos) causing problems with both appearance of the eye and how well the eye works. If the eye muscles are injured by the fracture, there can be a change in the movement of the eye with possible double vision.

WHAT CAUSES A BLOWOUT FRACTURE?

Blowout fractures can happen with falls, sports-related high velocity ball impacts, violence from fists and elbows, and traffic accidents. Direct trauma may break the edge of the bone resulting in a noticeable lump or curve in the edge of the bone, but more commonly the force is transmitted as increased pressure in the orbit.

Fractures are much more common in boys than in girls. Protective glasses can reduce the chance of serious eye injury in sports with fast moving objects and should be encouraged.

WHAT ARE THE SYMPTOMS OF AN ORBITAL BLOWOUT FRACTURE?

The most common symptoms are bruising, tenderness and swelling around the eye; redness of the eye; double vision, (seeing two images); numbness of the cheek, nose or teeth. Signs of an orbital fracture include disruption of the smooth edge of the orbital floor rim, reduced movement of the eye (especially upward and downward movements), and air under the skin around the eye. [See figure 2].

Symptoms that typically indicate a “trapdoor fracture” (see above for explanation) are pain on eye movement, nausea or vomiting, and double vision. Nausea and vomiting can predict a trapdoor fracture in 75% of cases. These fractures may show little or no redness of the eye.

In cases of any orbital fracture, an eye exam with an ophthalmologist is very important.

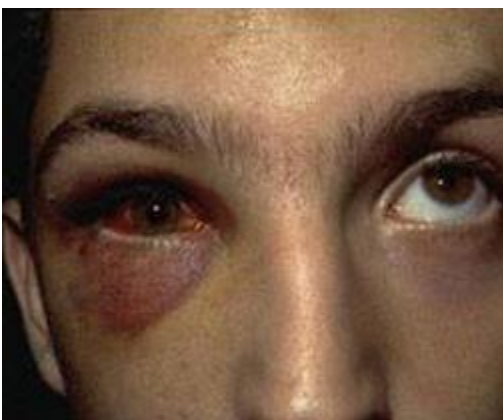

Fig. 2: Bruising around the eye is a common symptom of a blowout fracture. Notice also that the right eye does not seem to move upward like the left eye.

HOW DO YOU KNOW IF THERE IS A FRACTURE?

Thin cut computed tomography (CT) scans of the orbit are used to help make the diagnosis [See figure 3]. In cases where radiation exposure is a major concern, magnetic resonance imaging (MRI) may be used.

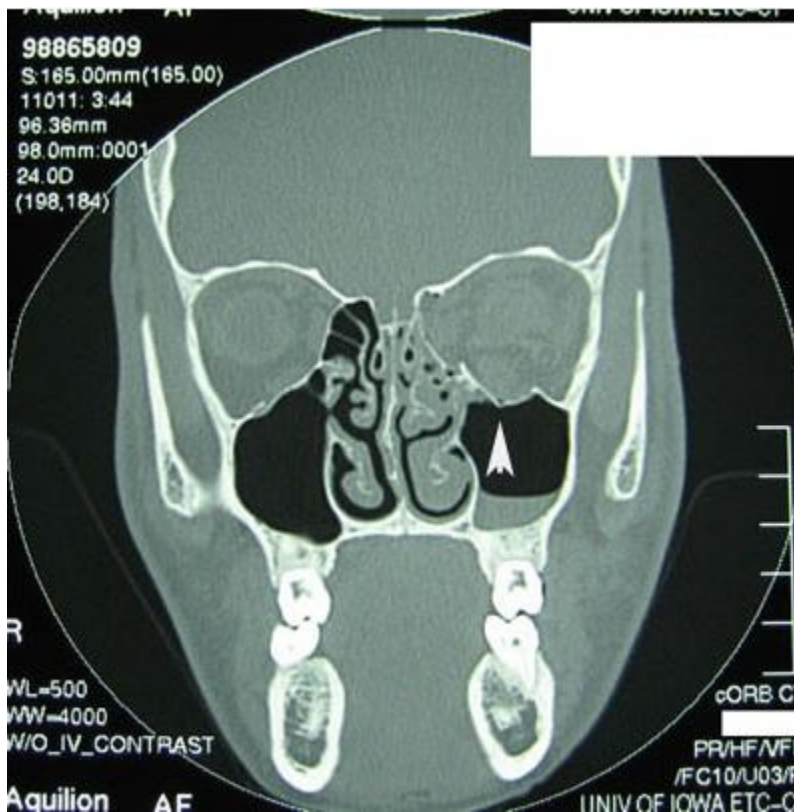


Fig. 3: Computed tomography (CT) Scan with a fracture shown by the arrowhead.

ARE THERE DIFFERENT TYPES OF BLOWOUT FRACTURES?

Blowout fractures come in different forms including:

- size (big or small)
- location (front or back)
- bone in place or displaced



- tissue/muscle entrapped in fracture, “trapdoor fracture”
- accompanying symptoms (double vision, pain, eye position)

A “simple” fracture is one with minimal or no double vision and minimal or no sunken in appearance (enophthalmos) once healed from injury.

WHAT CAN BE DONE FOR A SIMPLE BLOWOUT FRACTURE?

Most simple blowout fractures do not require surgical repair and do not cause lasting problems.

Early treatment consists of:

- ice to decrease swelling
- decongestants to aid in the drainage of blood and fluid accumulating in the sinuses
- avoidance of nose blowing to prevent pressure from pushing the sinus contents into the orbit
- oral steroids in some cases to decrease swelling and scarring
- oral antibiotics may be needed if sinus infection is present

WHEN SHOULD SURGICAL REPAIR OF BLOWOUT FRACTURES BE CONSIDERED?

Trapdoor fractures need to be repaired to release the trapped tissue, usually within 24-48 hours for best outcomes. In all other fracture types, observation may be best, as double vision tends to improve over several weeks. Fractures with persistent symptoms (typically double vision or enophthalmos) may be good candidates for surgical repair depending on the type and severity of the symptoms. Timing of the repair varies, but most often is within a few weeks to months of the injury. Initial repair may consist of any of the following:

- exploration of fracture site and repositioning of bone
- release of trapped tissue from fracture site
- covering of fracture site with synthetic material

WHAT LONG-TERM PROBLEMS MAY DEVELOP FOLLOWING BLOWOUT FRACTURES?



Most fractures heal without long-term effects. However, strabismus surgery (eye muscle surgery) is sometimes necessary for persistent double vision. Surgery may also be necessary for the sunken appearance of blow out fractures due to loss of orbital fat and increased volume of the orbit. Swelling of the extraocular muscles on CT scan can sometimes predict the chance of double vision. Occasionally, persistent double vision can be treated with other non-surgical methods like prism glasses or botulinum toxin injections.

Updated 03/2023