

Transplantation in Identical Twins: Another Option for Breast Reconstruction

Robert J. Allen, Jr., M.D.
 Maria M. LoTempio, M.D.
 James E. Craigie, M.D.
 Robert J. Allen, Sr., M.D.

Charleston, S.C.; New Orleans, La.;
 and New York, N.Y.

Background: Deriving their name from the Greek word *plastikos*, meaning related to molding, plastic surgeons have made their reputation by transplanting tissues from one area of the body to another to “remold” defects caused by trauma, congenital anomaly, or disease. Dr. Joseph Murray, a plastic surgeon, performed the first successful kidney transplant between identical twins in 1954. The authors present three cases involving the transplantation of perforator flaps from one identical twin to another for breast reconstruction, including cases using both deep inferior epigastric perforator and superficial inferior epigastric artery flaps.

Methods: Three sets of recipient monozygotic twins that had breasts treated with mastectomies underwent reconstruction using transplanted tissue from their donor monozygotic twins. All sets of twins underwent DNA testing to determine that they were monozygotic; therefore, no immunosuppressive therapy was indicated.

Results: The three sets of recipient monozygotic twins underwent successful breast reconstruction using perforator flap transplants from their donor monozygotic twins. The operations included two unilateral reconstructions (one using a deep inferior epigastric perforator flap and the other using a superficial inferior epigastric artery flap) and one bilateral deep inferior epigastric perforator reconstruction. Their hospital courses were unremarkable.

Conclusions: Transplant surgery continues to evolve in the twenty-first century. The authors present three cases of breast reconstruction using skin flap transplantation as a new option for breast reconstruction. (*Plast. Reconstr. Surg.* 122: 1019, 2008.)

The first successful kidney transplant was performed by a plastic surgeon, Dr. Joseph Murray, on December 23, 1954. The patient was a 24-year-old man with chronic glomerulonephritis who agreed to undergo a kidney transplant with the donor kidney from his identical twin brother.¹ The operation was a success, and the recipient survived for 9 years postoperatively until his allograft failed as a result of recurrent glomerulonephritis.² This operation was a groundbreaking procedure, and the Nobel Prize in Physiology or Medicine was awarded to Dr. Murray in 1990.

From the Division of Plastic Surgery, Medical University of South Carolina; the Section of Plastic Surgery, Louisiana State University Health Sciences Center; and the Division of Plastic Surgery, New York University Medical Center.

Received for publication July 26, 2007; accepted February 5, 2008.

Presented at the 50th Annual Meeting of the Southeastern Society of Plastic and Reconstructive Surgeons, in Destin, Florida, June 9 through 13, 2007; and at the World Society for Reconstructive Microsurgery Annual Meeting, in Athens, Greece, June 24 through July 2, 2007.

Copyright ©2008 by the American Society of Plastic Surgeons

DOI: 10.1097/PRS.0b013e3181858bb6

Since 1954, transplantation between identical twins has continued to be used for medical management. Other organs and tissues that have been successfully transplanted between identical twins include the small bowel,³ hematopoietic cells,⁴ ovarian cortical tissue,⁵ liver,⁶ pancreas,⁷ full-thickness skin grafts,⁸ and prepuce and bladder mucosal transplants for hypospadias repair.^{9,10} The following procedures are a continuance of the precedent set forth by Dr. Murray and colleagues.

Perforator flaps were first described in 1989 by Koshima and Soeda. These skin flaps were based on a single paraumbilical perforator from the deep inferior epigastric artery.¹¹ The use of superficial inferior epigastric artery (SIEA) and deep inferior epigastric perforator (DIEP) flaps for autologous breast reconstruction was then reported by Allen in 1989 and 1992, respectively.¹²⁻¹⁴ Unlike transverse rectus abdominis musculocutaneous

Disclosure: None of the authors has a financial interest in any of the products, devices, or drugs mentioned in this article.

(TRAM) flaps, perforator flaps leave the abdominal musculature intact, resulting in decreased donor-site morbidity. Advantages of breast reconstruction using perforator flaps as compared with musculocutaneous flaps also include decreased pain, quicker recovery, and preservation of abdominal wall function. Other benefits include lower incidence of hernias, shorter hospital stay, and decreased cost.^{15–17}

CASE REPORTS

Case 1

The first transplant for breast reconstruction was performed on February 29, 2000, between 46-year-old identical twin sisters. The recipient twin had undergone a right mastectomy in 1998 for stage II breast cancer. Immediate reconstruction at an outside hospital involved tissue expansion with subsequent silicone implant reconstruction and contralateral silicone breast augmentation for symmetry. After postoperative radiation therapy, the right silicone prosthesis became exposed and infected and had to be removed. After failed implant reconstruction, the patient still desired breast reconstruction. The patient was nulliparous and an avid runner, and thus had little excess abdominal or gluteal tissue. For these reasons, she was not a candidate for breast reconstruction using her abdomen or buttock as donor sites. Her identical twin sister was multiparous, 10 pounds heavier, and willing to offer her excess abdominal tissue for the reconstruction of her sister's breast.

Before the procedure, the patients had DNA testing to ensure that they were identical twins and would not require immunosuppressive therapy following the transplant. The twins matched at all loci studied in genetic testing, confirming that they were in fact identical twins.

On February 29, 2000, the twin sisters were taken to separate operating rooms for the procedure. A team of two surgeons harvested abdominal tissue from the donor twin, and another team of surgeons prepared the breast pocket and the internal mammary vessels on the recipient twin. The flap was based on lateral row perforators, and a sensory nerve was dissected for coaptation to make this a sensate flap. Once harvested, the flap was transferred to the adjacent operating room for reconstruction of her twin sister's right breast. The abdominal donor site was closed using a standard abdominoplasty closure. The donor twin tolerated the procedure well and was discharged to home from the hospital on postoperative day 2.

The DIEP flap was taken to the adjacent operating room, where the recipient internal mammary vessels and the fourth intercostal nerve of the recipient twin had been prepared. After microvascular anastomoses, the fourth intercostal nerve was coapted to the sensory nerve. The breast flap was contoured and inset with a final weight of 505 g. The recipient twin had an uncomplicated postoperative course and was discharged to home on the fourth day after surgery.

Case 2

In September of 2001, a second pair of identical twin sisters underwent a similar procedure for breast reconstruction. The recipient twin had a history of invasive carcinoma of the left breast treated with mastectomy in November of 2000 followed by postoperative chemotherapy. The patient specifically desired autogenous breast reconstruction. However, the patient had previously undergone abdominoplasty, making this donor site unavailable for breast reconstruction. Reconstruction with a

gluteal artery perforator flap was discussed with the patient; however, she wanted to avoid the morbidity involved in harvesting gluteal tissue and the potential for buttock asymmetry following unilateral reconstruction. She did have an identical twin sister that was eager to donate her lower excess abdominal tissue for breast reconstruction. After confirming that the sisters were monozygotic twins with DNA testing, both patients requested proceeding with a breast reconstruction transplant.

On September 5, 2001, both sisters were taken to adjacent operating rooms for the operation. While harvesting the abdominal tissue for transplant, it was noted that the donor patient had a sufficient superficial epigastric artery and vena comitantes for flap perfusion. A sensate SIEA flap (1350 g) was harvested from the donor twin based on these vessels.

In the adjacent operating room, a team of surgeons had prepared the internal mammary vessels and the fourth intercostal nerve for the free flap transplant. Using an operative microscope, the superficial inferior artery and vein of the transplant flap were anastomosed end-to-end to the recipient internal mammary vessels. The sensory nerve from the flap was approximated to the fourth intercostal nerve to provide sensation to the new breast. After contouring, the final flap weight of 855 g appeared symmetric to the right breast, which underwent a mastopexy at the time of flap inset. By postoperative day 5, the distal inferior lateral aspect of the flap showed signs of ischemia, at which time the patient was taken back to the operating room for debridement of 183 g of the flap. After this revision, the patient did very well and was discharged to home the next day. The donor twin sister had an uncomplicated stay in the hospital and was discharged to home on postoperative day 2.

Case 3

The final two sisters involved in the transplant procedure for breast reconstruction were 44-year-old identical twins. The patient had a history of stage III ductal carcinoma of the left breast treated with modified radical mastectomy with immediate tissue expander placement followed by chemotherapy and radiation therapy. She later underwent a right prophylactic mastectomy with implant reconstruction. After radiation therapy, the left expander became exposed and infected and was removed (Fig. 1). The reconstructed right breast developed a symptomatic capsular contracture. The patient desired autogenous breast reconstruction; however, she was not a candidate for DIEP flap reconstruction because of a previous abdominoplasty. On discussing further options, the patient expressed great concern over having any other area of her body subjected to surgical manipulation. To prevent this, she arrived at the consultation with her identical twin sister, who had not had any abdominal surgery other than a midline cesarean section and later hysterectomy and wanted to donate her extra abdominal tissue for her sister's bilateral breast reconstruction (Fig. 2). The sisters were deemed monozygotic twins after DNA testing.

On October 17, 2006, both sisters were taken to separate operating rooms for transplantation. The donor twin underwent harvest of bilateral DIEP flaps for reconstruction of her sister's breasts. Both flaps were based on two medial row perforators. The initial flap weights were 460 g and 408 g. The flaps were taken to the adjacent operating room, where they were used to reconstruct her sister's breasts. A standard abdominoplasty closure was performed on the donor.

In the adjacent operating room, a second set of surgeons was operating on the recipient twin. Once the right breast expander was removed, the breast pockets and internal mammary vessels were prepared. The left and right DIEP flaps from the donor twin were used to reconstruct the recipient twin sister's right and left breasts, respectively. Both patients were discharged to

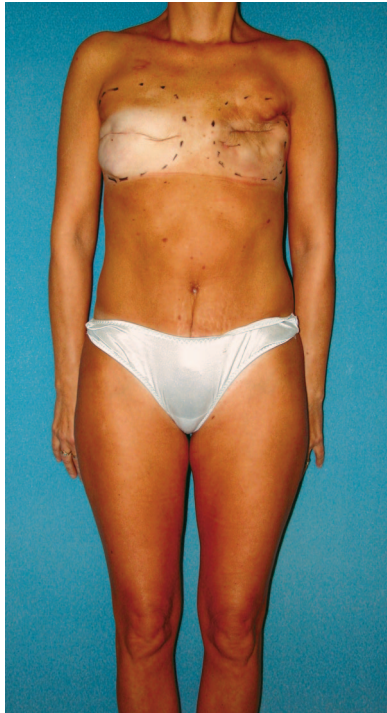


Fig. 1. Preoperative view of the recipient twin after bilateral mastectomy for left breast carcinoma. The patient initially underwent reconstruction with expander placement bilaterally. The left expander had to be removed after radiation therapy.

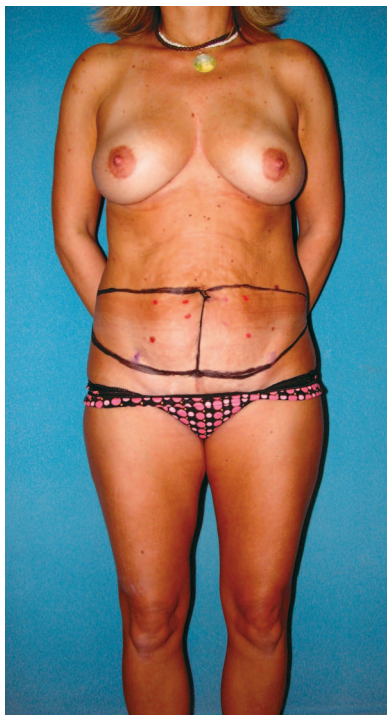


Fig. 2. Preoperative view of the donor twin before bilateral DIEP flap harvest. Incision lines are marked in *black*. Doppler signals of DIEP flap perforators are marked in *red*.

home on postoperative day 4 without complication. Of note, the recipient of the bilateral DIEP flap transplants had essentially no postoperative pain. The donor patient had the usual abdominoplasty postoperative pain.

Three months after the transplants, the twins returned for second-stage procedures (Fig. 3). The recipient twin required bilateral nipple reconstruction and left breast flap revisions because of contracture of the irradiated skin superiorly. The donor twin had mild dog-ear deformities bilaterally from her abdominoplasty. The decision was made to first harvest fat from the donor twin's lateral abdomen to correct for the dog-ear deformities and then to use this fat for lipoinfiltration of the recipient twin's contour defect of the left breast flap. Fat was harvested from the donor twin and centrifuged, and 52 cc of pure adipocytes was injected around the superior and lateral borders of the recipient twin's left reconstructed breast. Both twins tolerated the procedures well and were discharged to home the same day. To our knowledge, this is the first-ever documented case of the transplant of fat cells between two humans for lipoinfiltration.

The recipient twin returned 1 year postoperatively for nipple-areola tattooing. Although we are unable to objectively determine the quantity of fat that has persisted from grafting to the recipient twin's left breast flap/chest wall, we estimate a 40 percent take at 11 months. Fourteen months after the initial procedures, both twins are very happy with their results (Figs. 4 through 6).

DISCUSSION

The preceding three cases present unique challenges to the surgeon and unique opportunities for reconstruction. These cases involve simultaneous reconstruction in two patients who are siblings. Perforator flap transplantation between identical twins for breast reconstruction offers improved quality of life. By transplanting tissue from

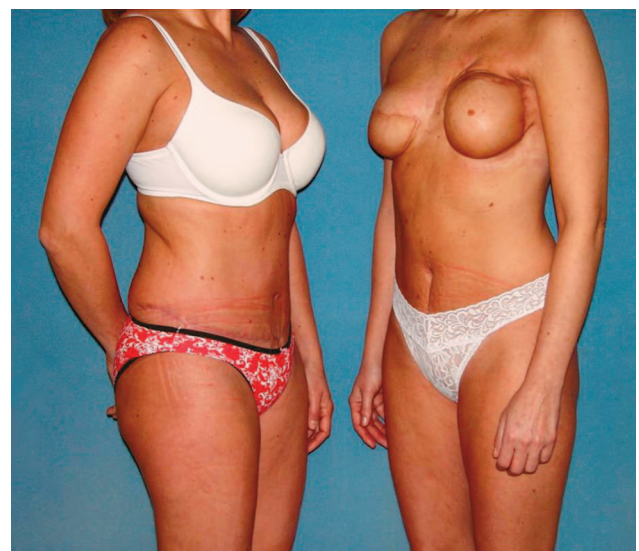


Fig. 3. View of the donor twin (*left*) and the recipient twin (*right*) 3 months after DIEP flap transplant for bilateral breast reconstruction. Fat harvested from the donor twin's abdominal contour defect was used to correct the recipient twin's left breast contour defect by lipoinfiltration.

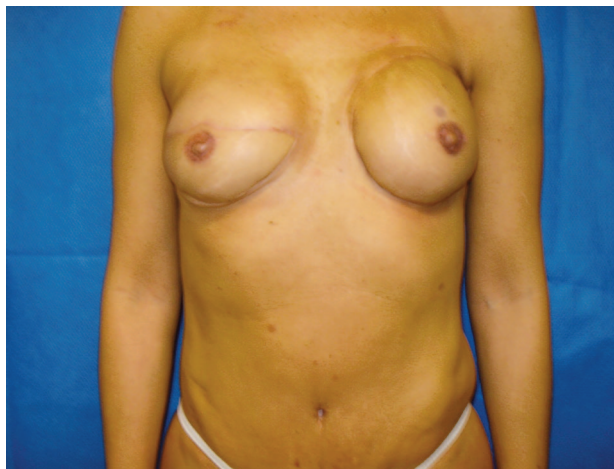

Fig. 4. Anteroposterior view of the recipient twin 14 months after DIEP transplant for bilateral breast reconstruction.

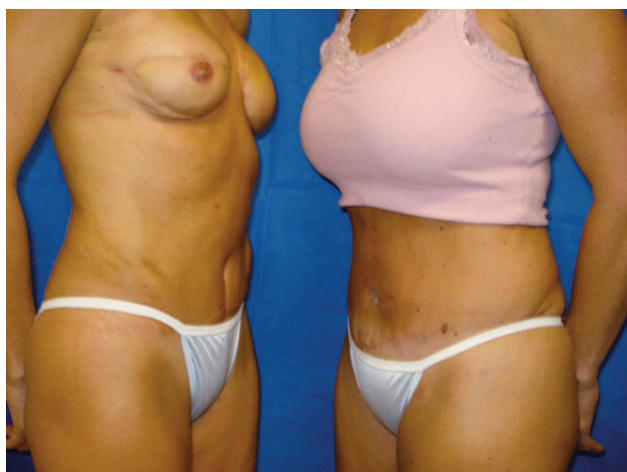

Fig. 5. Oblique view of the donor (*right*) and recipient (*left*) twins 14 months after the initial procedure.

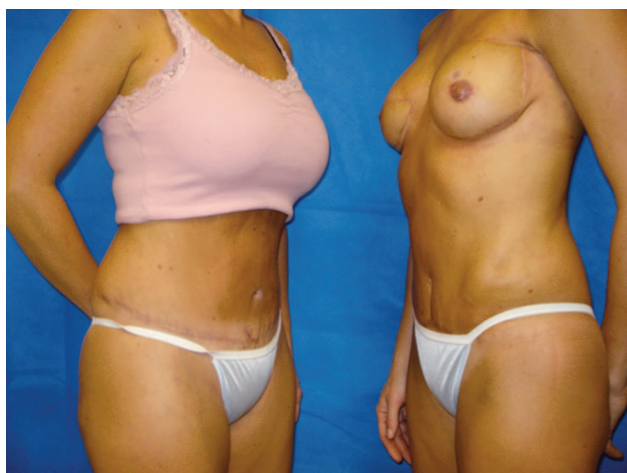

Fig. 6. Contralateral oblique view of the donor twin (*left*) and the recipient twin (*right*) 14 months after DIEP transplant for bilateral breast reconstruction.

one twin to another, the recipient twin's quality of life is improved, with no donor-site morbidity. The donor twin's quality of life is improved both aesthetically and psychologically. As she donates her excess abdominal tissue, the donor twin has an improved body contour and an improved sense of well-being knowing that she was able to help her sister recover from breast cancer. These patients were all offered other methods of breast reconstruction including latissimus dorsi myocutaneous flap with implant reconstruction, gluteal artery perforator flap reconstruction (when available), anterolateral thigh flaps, and lateral thigh perforator flaps. Of the options presented, these patients chose, and we recommended, DIEP/SIEA transplants from their sisters. In our opinion, this option represented the best approach to reduce patient morbidity and improve patient well-being for both the donor and recipient twins. As of today, all patients have stated that they would undergo the same procedure again if given the option.

Before proceeding with these cases, it was essential, first, to determine that the twins were monozygotic and, second, to discuss the potential of the donor twin to develop breast cancer in the future. To ensure that these twins were monozygotic, genetic testing was performed for all three cases. This avoided the use of postoperative immunosuppressive therapy. In using immunosuppressive therapy, recipient patients are exposed to increased risk of infection, increased cancer recurrence, and increased risk of transplant failure.¹⁸

We also counseled the donor twins on the possibility that they would subsequently develop breast cancer and that their abdomen would no longer be a potential donor site for their own reconstruction. In the literature, it was found that over 75 percent of these patients will not develop breast cancer in the future. In a study by Mack and Peto, monozygotic twins of breast cancer patients were found to have an annual risk of developing breast cancer of 1.31 percent.¹⁹ This same study found the 20-year risk of developing breast cancer for our donor twins to be 24 percent.¹⁹ Another study from 2000 found the absolute risk for a monozygotic twin of a breast cancer patient of developing breast cancer before 75 years of age to be only 13 percent.²⁰ Test results were negative for *BRCA1* or *BRCA2* mutations in all three sets of twins. As of today, none of the donor twins in our three cases has subsequently developed breast cancer, nor has any donor twin complained of any abdominal-site complications (5-year average follow-up). However, if they do develop breast cancer and have a mastectomy, we have informed them of

the numerous reconstructive options that are available, including gluteal artery perforator flaps, anterolateral thigh flaps, lateral thigh perforator flaps, latissimus dorsi flaps, and implant/expander reconstruction.

CONCLUSIONS

Transplantation continues to be an important surgical treatment modality. The principles of transplantation have been applied to a variety of circumstances, now including breast reconstruction. The previous case reports are the first documentation of flap transplantation for breast reconstruction. The success demonstrated by these case reports shows that perforator flap transplantation between identical twins is an excellent option for breast reconstruction. As Dr. Murray's work led to the eventual transplantation of kidneys between unrelated individuals, time will tell whether the future of breast reconstruction will involve composite tissue transplantation between nonidentical twins.

Robert J. Allen, Jr., M.D.
125 Doughty Street, Suite 480
Charleston, S.C. 29403
boballen@diepflap.com

REFERENCES

- Merrill, J. P., Murray, J. E., Harrison, J. H., and Guild, W. R. Successful homotransplantation of the human kidney between identical twins. *J.A.M.A.* 160: 277, 1956.
- Sayegh, M. H., and Carpenter, C. B. Transplantation 50 years later: Progress, challenges, and promises. *N. Engl. J. Med.* 351: 2761, 2004.
- Schena, S., Testa, G., Setty, S., Abcarian, H., and Benedetti, E. Successful identical-twin living donor small bowel transplant for necrotizing enterovascularitis secondary to Churg-Strauss syndrome. *Transpl. Int.* 19: 594, 2006.
- Cohen, J. M., Rogers, V., Gaspar, H. B., et al. Serial transplantation of mismatched donor hematopoietic cells between HLA-identical sibling pairs with congenital immunodeficiency: In vivo tolerance permits rapid immune reconstitution following T-replete transplantation without GVHD in the secondary recipient. *Blood* 108: 2124, 2006.
- Silber, S. J., Lenahan, K. M., Levine, D. J., et al. Ovarian transplantation between monozygotic twins discordant for premature ovarian failure. *N. Engl. J. Med.* 353: 58, 2005.
- Liu, L. U., Schiano, T. D., Min, A. D., et al. Syngeneic living-donor liver transplantation without the use of immunosuppression. *Gastroenterology* 123: 1341, 2002.
- Benedetti, E., Dunn, T., Massad, M. G., et al. Successful living related simultaneous pancreas-kidney transplant between identical twins. *Transplantation* 67: 915, 1999.
- Kortholm, B. Transplantation between monozygotic twins. *Scand. J. Plast. Reconstr. Surg.* 2: 64, 1968.
- Donovan, J., and Maizels, M. Transplantation of the prepuce to facilitate hypospadias repair in monozygotic twins. *J. Urol.* 136: 1077, 1986.
- Weiss, R. E., Garden, R. J., and Stone, N. N. Isograft bladder mucosal transplantation for hypospadias repair in identical twins. *J. Urol.* 150: 1884, 1993.
- Koshima, I., and Soeda, S. Inferior epigastric artery skin flap without rectus abdominis muscle. *Br. J. Plast. Surg.* 42: 645, 1989.
- Allen, R. The superficial inferior epigastric artery flap: An anatomic and clinical study for use in reconstruction of the breast. In Proceedings of the Xth Annual Meeting of the Southeastern Society of Plastic and Reconstructive Surgeons, Kiawah, S.C., June 3-7, 1990.
- Allen, R. J., and Heitland, A. S. Superficial inferior epigastric artery flap for breast reconstruction. *Semin. Plast. Surg.* 16: 35, 2002.
- Allen, R. J., and Treece, P. Deep inferior epigastric perforator flap for breast reconstruction. *Ann. Plast. Surg.* 32: 32, 1994.
- Blondeel, N., Vanderstraeten, G. G., Monstrey, S. J., et al. The donor site morbidity of free DIEP flaps and free TRAM flaps for breast reconstruction. *Br. J. Plast. Surg.* 50: 322, 1997.
- Garvey, P. B., Buchel, E. W., Pockaj, B. A., et al. DIEP and pedicled TRAM flaps: A comparison of outcomes. *Plast. Reconstr. Surg.* 117: 1711, 2006.
- Kaplan, J. L., and Allen, R. J. A cost-based analysis of perforator flaps vs. TRAM flaps in breast reconstruction. *Plast. Reconstr. Surg.* 105: 943, 2000.
- St. Clair, D. M., St. Clair, J. B., Swainson, C. P., Bamforth, F., and Machin, G. A. Twin zygosity testing for medical purposes. *Am. J. Med. Genet.* 77: 412, 1998.
- Mack, T. M., and Peto, J. High constant incidence in twins and other relatives of women with breast cancer. *Nat. Genet.* 26: 411, 2000.
- Lichtenstein, P., Holm, N. V., Verkasalo, P. K., et al. Environmental and heritable factors in the causation of cancer. *N. Engl. J. Med.* 343: 78, 2000.