



Clavicle morphometry revisited: a 3-dimensional study with relevance to operative fixation

Abdo Bachoura, MD^a, Andrew S. Deane, PhD^b, James N. Wise, MD^c,
Srinath Kamineni, MD, FRCS-Orth^{a,*}

^aDepartment of Orthopaedic Surgery and Sports Medicine, Elbow Shoulder Research Center, University of Kentucky, Lexington, KY, USA

^bDepartment of Anatomy and Neurobiology, University of Kentucky, Lexington, KY, USA

^cDepartment of Radiology, Division of Musculoskeletal Radiology, University of Kentucky, Lexington, KY, USA

Background: The advocacy for operative fixation of midshaft clavicle fractures has prompted a reemergence of interest in clavicle anatomy. Three-dimensional (3D) anatomical studies provide more information than 2-dimensional studies, but are currently rare.

Material and methods: Twenty-five skeletonized clavicles were digitized using a laser scanner. Three-dimensional computer software was used to analyze the data. Clavicles were divided into medial, middle, and lateral segments based on the medial and lateral apices of curvature and their lengths and midpoint cortical diameter measured. The angles of medial and lateral curvatures were measured in standardized axial and coronal planes. The medial and lateral curvatures were fitted with circles and the radii of curvature measured. Correlations between the intrinsic dimensions of the clavicle were assessed.

Results: The mean length was 136.7 mm. The medial, middle, and lateral segments had mean lengths of 48, 56, and 32.7 mm, respectively. In the axial plane, the mean medial and lateral angles were 149.5° and 145.8°, respectively. In the coronal plane, the mean medial and lateral angles were 178.2° and 174.2°, respectively. The mean midpoint cortical diameter was 10.9 mm. The mean medial and lateral radii of curvature were 66.4 and 33.5 mm, respectively. The length and cortical diameter and length and medial radius of curvature were found to positively correlate, $R^2 = .355$ and $.184$, respectively.

Conclusion: Using standardized measurements, we were able to accurately characterize the dimensions of the clavicle. We found that the length of the clavicle correlates with the midpoint cortical diameter and with the radius of medial curvature.

Level of evidence: Basic Science Study, Anatomic Study.

© 2013 Journal of Shoulder and Elbow Surgery Board of Trustees.

Keywords: Clavicle; anatomy; morphometry; 3-dimensional study

*Reprint requests: Srinath Kamineni, MD, FRCS-Orth, Director of the Elbow Shoulder Research Center, University of Kentucky Department of Orthopaedic Surgery and Sports Medicine, 740 South Limestone Street K-412 Kentucky Clinic, Lexington, KY 40536-0284, USA.

E-mail address: srinathkamineni@gmail.com (S. Kamineni).

The clavicle has a complex and variable bony anatomy. Midshaft clavicle fractures have traditionally been managed conservatively, but the turn of the 21st century has seen a re-emergence of interest in operative fixation due to a number of reasons. First, several clinical outcome studies revealed lower rates of nonunion and better patient related outcomes after

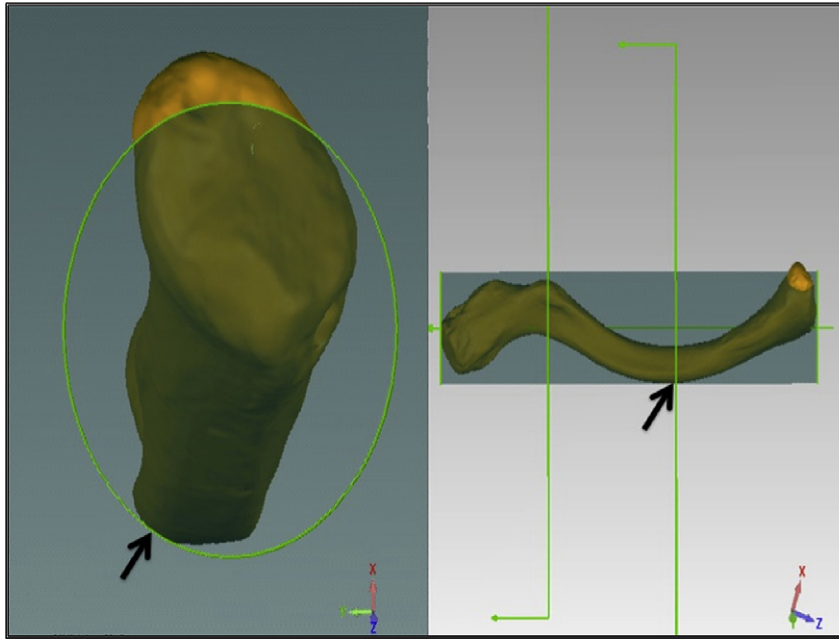


Figure 1 An illustration of how the apex of curvature was determined. The left graphic demonstrates a view looking directly down the barrel of the cylinder of best fit from the sternoclavicular end. The medial apex of the clavicle is seen making contact with the cylinder's rim (*arrow*). This point of contact was set as the apex of curvature. The right graphic demonstrates the corresponding medial apex of curvature on an axial view (*arrow*). The vertical lines bisect the clavicle at the medial and lateral apices of curvature.

operative fixation.^{6,11,15} Second, malunion of the clavicle may cause glenoid malpositioning, which, in turn, can lead to functional deficits during abduction.³ In addition, promising healing and functional outcomes have been observed in osteoporotic patients who have poor bone healing potential.⁸

Previous anatomic studies, although useful and have contributed to our understanding of clavicle anatomy, have lacked reproducibility and utilized measurement methods susceptible to various human related selection errors.^{2,12,14} Recent technological advances have made available both hardware and software that potentially enhance the precision, objectivity, reproducibility, and applicability of morphometric studies. There is currently a lack of 3-dimensional (3D) morphologic studies that analyze the clavicle.^{4,5} The goals of this article are: (1) to present an accurate morphometric description of the clavicle using a novel 3D approach; (2) to identify and quantify any relations within the intrinsic structure of the clavicle; and (3) to investigate the geometric basis of the age old nomenclature that divides the clavicle into “thirds.” A more objective presentation of clavicle anatomy will help to better understand the complexity of the clavicle, which will have clinical relevance in terms of clavicle reconstruction, fracture management, and implant refinement.

Materials and methods

Twenty-five skeletonized, dried, randomly selected adult human clavicles were acquired from our university's anatomy laboratory

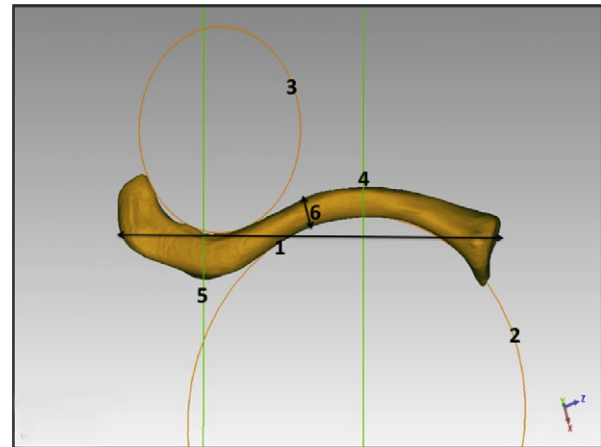


Figure 2 Diagram illustrating: (1) clavicle length; (2) circle of medial curvature; (3) circle of lateral curvature; (4) medial apex of curvature; (5) lateral apex of curvature; (6) midpoint cortical diameter.

and digitized using a FaroArm Platinum laser scanner (FARO, Lake Mary, FL, USA). Each clavicle was set up for scanning by suspending it under tension with a cord. A 3D inspection computer software, Geomagic Qualify (Geomagic, Research Triangle Park, NC, USA) was used to register and analyze the data.

Using the computer software, the length of each clavicle was determined based on the line of best fit through the clavicle. Each clavicle was divided into 3 segments (a medial, middle, and lateral segment) based on the medial and lateral apices of curvature (Fig. 1). For descriptive purposes, the length of the middle and

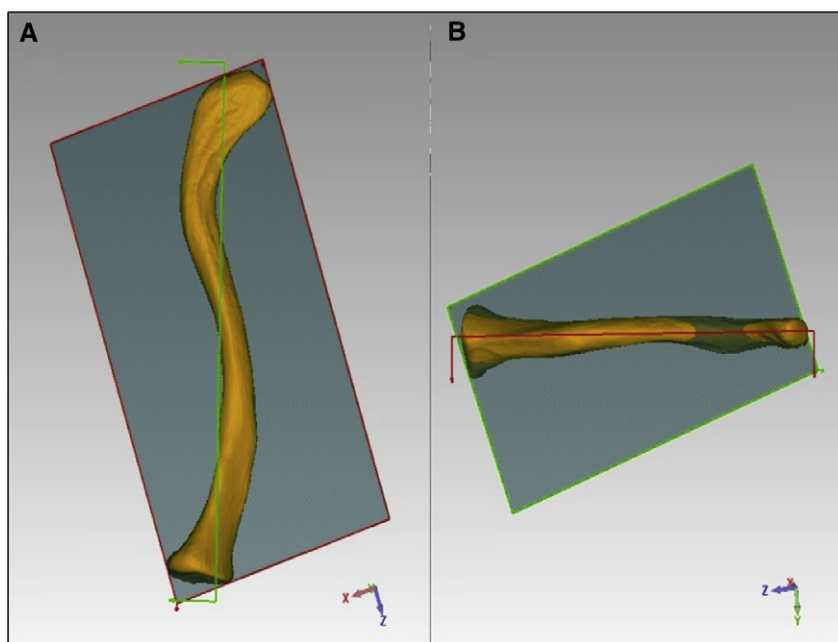


Figure 3 Demonstration of the axial and coronal planes; 3A illustrates the axial plane (outlined red) used as the reference plane to measure angles in the axial view. 3B illustrates the coronal plane (outlined green) used as the reference plane to measure angles in the coronal view.

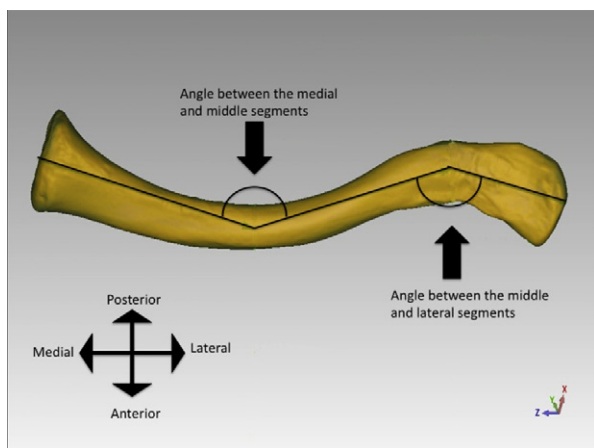


Figure 4 A superior, axial view of the clavicle demonstrating the method by which the inter-segmental angles were measured.

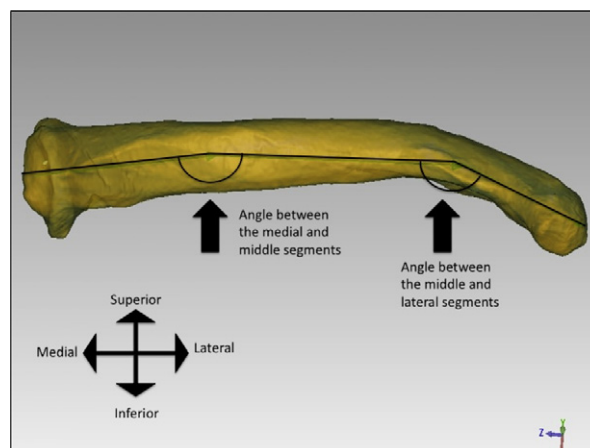


Figure 5 An anterior, coronal view of the clavicle demonstrating the method by which the inter-segmental angles were measured.

medial segments was expressed as a factor of the length of the lateral segment, because the lateral segment was almost always the shortest. The maximal cortical diameter at the midpoint was measured using the software. This measurement was used to reflect the midshaft thickness. In addition, the medial and lateral curvatures were fitted with circles and their radii measured. The regions of curvature that were fitted with a circle were based on the area most clearly suggesting an arc of curvature (Fig. 2).

Angles between the medial and middle as well as the middle and lateral segments were measured in both the axial and coronal planes (Fig. 3). The axial plane was set as the plane of best fit through the clavicle. The coronal plane was set as the plane perpendicular to the axial plane and along the same axis as the line of best fit. Intersegmental angles were created by lines connecting

the center points of the sternoclavicular end to the medial apex, the medial apex to the lateral apex, and the lateral apex to the acromioclavicular end (Figs. 4 and 5).

In order to validate the utility of the laser scanner, all clavicles underwent computed tomography (CT) using a SOMATOM Definition AS single source 64 slice CT scanner (Siemens, Washington, DC, USA) at 0.600 mm slices reconstructed to 2 mm slices using a 70f sharp filter and standard Siemens osteo algorithm. Each laser-scanned clavicle and its CT scanned counterpart were aligned then compared in 3D. Only 22 out of 25 clavicles were available for analysis due to either a human or software error that occurred during data transfer to the CDs. The DICOM files were imported from the CDs into the computer software and

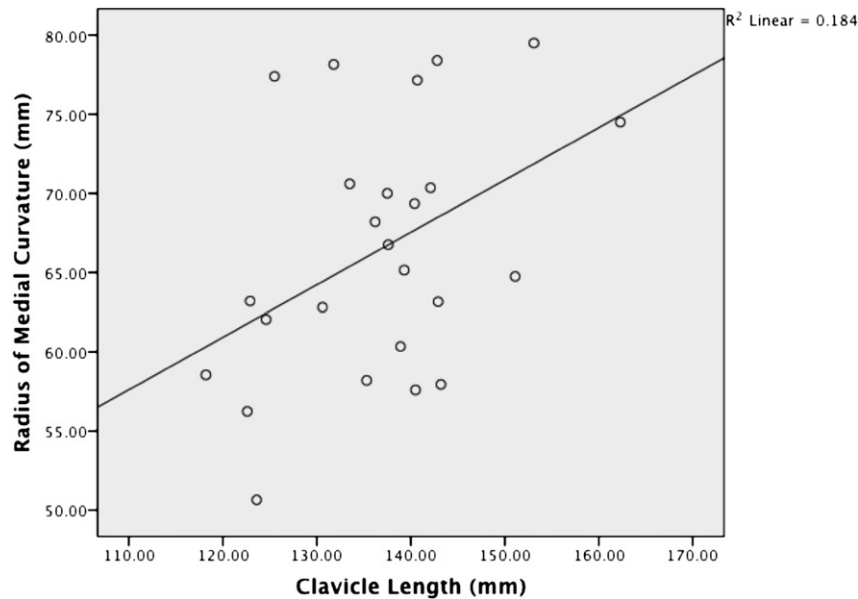


Figure 6 Scatter plot demonstrating the correlation between clavicle length and the radius of medial curvature.

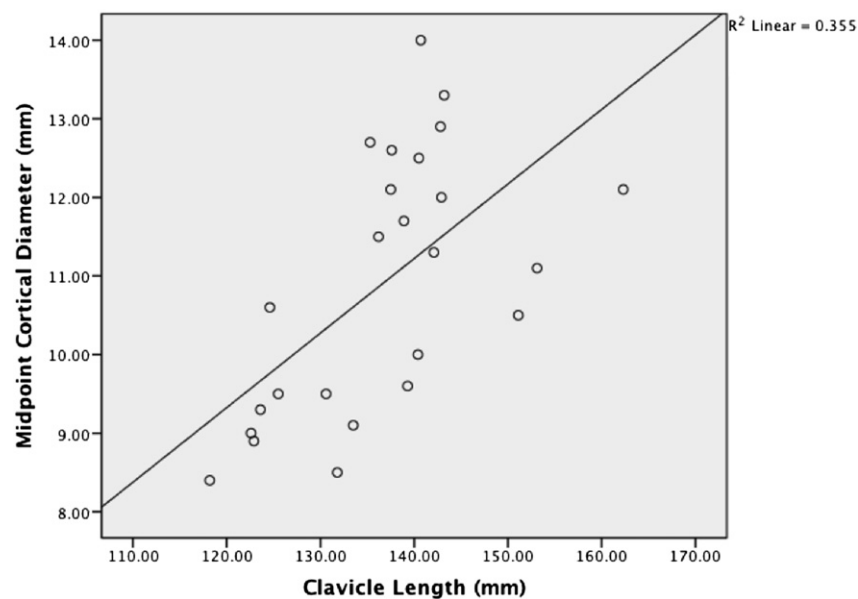


Figure 7 Scatter plot demonstrating the correlation between the length of the clavicle and the cortical diameter at the midpoint.

converted to wrap (.wrp) files. The “average error” reported by the software indicates the average deviation of all points of comparison during best-fit alignment of the clavicles. The “average deviation” reported by the software is the deviation for the 3D comparison function, and indicates the average deviation that is found anywhere in the comparison. During this process, the laser-scanned clavicles were set as the “reference objects,” while the CT scanned clavicles were set as the “test objects.”

The statistical software package PASW 18 was utilized (PASW, IBM Corporation, Somers, NY, USA). For 2 group comparisons, we used a paired *t* test. For 3 group comparisons,

a reproduced measures ANOVA was used. Post hoc Bonferroni analysis was used to compare any significant differences found with ANOVA. A Pearson correlation coefficient was computed to assess the relationship between: (1) clavicle length and the radius of medial curvature (Fig. 6); (2) clavicle length and the radius of lateral curvature; (3) clavicle length and the cortical diameter at the midpoint (Fig. 7); (4) midpoint cortical diameter and the radius of medial curvature; (5) midpoint cortical diameter and the radius of lateral curvature; (6) the medial and lateral radii of curvature; (7) clavicle length and the angles between the medial and middle segments in the axial plane; (8) clavicle length and the

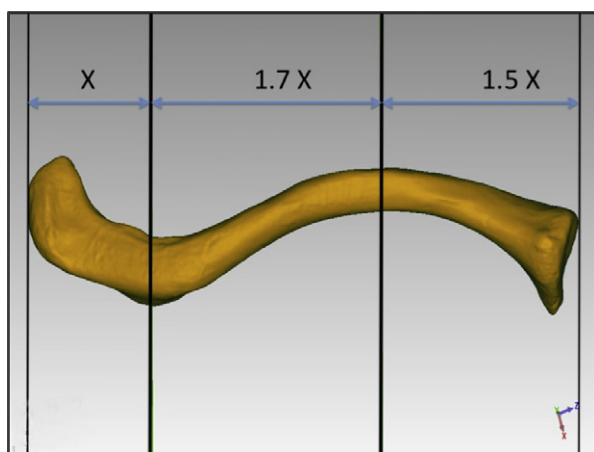


Figure 8 Diagram illustrating the clavicle divided into 3 segments. This division was based on the apices of curvature. The lengths of the middle and medial segments were expressed as factors of the lateral segment's length (X).

angles between the middle and lateral segments in the axial plane; and (9) the medial and lateral angles in the axial plane.

Differences that had less than 0.05 probability of occurring from chance were considered to be statistically significant.

Results

The mean length of the 25 clavicles was 136.7 mm (118.2-162.3 mm) with a standard deviation of 10.4 mm. A significant difference between the lengths of the lateral, middle, and medial segments was found ($P < .001$). The Bonferroni post hoc analysis revealed that the mean length of the lateral segment was 32.7 (28.4-40.2 mm) and was significantly less than the medial segment 48.0 (34.6-69.1 mm), and the length of the medial segment was significantly less than the middle segment 56.0 (45.0-64.1 mm). It was found that, on average, the middle segment was 1.7 times the length of the lateral segment, and the medial segment was 1.5 times the length of the lateral segment, $P = .02$ (Fig. 8). The maximum cortical diameter measured at the midpoint of the clavicle had a mean of 10.3 (8.4-13.0 mm) (Table I).

The curvature of the clavicle is partly responsible for its anatomic complexity. In the best-fit plane, the circle fitted within the medial curvature had a mean radius of 66.4 mm, while the radius of the circle fitted in the lateral curvature was 33.5 mm, $P < .001$ (Table II). When measured in line with the axial plane, the medial intersegmental angle had a mean of 149.5 (143.3-156.8°), while the lateral intersegmental angle had a mean of 145.8 (138.0-155.4°). The difference in means was found to be statistically significant, $P = .009$. When measured in line with the coronal plane, the medial intersegmental angle had a mean of 178.2 (165.5-186.2°), while the lateral intersegmental angle had a mean of 174.2 (161.4-182.3°). The difference in means was also found to be statistically significant, $P = .007$ (Table II).

A Pearson correlation coefficient (R) was computed to assess the relationship between the intrinsic dimensions of the clavicle. We found a positive correlation between the length of the clavicle and the radius of medial curvature $R = .429$, $P = .032$, $R^2 = .184$, and the length of the clavicle and the midpoint cortical diameter $R = .596$, $P = .002$, $R^2 = .355$ (Fig. 5). No relations were found between the midpoint cortical diameter and the radius of medial curvature $R = .142$, $P = .498$; midpoint cortical diameter and the lateral radius of curvature $R = -.138$, $P = .511$; length of the clavicle and the radius of lateral curvature $R = .02$, $P = .915$; the radii of medial and lateral curvature $R = -.01$, $P = .963$; clavicle length and medial-middle segment angle (in the axial plane) $R = -.14$, $P = .508$; clavicle length and the middle-lateral segment angle (in the axial plane) $R = -0.075$, $P = .721$; or medial and lateral angles in the axial plane $R = .104$, $P = .620$.

The average error during point alignment was 1 mm, while the average positive and negative deviations during object comparison were +0.6 and -3.5 mm, respectively (Table III).

Discussion

The recent advocacy for operative fixation of certain midshaft fractures of the clavicle has prompted the re-emergence of interest in clinically pertinent anatomy. The human clavicle has a highly variable and complex bony anatomy that makes accurate, objective, and reproducible study of its morphology a challenge, as described by Daruwalla et al.⁴ Three-dimensional anatomical studies can provide more information than traditional 2-dimensional (2D) studies. Huang et al used a 3D digitizer but 2D analysis during a study of the applicability of clavicle plates.⁷ In their 3D studies, Daruwalla et al standardized a reference orientation for measuring the anatomic features of a clavicle and used statistics and principal component analysis to study the size and shape variations of clavicles.^{4,5} We set out to: (1) present an accurate morphometric description of the clavicle using a novel 3D analysis; (2) determine and quantify the relations between the intrinsic characteristics of the clavicle, such as curvature, length and thickness; and (3) investigate the geometric basis of clavicle fracture nomenclature, which divides the clavicle into thirds.

It is important to consider clavicle thickness and curvature in both plate and intramedullary fixation of clavicle fractures. In clinical practice, the degree of clavicle curvature may help determine the type of plate or whether intramedullary pinning is a reasonable treatment option. The ability to gauge these parameters from the length or thickness of the clavicle can be an important tool for surgeons during preoperative planning. We found a positive correlation between the length of the clavicle and the radius of medial curvature $R = .429$, $n = 25$, $P = .016$, but only

Table I Clavicle dimensions

Variable	Results			P value
	Mean	SD	Min-max	
Total length (mm)	136.7	10.4	118.2-162.3	
MeS length (mm) (% of total length)	48.0 (34.9)	9.1 (4.7)	34.6-69.1 (28.0-45.0)	<.001
MiS length (mm) (% of total length)	56.0 (41.2)	5.0 (3.9)	45.0-64.1 (32.0-48.0)	
LaS length (mm) (% of total length)	32.7 (24.0)	3.1 (2.4)	28.4-40.2 (20.4-30.3)	
MiS as a proportion of LaS	1.7	0.2	1.2-2.0	.002
MeS as a proportion of LaS	1.5	0.3	0.9-2.0	
Midpoint cortical diameter (mm)	10.9	1.7	8.4-13.0	

SD, standard deviation; MeS, medial segment; MiS, middle segment; LaS, lateral segment.

Table II Clavicle dimensions: curvature and angles

Variable	Results			P value
	Mean	SD	Min-max	
Radius of medial curvature (mm)	66.4	8.0	50.7-79.5	<.001
Radius of lateral curvature (mm)	33.5	10.5	19.5-57.8	
Axial plane				
Angle between medial and middle segments (°)	149.5	3.8	143.3-156.8	.009
Angle between lateral and middle segments (°)	145.8	5.7	138.0-155.4	
Coronal plane				
Angle between medial and middle segments (°)	178.2	4.8	165.5-186.2	.007
Angle between lateral and middle segments (°)	174.2	4.6	161.4-182.3	

SD, standard deviations.

18.4% of the variance was explained. We also found a correlation between the length of a clavicle and the midpoint cortical diameter $R = .596$, $n = 25$, $P < .001$, with 35.5% of the variance explained.

Factors such as sex and side have also been known to influence the magnitude of medial curvature and clavicle thickness, with males typically having greater clavicle width and thickness.^{2,4,10} In our study, the medial curvature had a greater mean radius than the lateral curvature. Our mean medial and lateral radii of curvature were 66.4 and 33.5 mm, respectively, as compared to 71 and 39 mm in Andermahr et al's study, who found no gender-specific differences for the medial curvature of the clavicle. In contrast, a side-specific difference was noted, with the left side having a greater radius of curvature.²

The clavicle has traditionally been divided into "thirds," based on the location of the ligaments, types of fracture, and subsequent natural history.^{1,13} On the other hand, Moseley described the clavicle as consisting of a medial and a lateral 1/4, and an inner 2/4.¹² The Orthopaedic Trauma Association's description of clavicle fractures lists midshaft fractures as diaphyseal fractures (code 15-B) without specifying any lengths or proportions, but clearly illustrates the diaphysis as the major proportion of the total length of the clavicle.⁹ Therefore, although dividing the clavicle into thirds has a practical advantage, this division is not based on geometric dimensions. During this anatomic

study, we divided the clavicle into 3 segments, separated by the apices of curvature to facilitate anatomic description (Fig. 8). We found it difficult to justify dividing the clavicle into 3 equal segments, because part of the clavicle diaphysis would have inevitably been included in either the medial or lateral "thirds," thus creating an overlap in fracture locations (eg, a diaphyseal midshaft fracture occurring in the medial or lateral thirds). The middle segment was, on average, 41.2% of the total length of the clavicle, and this ranged from 32.0% to 48.0% (Table I). Data from this study suggest that dividing the clavicle into "thirds" (implying 3 equal segments) may not be a technically accurate method for reflecting the 3 different categories of clavicle injuries, and this nomenclature may add to the confusion during future anatomic research and possibly in the clinical setting. With reference to clavicle fractures, we agree with the OTA's descriptive terms: "medial end, lateral end and clavicle diaphysis fractures." An alternative option may be to replace "third" by a less specific term, such as "segment."

The limitations of this study include the small number of clavicles analyzed, but this study employs a unique method and forms the basis for future investigations. The specimens analyzed did not have any recorded demographic data, which limited gender, race, and age based analyses. This paper presents data on the average dimensions of clavicles; however, as Huang et al pointed out,⁷ working

Table III Comparing the accuracy of laser scanned and CT scanned clavicles

	Mean	SD	Min-max
Average error (mm)	1.0	0.2	0.6-1.7
Positive average deviation (mm)	0.6	0.4	0.2-2.0
Negative average deviation (mm)	3.5	0.7	2.4-4.8

SD, standard deviations.

with “averages” may cause significant problems when trying to apply this information to surgical situations, such as fitting a plate to the clavicle. We believe that presenting these morphometric relations in 3D, however, is of value given the scarcity of 3D studies. Presenting the outcomes and this methodology may stimulate further discussion regarding the bony anatomy of the clavicle. The specimens used were skeletonized, and we were unable to account for this factor. The novel technique presented here appears to be a valid and accurate method for approaching anatomy. In comparison to a high resolution CT scanner, the laser scanner was more accurate; but this may not be clinically significant in orthopedic surgery.

Despite the laser scanner being restricted to surface features only, the main advantage of utilizing this device would be for the mapping of topographic soft tissue footprints. On the other hand, a CT scanner is capable of providing information about the medullary dimensions of bone. The average error during point alignment was 1 mm, while the average positive and negative deviations during object comparison were +0.6 and -3.5 mm, respectively (Table III). The relatively high negative deviations may have occurred because the ends of the clavicles, where the cortex was sparse in our specimens did not register well on the DICOM (CT) images.

Conclusion

This study presents a novel 3D study of the complex anatomy of the clavicle. We were able to accurately measure and analyze the intrinsic characteristics of clavicles. We were able to corroborate the magnitude of clavicle curvature and we found that the length of the clavicle correlates with the midpoint cortical diameter and with the radius of medial curvature.

Acknowledgments

We would like to thank Dr. Timothy Uhl for his assistance with the statistical analysis, and Dr. Bruce Maley and Mr. Gary Ginn for their assistance in

specimen acquisition from our university’s anatomy laboratory.

Disclaimer

The authors, their immediate families, and any research foundations with which they are affiliated did not receive any financial payments or other benefits from any commercial entity related to the subject of this article.

References

- Allman FL Jr. Fractures and ligamentous injuries of the clavicle and its articulation. *J Bone Joint Surg Am* 1967;49:774-84.
- Andermahr J, Jubel A, Elsner A, Johann J, Prokop A, Rehm KE, et al. Anatomy of the clavicle and the intramedullary nailing of mid-clavicular fractures. *Clin Anat* 2007;20:48-56. doi:10.1002/ca.20269
- Andermahr J, Jubel A, Elsner A, Prokop A, Tsikaras P, Jupiter J, et al. Malunion of the clavicle causes significant glenoid malposition: a quantitative anatomic investigation. *Surg Radiol Anat* 2006;28:447-56. doi:10.1007/s00276-006-0122-z
- Daruwalla ZJ, Curtis P, Fitzpatrick C, Fitzpatrick D, Mullett H. Anatomic variation of the clavicle: A novel three-dimensional study. *Clin Anat* 2010;23:199-209. doi:10.1002/ca.20924
- Daruwalla ZJ, Curtis P, Fitzpatrick C, Fitzpatrick D, Mullett H. An application of principal component analysis to the clavicle and clavicle fixation devices. *J Orthop Surg Res* 2010;26:21. doi:10.1186/1749-799X-5-21
- Hill JM, McGuire MH, Crosby LA. Closed treatment of displaced middle-third fractures of the clavicle gives poor results. *J Bone Joint Surg Br* 1997;79:537-9.
- Huang JI, Toogood P, Chen MR, Wilber JH, Cooperman DR. Clavicular anatomy and the applicability of precontoured plates. *J Bone Joint Surg Am* 2007;89:2260-5. doi:10.2106/JBJS.G.00111
- Khan SA, Shamsery P, Gupta V, Trikha V, Varshney MK, Kumar A. Locking compression plate in long standing clavicular nonunions with poor bone stock. *J Trauma* 2008;64:439-41. doi:10.1097/01.ta.0000238716.97303.b3
- Marsh JL, Slongo TF, Agel J, Broderick JS, Creevey W, DeCoster TA, et al. Fracture and dislocation classification compendium - 2007: Orthopaedic Trauma Association classification, database and outcomes committee. *J Ortho Trauma* 2007;21. S1-133.
- McCormick WF, Stewart JH, Greene H. Sexing of human clavicles using length and circumference measurements. *Am J Forensic Med Pathol* 1991;12:175-81.
- McKee MD. Clavicle fractures in 2010: sling/swathe or open reduction and internal fixation? *Orthop Clin North Am* 2010;41:225-31. doi:10.1016/j.ocl.2009.12.005
- Moseley HF. The clavicle: its anatomy and function. *Clin Orthop Relat Res* 1968;58:17-27.
- Neer CS II. Nonunion of the clavicle. *J Am Med Assoc* 1960;172:1006-11.
- Rowe CR. An atlas of anatomy and treatment of midclavicular fractures. *Clin Orthop Relat Res* 1968;58:29-42.
- Zlowodzki M, Zelle BA, Cole PA, Jeray K, McKee MD. Evidence-based Orthopaedic Trauma Working Group. Treatment of acute mid-shaft clavicle fractures: systematic review of 2144 fractures: on behalf of the Evidence-Based Orthopaedic Trauma Working Group. *J Orthop Trauma* 2005;9:504-7.