



REVIEW ARTICLES

The olecranon spur



Danielle Reilly, MD, Srinath Kamineni, MD*

Department of Orthopaedic Surgery, University of Kentucky, Lexington, KY, USA

Background: There is very little information for today's clinician on olecranon spurs. In addition, there is some ambiguity in the literature, with the terms "olecranon spur" and "olecranon osteophyte" sometimes being used interchangeably. This review presents the current knowledge about olecranon spur anatomy, pathophysiology, clinical presentation, diagnosis, treatment options and their outcomes, as well as clarification of the terms "spur" and "osteophyte".

Methods: The PubMed and Google Scholar databases were searched using the terms "olecranon spur," "olecranon traction spur," and "olecranon osteophyte." The resulting articles were used to find other manuscripts pertaining to the subject.

Results: Very few articles were found as a result of these search criteria and were limited to a few case reports and a study investigating the postoperative outcomes of spur removal. Confusion of the terms "olecranon spur" and "olecranon osteophyte" was noted in 6 of the manuscripts.

Conclusions: The mechanism of olecranon spur formation has not been confirmed but seems to be similar to that of spurs at other entheses. In addition, the current literature represents a small number of patients and selects only those who required surgical intervention. Three methods of spur resection have been published, and all have good outcomes with small patient numbers and limited follow-up.

Level of evidence: Narrative Review.

© 2015 Journal of Shoulder and Elbow Surgery Board of Trustees.

Keywords: Olecranon spur; olecranon traction spur; enthesophytes; olecranon osteophytes; triceps tendonitis; olecranon bursitis

Olecranon spurs are a pathology that have been present for hundreds of years and can be seen in the sketches of early anatomists, such as Bernard Albinus' 1747 publication *Tabulae sceleti et musculorum corporis* (Fig. 1). Despite this, the first report of them in the clinical literature was in 1969, when Cimmino⁸ published a case report of an allegedly missed fracture of an olecranon spur after a lawsuit was brought against him. He notes that, "The trained radiologist is aware of the frequent presence of a narrow band of radiolucency at the base of the spur".⁸

Investigational review board approval was not required for this review.

*Reprint requests: Srinath Kamineni, MD, University of Kentucky, Kentucky Clinic, 740 S Limestone, K412, Lexington, KY 40536, USA.

E-mail address: srinathkamineni@gmail.com (S. Kamineni).

Therefore, it seems that spurs were known to be a common radiographic finding, but the clinical importance was not addressed for another 42 years, when a case report of a man with gout who sustained an open fracture secondary to a spur was published.¹⁵ The current literature continues to be sparse, containing only a few case reports and just 1 report of surgical treatment with limited follow-up data.^{2,3,15,21} Otherwise, spurs are only mentioned when other topics, such as triceps tendonitis or olecranon bursitis, are discussed.^{6,14}

A significant amount of literature has been published on the diagnosis and management of olecranon osteophytes,^{4,9-11,13,16,17,20,22,25} and some of these manuscripts use the terms "spur" and "osteophyte" interchangeably. However, these two pathologies are not interchangeable.

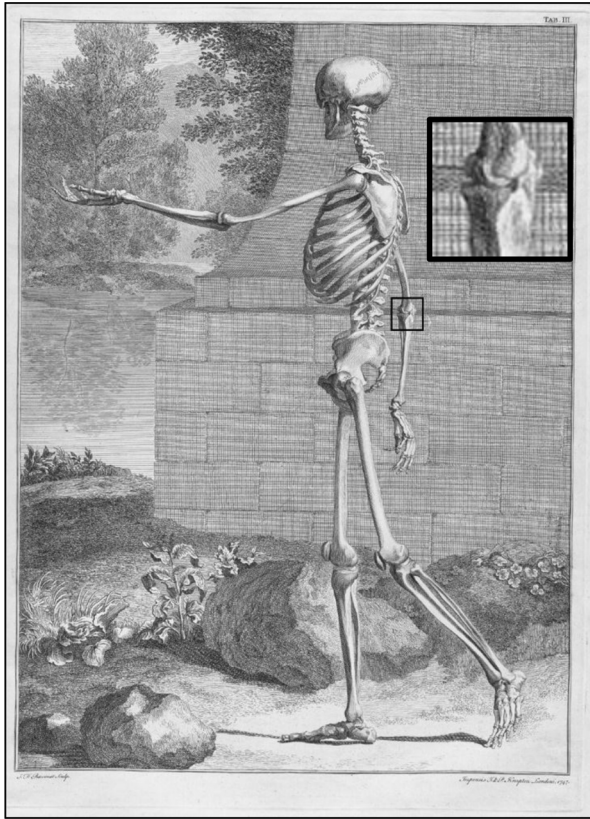


Figure 1 A small olecranon spur is seen on the right olecranon of a skeleton in Bernard Albinus' 1747 publication *Tabulae sceleti et musculorum corporis*. Image courtesy of the National Library of Medicine.

Although both are thought to be enthesophytes, they differ in their location, symptoms, diagnosis, treatment, and probably in their etiology. Therefore, differentiation and clarity in the literature is necessary.

Olecranon spurs are encountered with some frequency in the clinical setting, and the paucity of evidence-based recommendations, along with the ambiguity of terminology in the literature, has resulted in a lack of clinical guidelines for their treatment. This review presents the current knowledge about olecranon spurs.

Methods

The PubMed and Google Scholar databases were searched using the terms “olecranon spur,” “olecranon traction spur,” and “olecranon osteophyte.” The resulting articles were used to find other manuscripts pertaining to the subject.

Anatomy

Numerous studies have defined the anatomy and relationship between the olecranon and the triceps tendon. The triceps tendon serves as the primary extensor of the elbow.¹⁴ It originates about 20 cm proximal to the

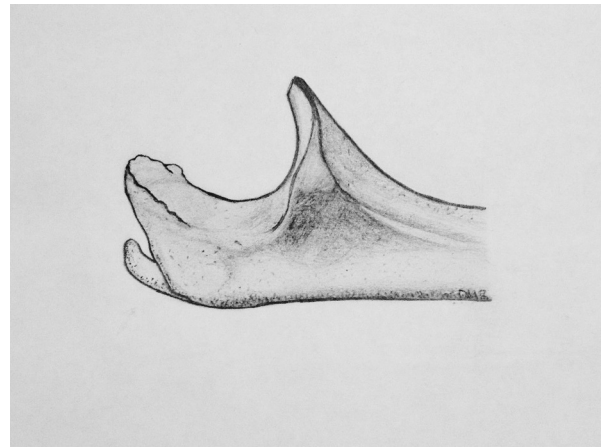


Figure 2 This illustration highlights the differing locations of olecranon spurs and osteophytes. Spurs form on the posterior olecranon at the triceps insertion, and osteophytes form along the articular margin.

olecranon tip within the muscle and divides into the triceps tendon proper and the triceps expansion. Cadaveric studies have found that about half of the specimens demonstrate a well-defined interval between the expansion and the tendon proper, which is known as the anatomic triceps decussation.¹⁴ The triceps tendon proper increases in thickness as it approaches the olecranon and inserts on the posterior 40% of the olecranon.¹⁴ The triceps expansion remains relatively thin and inserts distally and laterally through the anconeus.^{14,18} Therefore, the tendon has a very broad insertion that tends to envelop the posterior olecranon. Windisch et al²³ looked at 100 cadavers and noted that the width of the tendon was greater than that of the posterior olecranon in most specimens. Other cadaveric studies have found a similarly large footprint, which covers an average of 466 mm² of the olecranon.²⁴

Olecranon spurs form within the superficial portion of the central triceps tendon insertion and protrude posteriorly, sometimes with a slight upward curve.^{2,14} The spurs can become quite large, and 1 study found that they occupy 30% to 50% of the triceps insertion in patients with triceps tendonitis.¹⁴ This contrasts with olecranon osteophytes, which are located on the posterolateral or posteromedial articular border on the tip of the olecranon (Fig. 2).^{4,10,11,16,17,22}

Pathophysiology

Olecranon spurs are commonly seen in patients with inflammatory conditions such as triceps tendonitis, olecranon bursitis, and gout.^{14,15,21} They are also seen in patients with a history of elbow trauma, manual laborers, or people involved in recreational activities requiring repeated forceful elbow extension.^{2,3,8,12} In addition, spurs are an age-related phenomenon and can represent an incidental finding.⁵

There are no data specifically on the histology of olecranon spurs; however, spur formation at other anatomic sites has been studied. Benjamin et al⁵ histologically examined 26 different cadaveric entheses, and their results suggest that spurs are formed via a combination of endochondral, intramembranous, and chondroid ossification. They found a likely series of events leading to spur formation: Pathologic thickening of calcified fibrocartilage leads to the formation of small bony nodules, which then fuse to form macroscopic spurs.⁵ This sequence might also explain the line of radiolucency mentioned by Cimmino, because these spurs seem to form from aggregations of smaller nodules instead of growing outward from the olecranon, with sequential layers being laid down. This mechanism is consistent with most spurs being found in the superficial portions of tendinous attachments, because they are more fibrous.⁵ These findings also lend credence to the theory that enthesophytes are traction spurs forming in response to repetitive mechanical loading and micro-trauma^{2,5} and also support clinical observations that spurs are seen in patients involved in occupations or activities requiring repeated forceful elbow extension or those with triceps tendonitis, olecranon bursitis, or a history of trauma.^{2,3,8,12,14,21}

Olecranon spurs and osteophytes appear to develop over a similar time scale of months to years, not days to weeks.¹¹ However, the accepted mechanism for osteophyte formation differs significantly from the outlined hypothesis of spur formation. Posteromedial osteophytes are most commonly seen in overhead throwing athletes with valgus extension overload,^{1,4,9-11} with the core pathophysiologic event being an end arc bony abutment. The throwing motion requires a valgus torque and deceleration at the end of the motion, which produces high compression and shear forces on the posteromedial olecranon.¹ These shear and compressive forces induce osteogenesis and stimulate osteophyte formation concentrated on the posteromedial olecranon.¹ In addition, any laxity of in the ulnar collateral ligament can lead to increased compression of the medial olecranon during forced extension, thereby inducing posteromedial osteophyte formation.¹¹ Even the smallest laxity, including chronic or recurrent subclinical microtears of the ulnar collateral ligament, can lead to osteophyte formation.¹¹

Clinical presentation

Posterior midline elbow pain is universally present in patients with symptomatic olecranon spurs.² Posterior elbow pain can usually be elicited with resisted elbow extension, particularly from a beginning point of end arc flexion toward terminal extension over a range of about 130° to 100°. When the spur is fractured at presentation, pain can be experienced in all arcs of motion and especially with resisted elbow extension, presumably due to the pull of the

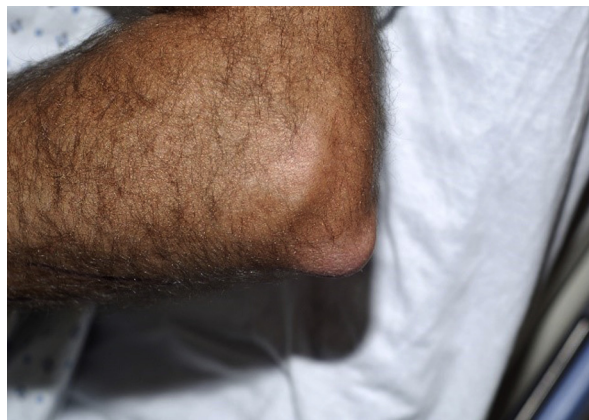

Figure 3 A preoperative photograph of a patient with a symptomatic olecranon spur. A prominent olecranon is visible with mild surrounding soft tissue edema.

triceps acting on a nonunion interface of the bony spur. Patients generally report that pain began after starting manual labor, weight lifting, or other repetitive activities. In addition, they may have a history of gout, bursitis, or trauma.^{2,3,8,12,14,21}

As mentioned, fracture through the spur, which was once thought to be a rare occurrence that was usually associated with triceps avulsion,^{3,8} can be a cause of significant pain. A more recent report of spur excision as a treatment for chronic triceps tendonitis found that 50% of patients had a fracture of the spur at operation.¹⁴ An unrecognized fracture can go on to become a painful nonunion, and associated soft tissue edema can lead to a mass effect that contributes to the posterior elbow pain. In our clinical experience, patients do not overtly display triceps weakness or deficiency; instead, they generally present with pain during resisted extension. This pain may cause decreased effort during testing, but this represents pain-inhibition, not true triceps weakness.

The subcutaneous nature of the elbow and olecranon process makes physical examination relatively straightforward.¹⁹ When an olecranon spur is present, the examination generally reveals a prominent olecranon and point tenderness, with or without edema (Fig. 3). Tenderness may also be present over the distal triceps tendon, suggestive of coexistent tendinitis. Posterior elbow pain can usually be elicited with resisted elbow extension, particularly from a flexed starting position. Flexion contractures between 10° and 20° have also been observed,² and all patients reported in the current literature have been neurovascularly intact.^{2,3,15} Decreased range of motion is a common presenting finding in patients with olecranon osteophytes.

The flexion contractures seen in olecranon osteophytes and olecranon spurs are hypothesized to have different mechanisms of formation, but both have the common final pathway of limited range of motion. The flexion contracture seen with osteophytes is secondary to the abutment of

the olecranon in the olecranon fossa, thereby forcing the patient to keep the elbow slightly flexed, which can eventually lead to a contracture.⁹ The mechanism of contracture development with olecranon spurs has yet to be definitively determined but may involve pain at terminal (resisted) extension causing a feedback loop within the joint that leads to a flexion contracture.

The examination findings of spurs also contrasts with those of olecranon osteophytes. When osteophytes are present, testing for valgus extension overload whereby the elbow is placed under valgus stress and then extended to terminal extension will result in abutment of any osteophytes against the olecranon fossa, and full extension will not be possible. The posterior grind test can also be used to demonstrate the presence of olecranon osteophytes. In this test the patient's wrist is placed on the examiner's shoulder with the arm in full pronation and extension. The examiner then applies a downward force on the elbow, exaggerating the hyperextension. If osteophytes are present, the examiner will feel them grinding against the olecranon fossa and the patient generally reports pain.

Investigations

When a symptomatic olecranon spur is suggested by history and physical examination, a lateral plain radiograph of the affected elbow is sufficient for diagnosis. However, most patients have been assessed with magnetic resonance imaging (MRI), computed tomography, or ultrasound at the time of presentation to the clinic.² MRI or ultrasound imaging is usually performed when the patient is evaluated for triceps tendonitis or olecranon bursitis because these pathologies are frequently found concomitantly with olecranon spurs.² The presence of an olecranon spur has been hypothesized to make these entities more resistant to conservative treatment and therefore more likely to require surgical intervention.^{2,7,20,21} We commonly use MRI in our practice due to the ability to interpret any associated tendinitis and nonunions in the clinic with an examinable patient in our presence. A representative radiograph is shown in [Figure 4](#).

Treatment and outcomes

All of the reported patients with symptomatic spurs have undergone at least 3 months of conservative treatment. This regimen includes nonsteroidal anti-inflammatory medications (ibuprofen, naproxen, etc), rest, activity modification (reduction of loaded elbow extension below 5 pounds), supervised physical therapy (ultrasound, cryotherapy, iontophoresis, etc), and elbow immobilization or padding or both.² This conservative therapy failed in all 11 of the reported patients; however, this was a retrospective study looking at operative outcomes, and therefore, only operative cases were reported. Other studies have shown that patients with associated conditions, such as triceps

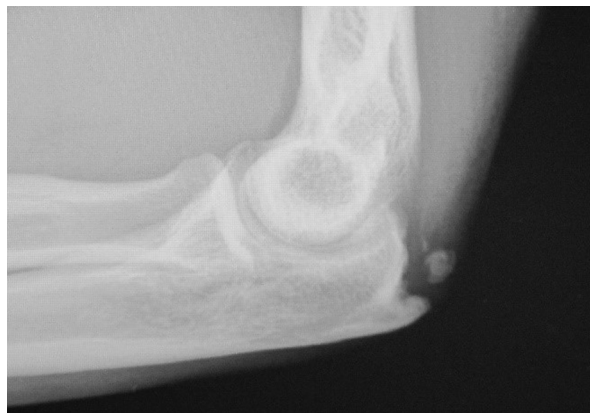

Figure 4 A lateral radiograph shows a representative olecranon spur and spur fragment.

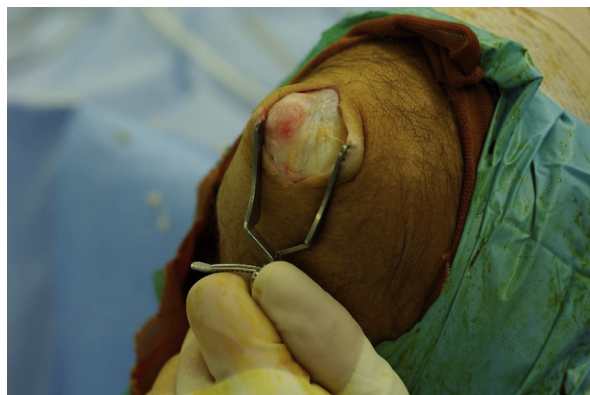

Figure 5 Skin incision and subcutaneous dissection allows the spur to be seen with fibers of the triceps tendon inserting onto and going deep to the spur.

tendonitis and olecranon bursitis, are more likely to be refractory to conservative management if a spur is present and that symptoms resolve after spur excision.^{14,21}

Operative techniques of spur excision with limited follow-up have been reported for patients undergoing spur removal because of symptomatic spurs, chronic triceps tendonitis, and chronic olecranon bursitis that were refractory to conservative treatment.^{2,14,21} General or regional anesthesia was used for all procedures. A lateral longitudinal incision was made, and a full-thickness skin flap was raised ([Fig. 5](#)). Partial or full bursectomies were performed in all patients with symptomatic spurs or recurrent triceps tendonitis in which evidence of concomitant bursitis was found at operation.^{2,14} The spur was generally covered by at least a thin layer of triceps tendon, which was incised longitudinally. The tendon was then elevated until the spur and posterior olecranon were exposed. The spur and, in some cases, a small section of normal olecranon, were removed using an osteotome, rongeur, or combination of the two ([Figs. 6-8](#)).^{2,14,21} All authors were careful to preserve the remainder of the normal distal triceps insertion.^{2,14,21} The incised tendon

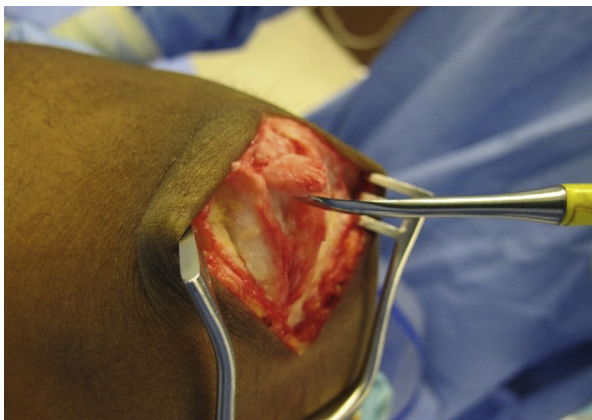


Figure 6 Intraoperative photograph showing that the triceps tendon has been elevated off the spur, preserving its distal insertion. The spur has been almost completely removed.

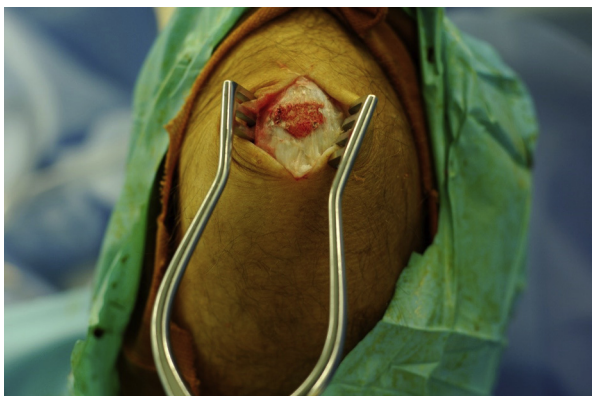

Figure 7 Intraoperative photograph showing the posterior olecranon after spur removal. The spur has been removed down to the dorsal cortex.

was not repaired in all published cases. Alvi et al² simply debrided the tendon to healthy-looking tissue in some patients, and the remaining tendons were repaired with running suture or suture anchors.^{14,21}

In our practice, the periosteum is elevated from the subcutaneous border of the spur, and this plane is progressed, with a combination of sharp scalpel dissection and blunt periosteal elevation, to the deep surface of the spur. When the deep surface is completely detached from the triceps, an osteotome is placed at the interface angle between the spur and normal olecranon. The osteotome is angled toward the normal contour of the olecranon, and the spur is removed. Any sharp edges are removed with a rongeur. We prefer to repair the tendon side-to-side or to bone, depending on the defect size that results from spur excision.

Postoperatively, patients treated for symptomatic spurs were splinted in flexion,² although we use bulky bandages in elbow extension in an attempt to reduce triceps tension for the first 2 weeks. Patients were allowed to begin range of motion exercises within 1 week of surgery, progressed to a self-directed motion and strengthening program, and were

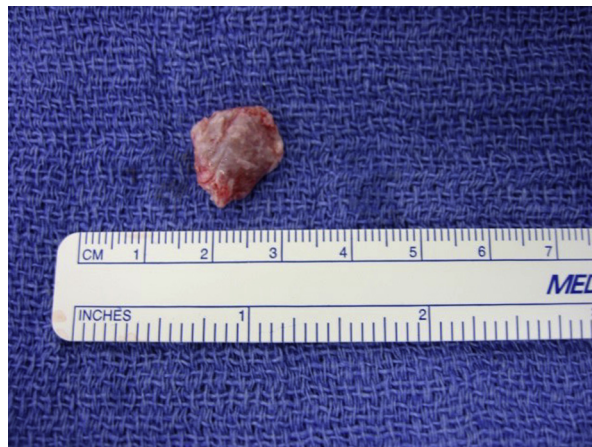


Figure 8 Typical olecranon spur after removal.

allowed to resume normal activities at 3 to 6 weeks.² Patients treated for recurrent bursitis were not splinted but instead received a compression bandage for 10 days, after which range of motion activities were begun.²¹ Those treated for triceps tendonitis had the most restrictive postoperative course and were kept in a splint or cast at 45° flexion for 3 weeks before limited range of motion exercises were started. These patients were protected from active extension until 6 weeks postoperatively, and strengthening was not commenced until 3 months.¹⁴ A summary of these techniques can be found in [Table I](#).

All 3 techniques produced good clinical outcomes with high patient satisfaction in short to midterm follow-up, and there were no major complications.^{2,14,21} Quayle and Robinson²¹ monitored their patients with serial physical examinations for a minimum of 6 months and noted only some minor tenderness or hypoesthesia of their scars. Triceps function was unaffected, even after removal of normal olecranon; however, the authors do stress the importance of preserving the triceps periosteal attachments.²¹ Alvi et al² reassessed patients an average of 34 months after spur excision. The patients were examined and assessed with the 11-item version of the Disabilities of Arm, Shoulder and Hand, and the Mayo Elbow Performance Score, and visual analog scales were used to quantify patient satisfaction and pain.² They also measured active elbow joint motion with a goniometer, tested elbow strength and categorized it using the Medical Research Council of Great Britain grading system, and judged elbow stability by applying varus and valgus stress and comparing it with the contralateral side.² Follow-up radiographs were obtained as well. At the final follow-up, all patients had normal range of motion and strength, and no instability was noted.² Jafarnia et al¹⁴ reported outcomes in competitive pitchers who had triceps tendonitis that was refractory to conservative treatment and associated with an olecranon spur. All patients were all able to return to their premorbid level of performance after spur excision.¹⁴

Table I Summary of reported operative techniques for olecranon spur excision and their outcomes

	Quayle and Robinson ²¹ (1978)	Jafarnia et al ¹⁴ (2001)	Alvi et al ² (2014)
Indication	Recurrent bursitis	Recurrent triceps tendonitis	Symptomatic olecranon spur
Patients, No.	9	9	11
Elbows, No.	11	9	12
Spurs, No.	7	9	12
Operative technique differences	<ul style="list-style-type: none"> • All bursas preserved • Spur and normal olecranon removed • Tendon repaired with running suture 	<ul style="list-style-type: none"> • Bursitis excised • Spur and normal olecranon removed • Tendon repaired with 1-2 suture anchors and running suture 	<ul style="list-style-type: none"> • Bursitis excised • Spur removed down to dorsal cortex and adequacy of resection checked with intra-op fluoroscopy • Tendon debrided or repaired with running suture
Post-op course	<ul style="list-style-type: none"> • Compression bandage for 10 days • Motion started once bandage removed 	<ul style="list-style-type: none"> • Splint or cast in 45° flexion • Active flexion and passive extension started 3 weeks post-op • Active extension started 6 weeks post-op • Strengthening started 3 months post-op 	<ul style="list-style-type: none"> • Splinted in flexion • Motion started 1 week post-op • Self-directed motion and strengthening program • Unrestricted activities at 3-6 weeks
Outcomes	<ul style="list-style-type: none"> • All had bursitis resolve • No loss of extension or strength • 2 had scar tethering • 2 had temporary hypoesthesia • 1 had slight residual tenderness 	<ul style="list-style-type: none"> • All had tendonitis resolve • No loss of extension or strength • 1 had triceps suture prominence • 1 had persistent pain without discrete clinical findings 	<ul style="list-style-type: none"> • High patient satisfaction and improved symptoms • No loss of extension or strength • 1 had post-op seroma, that resolved with aspirations • 1 had olecranon bursitis that resolved with compression • 1 required return to operating room for prominent suture material in triceps tendon • 2 had recurrent spurs, one of which was symptomatic and required reoperation
Follow-up	Range: 0.5-6 years Average: 3 years	Not stated	Range: 10-78 months Average: 34 months

Patients treated for symptomatic spurs did not undergo resection of normal olecranon, their spurs were removed down to the distal cortex, and adequacy of the bone removal was checked with intraoperative fluoroscopy.² However, in patients who underwent surgical treatment for recurrent bursitis and triceps tendonitis, a portion of normal olecranon bone was removed in addition to the spur.^{2,14,21} In our experience, this is often necessary in those with a prominent olecranon process (usually normal for that particular person bilaterally) to decrease the contour and prevent a future recurrence due to continued prominence irritation. This removal of nonpathologic bone did not seem to affect functional outcomes because there was no loss of extension, strength, or joint stability in any of the patients.^{2,14,21}

Preservation of normal joint stability, despite the removal of normal olecranon, contrasts with the treatment of olecranon osteophytes, in which removal of only abnormal bone is recommended.^{16,17} Excision of normal olecranon, at the articular cartilage edge, has been shown to

increase strain on the stabilizing ligaments, which may lead to further injury requiring operative repair.^{1,16,17} This aspect highlights the importance of correct nomenclature, between an olecranon spur (distant from the chondral margin) and an olecranon osteophyte (adjacent to the chondral margin). Two patients treated for symptomatic spurs, who therefore did not have excision of normal olecranon, did have recurrence of the spur. Only one of the recurrent spurs was symptomatic and was re-excised.² Patients in whom normal olecranon was removed did not experience recurrent symptoms in similar lengths of follow-up. Whether their spurs recurred is unknown because follow-up radiographs were not included in these studies.

Discussion

Olecranon spurs are an established pathology that has only recently received attention in the clinical literature. The

current literature represents a small number of patients and selects only those who have required surgical intervention. Therefore, whether an adequate conservative treatment regimen exists or whether all symptomatic spurs require excision has yet to be determined, although our clinical experience suggests that conservative treatment can be sufficient. The current literature supports that spur excision, which includes removal of normal olecranon, does not affect functional outcomes. Spur recurrence has been reported when only pathologic bone is excised; however, the number of patients studied is far too small to draw any definitive conclusions on whether removing normal olecranon is a superior technique resulting in less recurrence. Further comparative studies between these methods are needed. In addition, the mechanism of spur formation has not yet been elucidated in the current literature. Understanding their formation may provide insight into future treatments not only for olecranon spurs but also at other entheses.

Most patients with symptomatic spurs who present to our orthopedic upper extremity clinic can be adequately treated with nonoperative measures, notably, activity modification, nonsteroidal anti-inflammatory medications, padded elbow braces, and physical therapy. However, some refractory cases that require surgical intervention continue to cause unacceptable symptoms for the patient. A surgical solution that we most commonly use is a 4-cm posterior incision just lateral to the midline and centered over the most prominent aspect of the spur. Most frequently, we have noted that the triceps has attachments to the deep aspect of the spur and that these are elevated for spur removal, which is removed with an osteotome or rongeur, although occasionally the spur is already broken at presentation. Our practice is to remove the spur down to the original cortex and not remove any normal olecranon. Similar to the practice of Alvi et al,² triceps tendon repair is a clinical decision determined by the size of the defect left by spur removal.² Large defects are repaired with a running suture through bone tunnels, using a No.2 gauge nonabsorbable braided suture. As with the reported patients, our patients have done well postoperatively, are satisfied with their outcomes, and do not have any triceps weakness or functional disabilities. In addition, the patients in our practice have not had any recurrence of symptomatic spurs.

Conclusions

Olecranon spurs are a relatively common pathology with very scant representation in the literature. The mechanism of their formation has not been confirmed but seems to be similar to that of spurs at other entheses. Three methods of spur resection are reported in the current literature, and all have good outcomes. Our clinical experience is that most spurs can be treated with

conservative measures but that patients who do require an operative intervention have satisfactory results, and none have had any recurrence of symptoms.

Disclaimer

The authors, their immediate families, and any research foundations with which they are affiliated have not received any financial payments or other benefits from any commercial entity related to the subject of this article.

References

1. Ahmad CS, Conway JE. Elbow arthroscopy: valgus extension overload. *Instr Course Lect* 2011;60:191-7.
2. Alvi HM, Kalainov DM, Biswas D, Soneru AP, Cohen MS. Surgical management of symptomatic olecranon traction spurs. *Orthop J Sports Med* 2014;2:1-5. <http://dx.doi.org/10.1177/2325967114542775>
3. Amako M, Arino H, Nemoto K. Subcutaneous rupture of the triceps tendon with avulsion fracture of the olecranon spur. *J Hand Surg Eur Vol* 2012;37:71-2. <http://dx.doi.org/10.1177/1753193411421718>
4. Andrews JR, Timmerman LA. Outcome of elbow surgery in professional baseball players. *Am J Sports Med* 1995;23:407-13.
5. Benjamin M, Toumi H, Suzuki D, Hayashi K, McGonagle D. Evidence for a distinctive pattern of bone formation in enthesophytes. *Ann Rheum Dis* 2009;68:1003-10. <http://dx.doi.org/10.1136/ard.2008.091074>
6. Blackwell JR, Hay BA, Bolt AM, Hay SM. Olecranon bursitis: a systematic overview. *Shoulder Elbow* 2014;6:182-90. <http://dx.doi.org/10.1177/1758573214532787>
7. Canoso JJ. Idiopathic or traumatic olecranon bursitis. Clinical features and bursal fluid analysis. *Arthritis Rheum* 1977;20:1213-6.
8. Cimmino CV. The olecranon spur and its fracture. *Radiology* 1969;92:1305.
9. Cohen SB, Valko C, Zoga A, Dodson CC, Ciccotti MG. Posteromedial elbow impingement: magnetic resonance imaging findings in overhead throwing athletes and results of arthroscopic treatment. *Arthroscopy* 2011;27:1364-70. <http://dx.doi.org/10.1016/j.arthro.2011.06.012>
10. David TS. Medial elbow pain in the throwing athlete. *Orthopedics* 2003;26:94-103. <http://dx.doi.org/10.3928/0147-7447-20030101-25>. quiz 104-105.
11. Dugas JR. Valgus extension overload: diagnosis and treatment. *Clin Sports Med* 2010;29:645-54. <http://dx.doi.org/10.1016/j.csm.2010.07.001>
12. Gabel GT. Acute and chronic tendinopathies at the elbow. *Curr Opin Rheumatol* 1999;11:138-43.
13. Inagaki K. Current concepts of elbow-joint disorders and their treatment. *J Orthop Sci* 2013;18:1-7. <http://dx.doi.org/10.1007/s00776-012-0333-6>
14. Jafarnia K, Gabel GT, Morrey BF. Triceps tendinitis. *Oper Techn Sport Med* 2001;9:217-21.
15. Kakel R, Tumilty J. Open fracture as a rare complication of olecranon enthesophyte in a patient with gout. *Am J Orthop (Belle Mead NJ)* 2011;40:E52-6.
16. Kamineni S, ElAttrache NS, O'Driscoll SW, Ahmad CS, Hirohara H, Neale PG, et al. Medial collateral ligament strain with partial posteromedial olecranon resection. A biomechanical study. *J Bone Joint Surg Am* 2004;86-A:2424-30.

17. Kamineni S, Hirahara H, Pomianowski S, Neale PG, O'Driscoll SW, ElAttrache N, et al. Partial posteromedial olecranon resection: a kinematic study. *J Bone Joint Surg Am* 2003;85-A:1005-11.
18. Morrey BF. Anatomy of the elbow joint. In: Morrey BF, Sanchez-Sotelo J, editors. *The elbow and its disorders*. 4th ed. Philadelphia, PA: Saunders Elsevier; 2009. p. 11-38. ISBN 978-1-4160-2902-1.
19. Morrey BF, Regan WD. Physical examination of the elbow. In: Morrey BF, Sanchez-Sotelo J, editors. *The elbow and its disorders*. 4th ed. Philadelphia, PA: Saunders Elsevier; 2009. p. 67-79. ISBN 978-1-4160-2902-1.
20. Paterson J, Roper B. Olecranon spur. *J Hand Surg Br* 1993;18:9-10.
21. Quayle JB, Robinson MP. A useful procedure in the treatment of chronic olecranon bursitis. *Injury* 1978;9:299-302.
22. Valkering KP, van der Hoeven H, Pijnenburg BC. Posterolateral elbow impingement in professional boxers. *Am J Sports Med* 2008;36:328-32. <http://dx.doi.org/10.1177/0363546507308937>
23. Windisch G, Tesch NP, Grechenig W, Peicha G. The triceps brachii muscle and its insertion on the olecranon. *Med Sci Monit* 2006;12:Br290-4.
24. Yeh PC, Stephens KT, Solovyova O, Obopilwe E, Smart LR, Mazzocca AD, et al. The distal triceps tendon footprint and a biomechanical analysis of 3 repair techniques. *Am J Sports Med* 2010;38:1025-33. <http://dx.doi.org/10.1177/0363546509358319>
25. Yeoh KM, King GJ, Faber KJ, Glazebrook MA, Athwal GS. Evidence-based indications for elbow arthroscopy. *Arthroscopy* 2012;28:272-82. <http://dx.doi.org/10.1016/j.arthro.2011.10.007>