

Review Article

History of elbow arthroscopy

Karis Bennett¹, Srinath Kamineni²

Department of ¹Orthopaedics and ²Orthopaedic Surgery, University of Kentucky, Lexington, Kentucky, United States.



***Corresponding author:**

Srinath Kamineni,
Department of Orthopaedic
Surgery, University of
Kentucky, 740 S. Limestone,
Lexington - 40536,
Kentucky, United States.

srinathkamineni@gmail.com

Received : 03 May 2020

Accepted : 03 May 2020

Published :

DOI

10.25259/JASSM_7_2020

Quick Response Code:



ABSTRACT

Elbow arthroscopy is a minimally invasive surgical technique used to diagnose and treat elbow joint pathologies and is now one of the most commonly performed orthopedic elbow procedures. Although the technique of arthroscopy emerged more than a century ago, elbow arthroscopy has only significantly advanced since the 1980s. With the early dominance of knee arthroscopy, many of the early developments in elbow arthroscopy were influenced by that knowledge, with some degree of ongoing cross pollination of ideas. However, many of the steps in the evolution of elbow arthroscopy were unique to the elbow joint, independent of those taking place in other joints. This article presents the evolution of elbow arthroscopy, as well as, predictions for the future of this surgical technique.

Keywords: Orthopedic, History, Elbow, Arthroscopy

INTRODUCTION

Arthroscopy was first introduced as a diagnostic tool and has subsequently evolved into a therapeutic modality, used to treat a wide range of joint pathologies. The earliest arthroscopy reported was performed in 1912 by Dr. Severin Nordentoft [Figure 1], a Danish orthopedic surgeon from Aarhus, Denmark 1866 to 1922.^[1] He examined the inside of the knee joint with a “Trocart-Endoscope” which he constructed using a 5 mm trocar, a fluid valve, and an optic tube. He presented a vivid description of the knee joint, stating that endoscopy can be utilized to detect early meniscal lesions and laparoscopy, at the 41st Congress of the German Society of Surgeons in 1912.^[1] In 1919, Professor Kenji Takagi [Figure 2], a Japanese orthopedic surgeon from Tokyo, Japan 1888 to 1963, performed his first arthroscopy to examine tuberculous knees, using the cystoscope he produced, which measured 7.3 mm.^[1,2] Professor Takagi also produced the first purpose-specific arthroscope in 1931, called the no. 1 Takagi scope and measuring 3.5 mm [Figure 3].^[1-3] In 1931, interest in elbow arthroscopy began, but this interest was halted by Dr. Michael Burman’s report in 1931, which stated that the “needle” was too large for the limited elbow joint space and therefore “unsuitable” for examination with an arthroscope.^[4] Dr. Burman [Figure 4] was an American orthopedic surgeon from New York City 1901–1975.^[1]

Over the next 40 years, the size of the arthroscope decreased. By 1971, a 1.7 mm arthroscope was produced by Dr. Masaki Watanabe [Figure 5], a Japanese orthopedic surgeon from Nagano, Japan 1911 to 1995, which sparked renewed interest in elbow arthroscopy.^[1,4] While the 1.7 mm arthroscope allowed for a resurgence of interest in elbow arthroscopy, the most common arthroscope used in current practice is the 3.5 mm scope that was deemed unsuitable in the 1930s.

This is an open-access article distributed under the terms of the Creative Commons Attribution-Non Commercial-Share Alike 4.0 License, which allows others to remix, tweak, and build upon the work non-commercially, as long as the author is credited and the new creations are licensed under the identical terms.

©2020 Published by Scientific Scholar on behalf of Journal of Arthroscopic Surgery and Sports Medicine




Figure 1: Pictured is Dr. Severin Nordentoft (1866–1922). This image was obtained from Jackson, 2003.



Figure 4: Pictured is Dr. Michael Burman (1901–1975). This image was obtained from Jackson, 2003.



Figure 2: Pictured is Professor Kenji Takagi (1888–1963). This image was obtained from Jackson, 2003.



Figure 5: Pictured is Dr. Masaki Watanabe (1921–1994). This image was obtained from Jackson, 2003.

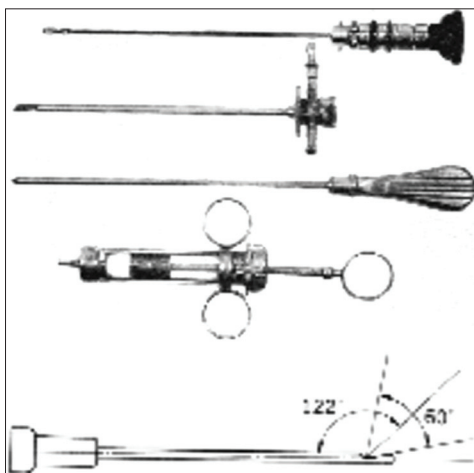


Figure 3: In 1931, the Takagi no. 1 arthroscope was produced. This image was obtained from Macgrill *et al.*, 2017.

POSITIONING

Since 1985, when elbow arthroscopy started to gain popularity, there have been many modifications to patient positioning during the procedure. Initially, patients were positioned supine with their arm suspended above their head, in 90° of shoulder abduction, neutral forearm rotation, and 90° of elbow flexion [Figure 6a].^[4,5] This was not ideal for the surgeon because the patient's arm was not stable and would swing like a pendulum. Furthermore, the position restricted the surgeon's view of the posterior aspect of the elbow joint. This positioning was also not ideal for the procedure, since gravity would cause the neurovascular structures and the joint space to become closer in proximity, placing the patient at a higher risk of iatrogenic injury. This position was considered the standard or "hanging supine position."^[5] It was later modified to the "supine-suspended position," which

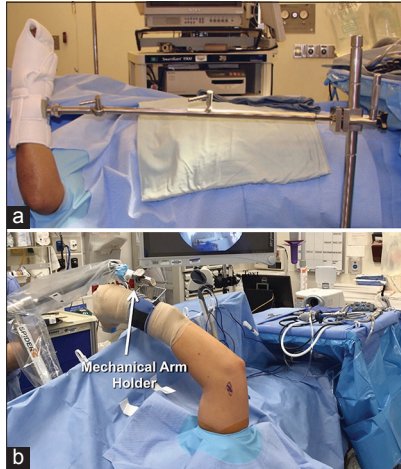


Figure 6: (a) The patient is in the supine position with the right elbow visible. This image was obtained from Merrell and DaSilva, 2009. (b) The patient is in supine-suspended position with the right elbow visible. This image was obtained from Camp *et al.*, 2016.

is still used for elbow arthroscopy, although less common [Figure 6b].^[5] In this position, the patient is supine and the arm, which is in a mechanical arm holder, is adducted across the body with the elbow flexed 45° and the shoulder rotated internally 90° and forward flexed 90°. The advantages of this position include optimal access for airway management, easy conversion to open surgery if needed, increased access to the anterior and posterior compartments of the elbow, and free positioning of the limb in space. The disadvantages are that the arm may feel unstable if not properly secured and positioned, a mechanical traction device is needed, and some surgeons report that the arthroscopic orientation is challenging to maneuver without significant experience.^[5]

In 1989, Gary Poehling, an American surgeon from North Carolina USA, introduced the prone position [Figure 7a].^[4-7] This position consists of the patient's arm rested on a padded bolster in 90° of shoulder abduction and neutral rotation, which allows the joint fluid to distend the anterior capsule.^[5] The advantage of the prone position is that the surgeon has a stable view of the anterior and posterior compartments of the elbow during arthroscopy. The major disadvantage of this position is that the anesthesiologist has considerable difficulty with accessing and managing the patient's airway, and hence is rarely utilized in current practice.

While the prone- and supine-suspended positions are rarely utilized, the lateral decubitus position has become the most popular position used for elbow arthroscopies since 1992 [Figure 7b].^[4-6] In this position, the patient's arm is supported and stabilized over a padded bolster, the shoulder is internally rotated and abducted to 90°, and the elbow is at 90° of flexion.^[5] This allows access to the posterior and anterior compartments of the elbow, and manipulation of the joint during the surgery, as needed. Other advantages of this

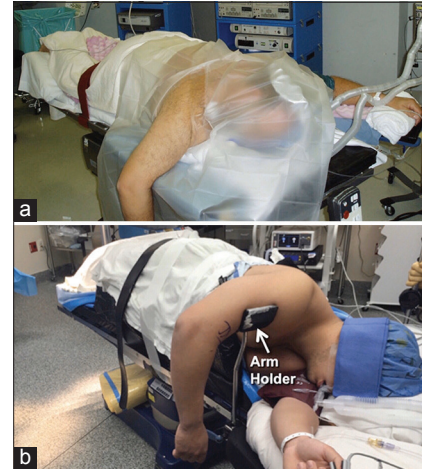

Figure 7: (a) The patient is in the prone position with the right elbow visible. This image was obtained from Stetson *et al.*, 2018. (b) The patient is in the lateral decubitus position. This image was obtained from Camp *et al.*, 2016.

position are that the anesthesiologist can manage the patient's airway with greater ease than in the prone position, and an arm positioning mechanical device is not necessary, as in the case of the supine-suspended position.^[5] A disadvantage of this position is that the patient's airway is less exposed as in the supine-suspended position.^[5,6] The lateral decubitus position currently represents the best compromise between surgical procedure and anesthetic airway access.

PORTALS

Correct portal placement is crucial during elbow arthroscopy to correctly access the working space while minimizing the risk of neurovascular damage. Throughout the early 1970s, the arthroscopic anatomy of the elbow and the indications for elbow arthroscopy were vigorously researched and later published in a report by Dr. K Ito in 1979.^[4] In 1985, Andrews and Carson first described a way to help ensure this by identifying and outlining anatomical and neurovascular structures, such as the medial and lateral epicondyles, the olecranon, the radiocapitellar joint, and the ulnar nerve [Figure 8], through palpation before joint distension.^[8] Portal establishment using the outside-in and inside-out techniques has both been surgically explored, but ultimately the outside-in technique has become the preferred method, for most portals.^[5]

Andrews' and Carson's 1985 article titled "Arthroscopy of the Elbow" was the first *in vivo* elbow arthroscopy publication to describe the anterolateral, anteromedial, and posterolateral portals (PLP), all of which are still in common use today.^[8] There have been many portals utilized for elbow arthroscopy, but there are nine standard portals that are still regularly used [Figure 9a-c].^[9] In 1989, Poehling *et al.* first described the

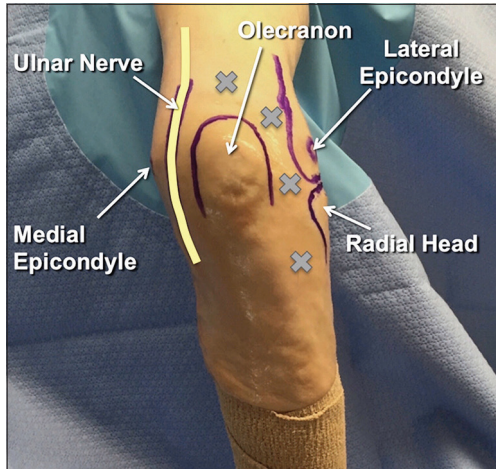


Figure 8: Anatomical landmarks, such as the medial epicondyle, ulnar nerve, olecranon, lateral epicondyle, and radial head, are outlined before surgical incision. This image was obtained from Camp *et al.*, 2016.

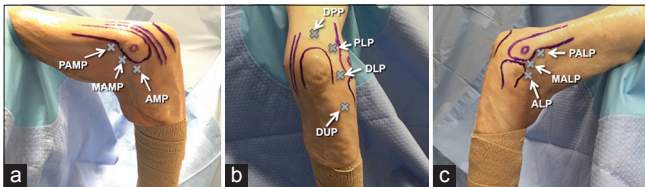


Figure 9: The patient is positioned in lateral decubitus and the right elbow is visible. (a) From the medial side, the proximal anteromedial portal, mid-ant anteromedial portal, and anteromedial portal are accessible. (b) From the posterior side, the distal posterior portal, posterolateral portal, distal lateral portal, and distal ulnar portal are accessible. (c) From the lateral side, the proximal anterolateral portal, mid-ant anterolateral portal, and anterolateral portal are accessible. This image was obtained from Camp *et al.*, 2016.

proximal anteromedial portal (PAMP), which is located 2 cm proximal to the medial epicondyle and provides access to the anterior compartment of the elbow joint.^[4,10] It is considered an auxillary portal and has a low risk of neurovascular damage.^[4,10] Another auxillary portal is the anteromedial portal (AMP), which is located 2 cm anterior and 2 cm distal to the medial epicondyle and provides a view of the anterior compartment from the medial side.^[10] The mid-AMP was initially described in 1990 by Lindenfeld as a modification to the PAMP.^[4,9] It is largely redundant because of its location, which is 1 cm anterior and 1 cm proximal to the medial epicondyle, placing it very close to the PAMP and AMP.^[9]

The anterolateral portal (ALP), which is located just proximal and 1 cm anterior to the radiocapitellar joint, provides access to the anterior compartment, along with excellent visualization of the medial structures.^[9,10] This portal was one of the first elbow arthroscopy portals described, but has since lost popularity due to the portal's close proximity to

the radial nerve.^[9,10] Today, many surgeons prefer to move this portal more proximal to lessen the risk of damaging the radial nerve, and if shifted proximal enough to where it is just anterior to the radiocapitellar joint, this location is technically considered the mid-ALP (MALP).^[9] The MALP was described in 1994 by Field *et al.* and is considered to be safer than the ALP.^[9] Another commonly used portal is the proximal ALP, which is located anterior to the humerus and 2 cm proximal to the lateral epicondyle.^[4,9] It was first described in 1995 by Stothers *et al.* and is considered to be the safest lateral portal.^[9] As the anatomy of the elbow is better understood now, the more proximal ALPs are preferred over the ALP because they are generally safer and greater visualization of the elbow joint is achievable.^[9]

The first standard posterior portal described was the PLP, which is located lateral to the borders of the triceps tendon and 3 cm proximal to the olecranon tip.^[4,10] To visualize the lateral side of the elbow better, some surgeons now elect to use a direct posterior portal (DPP) along with the “working” PLP.^[4,9,10] The DPP is located 2 cm medial to the PLP and 3 cm proximal to the olecranon tip.^[10] Finally, the direct lateral portal is a commonly used portal and is the first portal established during elbow arthroscopy, as the elbow is initially distended through the use of this portal.^[10] The portal is located in the middle of the triangle formed by the olecranon tip, the radial head, and the lateral epicondyle and gives the surgeon access to the posterior compartment of the elbow joint.^[10]

When elbow arthroscopy first began, only one or two portals were used during each procedure.^[5] As the indications of elbow arthroscopy have increased and became more complex, surgeons are now utilizing several portals for each procedure, with new portals for better procedure-specific visualization. For example, in 2011, the distal ulnar portal (DUP) was first described by Van Den Ende *et al.* and is located 3 cm distal to the radiocapitellar joint [Figure 9b].^[9,11] This portal was created for use in treating osteochondral lesions of the distal and posterior capitellum.^[9,11]

INSTRUMENTS

Since knee and shoulder arthroscopy became popular decades before elbow arthroscopy, many of the surgical instruments for elbow arthroscopy were borrowed from these established arthroscopy techniques. For example, the standard instruments for elbow arthroscopy include 30° and 70° arthroscopes, fiber optic wires, non-vented and interchangeable cannulae, and conical or blunt-tipped trocars [Figure 10a and b].^[4,10,12-14] Depending on the specific procedure, an arthroscopic probe and a variety of punches, graspers, switching sticks, motorized shavers, and scissors may be needed [Figure 11 a and b].^[4,10,12-14] The standard instrument set has not changed much since elbow arthroscopy began, but these tools have evolved and been refined.

Invented in 1958, the Watanabe no. 21 arthroscope [Figure 12] was the first production model arthroscope, but the incandescent light bulb would occasionally shatter, which was very problematic especially if this occurred during a procedure.^[15] In 1954 and 1960, Professor Harold Hopkins, a British physicist from Leicester, East Midlands 1918 to 1994, developed cold light fiber optics and the optical rod lens system, respectively, which provided a solution to the breakage of the incandescent light bulb.^[15] By 1967, the Watanabe no. 22 was produced as the first arthroscope with cold light fiber optics.^[15] The implementation of fiber optics into arthroscopy not only reduced the risk of bulbs shattering but also improved visualization.




Figure 10: Above are some of the standard arthroscopic instruments for the elbow. (a) A non-vented cannula is pictured on the left side and a conical, blunt-tipped trocar is on the right side. This image was obtained from Budge and Armstrong, 2009. (b) The 4.0 mm arthroscope and the 2.7 mm arthroscope, as well as, the interchangeable cannula systems are pictured. This image was obtained from Baker and Jones, 1999.

An important aspect of a standard arthroscope utilized for elbow arthroscopy is a 30° angled view [Figure 13].^[13] In the late 1970s, the 30° arthroscope was invented by Harold Eikelaar and the Storz company (Tuttlingen, Germany), before which was a straight view.^[16] The 30° arthroscope became quickly popular, as it provided an adequate view of the joint without distortion. Since 1985, the 4.0 mm 30° arthroscope has become the standard for accessing the anterior and posterior compartments of the elbow joint, with the less common use of the 2.7 mm arthroscope.^[4]

Accessory instruments have also been refined since their introduction, with the major themes dictating change being ease of use and risk of infection. In 1976, Dr. Lanny Johnson, an American orthopedic surgeon from Michigan, developed the motorized arthroscopic shaver.^[15] This instrument is useful for arthroscopic debridement and features disposable,




Figure 12: In 1958, the Watanabe no. 21 was invented. This image was obtained from Goebel and Madry, 2016.

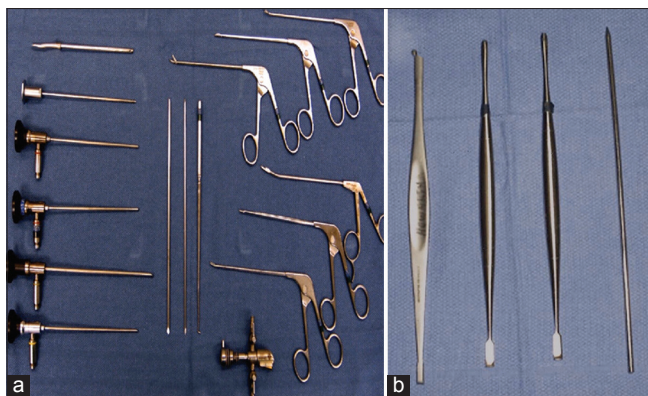

Figure 11: Accessory instruments for elbow arthroscopy are provided above. (a) A variety of arthroscopic accessory instruments are pictured. This image was obtained from Budge and Armstrong, 2009. (b) Pictured is one blunt Steinmann pin and three Howarth retractors. This image was obtained from Steinmann, 2003.




Figure 13: The 30° and 70° angled arthroscopes are considered standard instruments used for arthroscopy. This image was obtained from Budge and Armstrong, 2009.

single-use blades [Figure 14].^[17] Although more costly, disposable surgical instruments are believed to reduce the risk of iatrogenic disease transmission. One of the first disposable surgical instruments was the disposable surgical knife, which was introduced in the late 1920s, and disposable cannulae have been used since the 1980s.^[18,19] In 1994, the first disposable arthroscope was introduced and used in a cadaver study by Vangness *et al.*^[20] In 2017, Chen *et al.* stated that 75% of arthroscopic instruments are single-use and disposable, although this is contentious.^[19]

In the mid-1990s, arthroscopic radiofrequency instruments were introduced to both coagulate bleeding vessels and to cut soft tissues.^[21] They have evolved to the current standard of fluid temperature monitoring, alerts for chondroprotection, and settings to minimize cartilage penetration. Camera quality and video implementation have also come a long way in the world of arthroscopy. Surgeons initially used an eyepiece arthroscope [Figure 15a] until the mid-1980s, when video-arthroscopy started becoming standard in hospitals [Figure 15b].^[22] The video quality improved in 1993, when high-definition camera arthroscopes were introduced to arthroscopy.^[23]

In 2001, Kelly and O'Driscoll introduced the use of retractors [Figure 11b] through accessory portals to displace “at-risk” structures away from motorized shavers, to improve visualization and reduce neurovascular injury risk.^[12,24] In addition, in 2018, the use of small, handheld osteotomes [Figure 16] through standard portal cannulas for removal of elbow osteophytes was thoroughly described by Greer *et al.*^[25] The use of osteotomes has been well-documented and used for open procedures for many years, but this specific use of osteotomes has not been well-described in the literature, as arthroscopic burrs and shavers are most commonly used for elbow osteophyte removal.^[25]

To maintain joint distension throughout arthroscopic procedures, a fluid pump system is used, and there are generally two mechanisms for pump systems: Gravity flow and automated systems. The gravity flow system was described first and is still commonly used, while the automated pump system was introduced in the 1970s and is still evolving.^[26] Recently, an automated pump system, called the dual system, has been drawing interest.^[26] This system maintains pressure within the joint by controlling inflow and outflow independently, while the gravity flow system simply uses gravity to maintain the inflow, as a bag of fluid is placed 3 to 6 ft above the joint.^[26] Both systems are utilized for arthroscopy, as surgeons often prefer one over the other.

INDICATIONS

Although elbow arthroscopy is utilized for many therapeutic indications today, originally it was primarily used as a diagnostic tool.^[4] In 1985, Andrews and Carson introduced




Figure 14: Pictured is a motorized shaver with disposable blade tips. This image was obtained from Liang *et al.*, 2020.

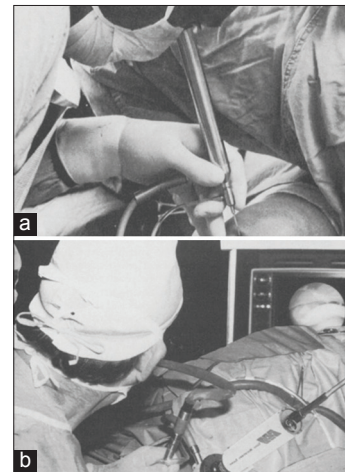


Figure 15: (a) In the mid-1970s, eyepiece arthroscopes were utilized. This image was obtained from Ike, 1996. (b) In the mid-1980s, video-arthroscopy was invented so surgeons could utilize a monitor instead of an eyepiece to see the joint. This image was obtained from Ike, 1996.

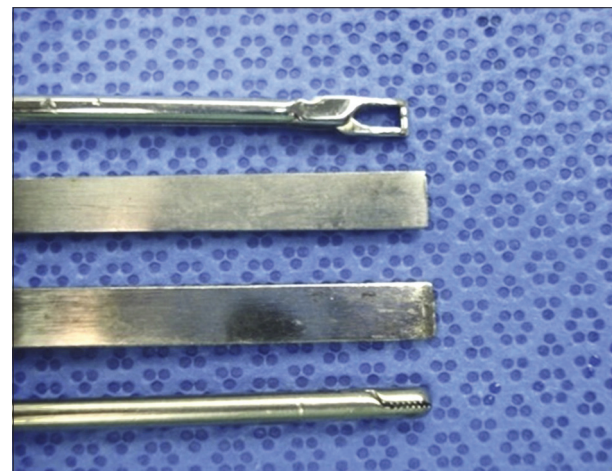


Figure 16: From top to bottom: Arthroscopic suture grasper, straight ¼” osteotome, curved ¼” osteotome, and arthroscopic grasper. This image was obtained from Greer *et al.*, 2018.

the removal of loose bodies as one of the first therapeutic indications of elbow arthroscopy.^[8] Similarly, O'Driscoll

and Morrey described many diagnostic indications of elbow arthroscopy in 1992, including the assessment of chronic elbow pain from an undetermined cause and examination of unexplained elbow contractures.^[27] Other early indications of elbow arthroscopy include synovectomy, debridement of degenerate joints, capsular release of elbow contractures, lavage of septic arthritis, excision of osteophytes, and treatment of osteochondral lesions.^[4,13,28]

With further progress of arthroscopic techniques and advancements of surgical tools, the indications of elbow arthroscopy shifted more toward therapeutics, increasing the number, and complexity of the indications. In 1995, Grifka *et al.* described the arthroscopic treatment of lateral epicondylitis as a new indication.^[29,30] In 1994, arthroscopic radial head excision was introduced, and in 2001, Menth-Chiari *et al.* expanded on this indication, describing the combined use of arthroscopic radial head excision with synovectomy for the treatment of post-traumatic arthritis and rheumatoid arthritis.^[31,32]

The complexity of elbow arthroscopy indications has expanded even further as the knowledge on arthroscopic anatomy has flourished and the indications have been refined. For example, in 2007, Tresbe *et al.* introduced the use of elbow arthroscopy for the removal of osteoid osteomas of the radial head.^[33] Furthermore, in 2006, Eames and Bain first described the repair of a partial distal biceps tendon tear, and in 2016, Bhatia further explored this indication, ultimately introducing the use of arthroscopic repair for acute and chronic retracted distal biceps tendon ruptures.^[34,35]

TODAY'S CUTTING EDGE

Elbow arthroscopy is evolving rapidly, and a few techniques that are currently on the cutting edge are dry arthroscopy, pediatric arthroscopy of the elbow, and arthroscopic lateral collateral ligament repair. Dry elbow arthroscopy was first described in 2015 and has provided a different perspective on elbow arthroscopy, as this technique causes less swelling/soft-tissue insufflation, provides better depth of vision inside the joint, and has comparable indications to that of standard elbow arthroscopy.^[36,37] Dry arthroscopy of the wrist is becoming increasingly popular, and dry elbow arthroscopy appears to be on a similar trajectory with reports of distal biceps tendon repairs and ulnar nerve explorations, releases, and transpositions using this technique recently being published in the literature.^[36,38,39] Indications for pediatric elbow arthroscopy have also been expanding recently. Specifically, there has been an increasing number of cases regarding arthroscopically-assisted treatments of pediatric elbow fractures in the literature, as well as retrospective case studies to demonstrate the efficacy of these procedures.^[38,40] Furthermore, introduced in 2010 by Savoie *et al.*, arthroscopic lateral collateral ligament repair

is on the cutting edge of elbow arthroscopy, as there are a growing number of studies being published reporting comparable results between this technique and open surgical technique.^[41,42]

FUTURE OF ELBOW ARTHROSCOPY

Recently, there has been great interest in the application of elbow arthroscopy to treat extra-articular pathologies.^[43,44] Reports of treating distal biceps tendon tears, an olecranon bursitis, and triceps tendon tears with elbow arthroscopy have been published, and there is now curiosity in using elbow arthroscopy to perform medial ulnar collateral ligament reconstruction.^[34,45,46] Kamineni *et al.* introduced the treatment of a high grade capsular contracture, with an extra-articular arthroscopic approach, which is currently considered an advanced technique for proficient arthroscopist.^[47] Interest in treating various intra-articular pathologies using elbow arthroscopy has also been increasing. Specifically, treatment of distal humerus, olecranon, and radial head fractures, tumor removal, and nerve-related pathology treatment are all being explored.^[39,43,44] In July 2019, the Food and Drug Administration approved Integrated Endoscopy Incorporated's (Irvine, California, USA) high definition, battery-operated, single use arthroscope for pilot launch in the United States [Figure 17].^[48] Advances in technology, such as surgical instrumentation, artificial intelligence, virtual reality, navigation systems, and robotics, will also help surgeons expand the uses of elbow arthroscopy and the knowledge of the elbow's neurovascular and pathoanatomy.

Open surgery will always be an important surgical technique. However, the pathologies treatable by elbow arthroscopy will continue to expand, as instruments, knowledge of surgical anatomy, and surgical techniques advance [Figure 18]. Arthroscopy will continue to be the preferred technique for an expanding list of surgical indications due to its lower risk of complications, decreased level of iatrogenic tissue injury, and decreased recovery time.

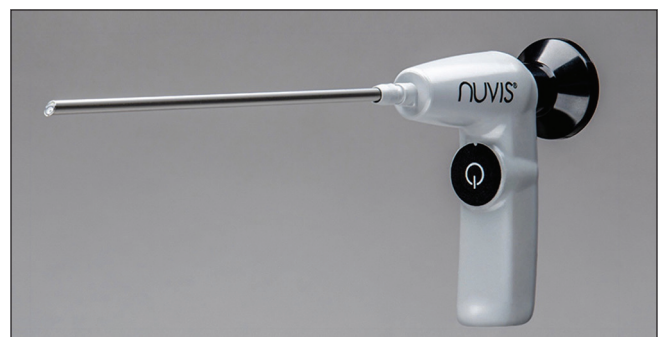

Figure 17: Pictured is integrated endoscopy incorporated's single-use, high definition, battery-operated arthroscope. This image was obtained from Integrated Endoscopy, 2019.

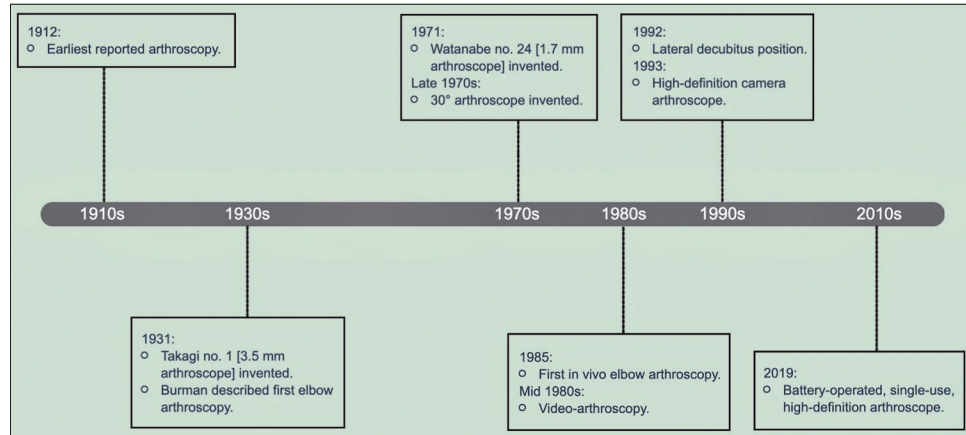


Figure 18: Above is a timeline of the major developments in elbow arthroscopy.

Declaration of patient consent

The authors certify that they have obtained all appropriate patient consent.

Financial support and sponsorship

Nil.

Conflicts of interest

There are no conflict of interest.

REFERENCES

- Jackson RW. History of arthroscopy. In: McGinty JB, Burkhart SS, editors. *Operative Arthroscopy*. 3rd ed. Philadelphia, PA: Lippincott Williams & Wilkins; 2003. p. 3-8.
- Jackson RW. From the scalpel to the scope: The history of arthroscopy. *Baylor Univ Med Cent Proc* 1996;9:77-9.
- Magrill AC, Nakano N, Khanduja V. Historical review of arthroscopic surgery of the hip. *Int Orthop* 2017;41:1983-94.
- Phillips NJ, Stanley D. (V) Arthroscopy of the elbow. *Curr Orthop* 2002;16:355-61.
- Camp CL, Degen RM, Dines JS, Sanchez-Sotelo J, Altchek DW. Basics of elbow arthroscopy Part II: Positioning and diagnostic arthroscopy in the supine position. *Arthrosc Tech* 2016;5:e1345-9.
- Camp CL, Degen RM, Dines JS, Altchek DW, Sanchez-Sotelo J. Basics of elbow arthroscopy Part III: Positioning and diagnostic arthroscopy in the lateral decubitus position. *Arthrosc Tech* 2016;5:e1351-5.
- Stetson WB, Vogeli K, Chung B, Hung NJ, Stevanovic M, Morgan S. Avoiding neurological complications of elbow arthroscopy. *Arthrosc Techn* 2018;7:e717-24.
- Andrews JR, Carson WG. Arthroscopy of the elbow. *Arthroscopy* 1985;1:97-107.
- Camp CL, Degen RM, Sanchez-Sotelo J, Altchek DW, Dines JS. Basics of elbow arthroscopy Part I: Surface anatomy, portals, and structures at risk. *Arthrosc Tech* 2016;5:e1339-43.
- Phillips BB. General principles of arthroscopy, arthroscopy of upper extremity. In: Canale ST, editor. *Campbell's Operative Orthopaedics*. 9th ed. St. Louis, MO: C. V. Mosby Co.; 1998. p. 1453-69, 1594-605.
- Van Den Ende KI, McIntosh AL, Adams JE, Steinmann SP. Osteochondritis dissecans of the capitellum: A review of the literature and a distal ulnar portal. *Arthroscopy* 2011;27:122-8.
- Steinmann SP. Elbow arthroscopy. *J Am Soc Surg Hand* 2003;3:199-207.
- Budge MD, Armstrong AD. Elbow arthroscopy: Set up, portals, and tools for success. *Oper Tech Orthop* 2009;19:209-19.
- Baker CL, Jones GL. Arthroscopy of the elbow. *Am J Sports Med* 1999;27:251-64.
- Goebel L, Madry H. History of arthroscopy. In: Randelli P, Dejour D, van Dijk C, Denti M, Seil R, editors. *Arthroscopy: Basic to Advanced*. 1st ed. Berlin, Heidelberg: Springer; 2016. p. 3-12.
- Jackson RW. A history of arthroscopy. *Arthroscopy* 2010; 26:91-103.
- Liang P, Zhao G, Gu X, Chen Z, Xu S, Lai W. Assessment of arthroscopic shavers: A comparison test of resection performance and quality. *J Orthop Surg Res* 2020;15:1-10.
- Kirkup J. The history and evolution of surgical instruments. VII. Spring forceps (tweezers), hooks and simple retractors. *Ann R Coll Surg Engl* 1996;78:544-52.
- Chen Z, Wang C, Jiang W, Tang N, Chen B. A review on surgical instruments of knee arthroscopic debridement and total hip arthroplasty. *Procedia CIRP* 2017;65:291-8.
- Vangsness CT Jr., Thordarson DB, Park K. A disposable fiberoptic arthroscope: A cadaver study. *Foot Ankle Int* 1994;15:502-4.
- Tasto JP, Cummings J, Medlock V, Hardesty R, Amiel D. Microtenotomy using a radiofrequency probe to treat lateral epicondylitis. *Arthroscopy* 2015;21:851-60.
- Ike RW. Diagnostic arthroscopy. *Baillieres Clin Rheumatol* 1996;10:495-517.
- Lange T, Buess G. Video technology for minimally invasive surgery. In: Cuschieri A, Buess G, Perissat J, editors. *Operative Manual of Endoscopic Surgery* 2. 1st ed. Berlin, Heidelberg: Springer; 1994. p. 71-90.
- Kelly EW, Morrey BF, O'Driscoll SW. Complications of elbow

- arthroscopy. *J Bone Joint Surg Am* 2001;83:25-34.
25. Greer WS, Field AC, Field LD. Handheld osteotomes facilitate arthroscopic elbow osteophyte removal. *Arthrosc Tech* 2018;7:e1031-5.
 26. Hsiao MS, Kusnezov N, Sieg RN, Owens BD, Herzog JP. Use of an irrigation pump system in arthroscopic procedures. *Orthopedics* 2016;39:e474-8.
 27. O'Driscoll SW, Morrey BF. Arthroscopy of the elbow. Diagnostic and therapeutic benefits and hazards. *J Bone Joint Surg Am* 1992;74:84-94.
 28. Elfeddali R, Schreuder MH, Eygendaal D. Arthroscopic elbow surgery, is it safe? *J Shoulder Elbow Surg* 2013;22:647-52.
 29. Grifka J, Boenke S, Krämer J. Endoscopic therapy in epicondylitis radialis humeri. *Arthroscopy* 1995;11:743-8.
 30. Merrell G, DaSilva MF. Arthroscopic treatment of lateral epicondylitis. *J Hand Surg* 2009;34:1130-4.
 31. Lo IK, King GJ. Arthroscopic radial head excision. *Arthroscopy* 1994;10:689-92.
 32. Menth-Chiari WA, Ruch DS, Poehling GG. Arthroscopic excision of the radial head: Clinical outcome in 12 patients with post-traumatic arthritis after fracture of the radial head or rheumatoid arthritis. *Arthroscopy* 2001;17:918-23.
 33. Trebše R, Poberaj B, Cör A, Levasic V. Arthroscopic removal of an osteoid osteoma in the radial head: A case report. *Arthroscopy* 2007;23:1361.e1-3.
 34. Eames MH, Bain GI. Distal biceps tendon endoscopy and anterior elbow arthroscopy portal. *Tech Shoulder Elbow Surg* 2006;7:139-42.
 35. Bhatia DN. Endoscopic repair of acute and chronic retracted distal biceps ruptures. *J Hand Surg* 2016;41:e501-7.
 36. Phadnis J, Bain G. Dry arthroscopy of the elbow. *Arthrosc Tech* 2015;4:e335-9.
 37. Bain G, Phadnis J, Mwaturura T. Dry elbow arthroscopy. In: Bain G, Eygendaal D, van Riet RP, editors. *Surgical Techniques for Trauma and Sports Related Injuries of the Elbow*. 1st ed. Berlin, Heidelberg: Springer; 2020. p. 137-41.
 38. Phadnis J, Bain G. Distal biceps endoscopy repair: Dry technique. In: Bain G, Eygendaal D, van Riet RP, editors. *Surgical Techniques for Trauma and Sports Related Injuries of the Elbow*. 1st ed. Berlin, Heidelberg: Springer; 2020. p. 439-46.
 39. Kamineni S, Hamilton DA Jr. Arthroscopic ulnar nerve identification during posterior elbow arthroscopy. *Arthrosc Tech* 2012;1:e113-7.
 40. Rubin TA, Gluck MJ, Robinson J, Hausman M. Arthroscopic-assisted treatment of pediatric elbow fractures. In: Bain G, Eygendaal D, van Riet RP, editors. *Surgical Techniques for Trauma and Sports Related Injuries of the Elbow*. 1st ed. Berlin, Heidelberg: Springer; 2020. p. 637-50.
 41. Savoie FH, O'Brien MJ, Field LD, Gurley DJ. Arthroscopic and open radial ulnohumeral ligament reconstruction for posterolateral rotatory instability of the elbow. *Clin Sports Med* 2010;29:611-8.
 42. Mica MC, Caekebeke P, van Riet R. Lateral collateral ligament injuries of the elbow-chronic posterolateral rotatory instability (PLRI). *EFORT Open Rev* 2017;1:461-8.
 43. Savoie FH, Morrey BF. The future of arthroscopy. In: Morrey BF, editor. *The Elbow and its Disorders*. 4th ed. Philadelphia, PA: Saunders; 2009. p. 625.
 44. Rodriguez-Martin J. The evolution of elbow arthroscopy. *Orthop Muscular Syst* 2012;1:e104.
 45. Thomas RJ, Savoie RH, Field LD. Complications of elbow arthroscopy. In: Savoie FH, Field LD, editors. *AANA Advanced Arthroscopy: The Wrist and Elbow*. 1st ed. Philadelphia, PA: Saunders; 2010. p. 146-9.
 46. Ng T, Rush LN, Savoie FH. Arthroscopic distal triceps repair. *Arthrosc Tech* 2016;5:e941-5.
 47. Kamineni S, Savoie FH, ElAttrache N. Endoscopic extracapsular capsulectomy of the elbow: A neurovascularly safe technique for high-grade contractures. *Arthroscopy* 2007;23:789-92.
 48. Integrated Endoscopy Receives FDA Clearance for Nuvis Single use had Battery Operated Arthroscope. *Integrated Endoscopy*; 2019. Available from: <https://www.iescope.com/integrated-endoscopy-receives-fda-clearance-for-nuvis-single-use-hd-battery-operated-arthroscope>. [Last accessed on 2020 Apr 26].

How to cite this article: Bennett K, Kamineni S. History of elbow arthroscopy. *J Arthrosc Surg Sport Med*, doi: 10.25259/JASSM_7_2020