



Patient Education & FAQ's

# Diabetes & the Eye

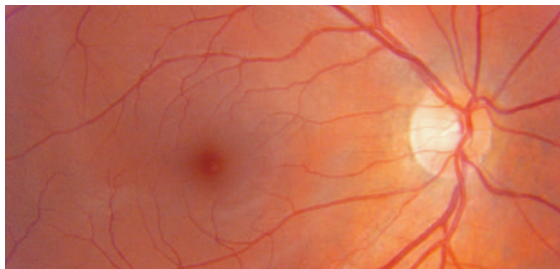
Approximately 4% of people have diabetes; often undiagnosed. As well as damaging other parts of the body, diabetes can also damage the eyes causing vision problems, glaucoma, cataract and diabetic retinopathy.

## Diabetic Retinopathy

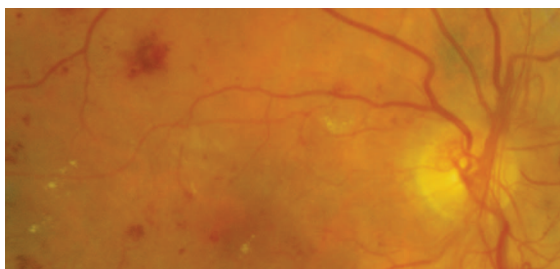
When diabetes causes long-term damage to the retinal blood vessels, an inflammation of the retina occurs called Diabetic Retinopathy.

## Damage to the Eye & Vision

Diabetic retinopathy is a very serious sight-threatening condition resulting in swelling, haemorrhages and exudates (discharge) on the retina.



Example of normal healthy retina



Example of retina with Diabetic Retinopathy

Changes in blood sugar levels can cause swelling in the eye which then leads to blurred and fluctuating vision. In addition, glaucoma and cataract are more common in diabetics and the consequences of the disease may also lead to retinal detachment.

## Risk Factors

The largest risk factor for diabetic retinopathy is the length of duration of the disease. The type of diabetes also has an effect with 90% of insulin-dependent (Type 1) diabetics having retinopathy after 20 years, compared to 70% of the non-insulin-dependent (Type

2) patients. Diabetic control is another major risk factor and there are also links to high blood pressure, kidney disease and smoking.

## Symptoms

Without realising that the condition is present, 30% of all diabetics already have retinal damage. Retinopathy can also be quite advanced in one eye before the patient notices any symptoms.

## Treatment


Possible treatment depends upon the severity of the retinopathy. Laser surgery to the retina is a possibility, if detected early enough. Certainly the best treatment is early detection.

## Recommendations

Every diabetic needs good control of the disease and they should be having routine eye examinations every 12 months to check for any signs of retinopathy.

These patients also need careful recording of their retinal condition so that comparisons can be made over time. The best way to do this is with "retinal fundus photographs" or "digital retinal imaging (DRI)".

Specialised tests like Fluorescein Angiography and Ocular Coherence Tomography (OCT) are sometimes also needed.



Equipment for Digital Retinal Imaging

Last edited: 23/02/11