

# Low-Level Laser Therapy Improves Vision in Patients with Age-Related Macular Degeneration

Boris T. Ivandic, M.D.,<sup>1</sup> and Tomislav Ivandic, M.D.<sup>2</sup>

## Abstract

**Objective:** The objective of this study of a case series was to examine the effects of low-level laser therapy (LLLT) in patients with age-related macular degeneration (AMD).

**Background Data:** AMD affects a large proportion of the elderly population; current therapeutic options for AMD are limited, however.

**Patients and Methods:** In total, 203 patients (90 men and 113 women; mean age  $63.4 \pm 5.3$  y) with beginning (“dry”) or advanced (“wet”) forms of AMD ( $n = 348$  eyes) were included in the study. One hundred ninety-three patients (mean age  $64.6 \pm 4.3$  y;  $n = 328$  eyes) with cataracts ( $n = 182$  eyes) or without cataracts ( $n = 146$  eyes) were treated using LLLT four times (twice per week). A semiconductor laser diode (780 nm, 7.5 mW, 292 Hz, continuous emission) was used for transconjunctival irradiation of the macula for 40 sec ( $0.3 \text{ J/cm}^2$ ) resulting in a total dose of  $1.2 \text{ J/cm}^2$ . Ten patients ( $n = 20$  eyes) with AMD received mock treatment and served as controls. Visual acuity was measured at each visit. Data were analyzed retrospectively using a *t*-test.

**Results:** LLLT significantly improved visual acuity ( $p < 0.00001$  versus baseline) in 162/182 (95%) of eyes with cataracts and 142/146 (97%) of eyes without cataracts. The prevalence of metamorphopsia, scotoma, and dyschromatopsia was reduced. In patients with wet AMD, edema and bleeding improved. The improved vision was maintained for 3–36 mo after treatment. Visual acuity in the control group remained unchanged. No adverse effects were observed in those undergoing therapy.

**Conclusion:** In patients with AMD, LLLT significantly improved visual acuity without adverse side effects and may thus help to prevent loss of vision.

## Introduction

AGE-RELATED MACULAR DEGENERATION (AMD) is the predominant cause of irreversible loss of vision in the elderly. AMD affects 30–50% of individuals 60 years or older.<sup>1,2</sup> AMD-related disability and poor quality of life are likely to increase the socio-economic burden in the elderly living in industrialized countries.<sup>3</sup>

AMD results from defects in the choriocapillaris, Bruch’s membrane, and the retinal pigmented epithelium (RPE) underneath the macula. The epitheliopathy diminishes lysosomal activity and phagocytosis of the outer photoreceptors and disrupts the transportation of cell debris through the RPE to the choriocapillaris.<sup>4</sup> The resulting accumulation of cell debris in Bruch’s membrane leads to thickening and hydrophobic charging of the membrane.<sup>5</sup> This suffocates the photoreceptors and promotes fibrovascular proliferation and the formation of subretinal exu-

dates. Ultimately, the decay of the retina results in loss of vision.<sup>6</sup>

Current therapeutic approaches aim to stabilize the remaining vision because photoreceptor function appears to be irreversibly lost. Treatment options, such as photodynamic therapy, laser photocoagulation, transpupillary thermotherapy, ionizing radiation, and surgery have been applied with limited success in cases of exudative, advanced AMD.<sup>7,8</sup> These treatments may also produce collateral damage of the foveal neurosensory retina and impair visual function further. At present, antioxidant and mineral dietary supplements as well as anti-angiogenetic drugs are being discussed as alternative treatment options.<sup>9–12</sup>

LLLT represents a novel therapeutic method that, other than surgical laser applications, does not damage tissues. In this study of a case series we investigated the effects of LLLT in patients with AMD of all forms and stages, and varying degrees of vision impairment.

<sup>1</sup>University of Heidelberg, Otto-Meyerhof Centre, Heidelberg, and <sup>2</sup>Medical Centre, Munich, Germany.

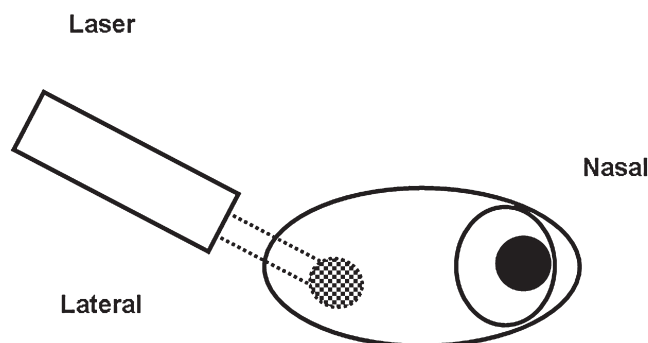


FIG. 1. Diagram showing how low-level laser therapy was given. For the right eye the laser beam was placed at a distance of 1 cm and pointed towards the macular area.

## Patients and Methods

### Study design

This study of a case series was conducted in accordance with the Helsinki declaration. Informed consent was obtained from all patients before entry into the study. Data were collected at a single non-institutional center in Germany during a 7-year period and were evaluated retrospectively.

### Patients

Patients with AMD of all stages (dry to wet exudative forms with or without cataracts) were included if their visual acuity was  $\leq 20/20$ . Patients were excluded if they had concomitant diseases that would impair vision except for new cataracts, or if they had received any prior treatment that could have affected vision; patients with visual acuity  $>20/20$  were also excluded.

### Laser

For LLLT, a semiconductor laser diode with continuous emission at 780 nm (7.5 mW, 292 Hz) fitted with collimating optics (spot diameter = 3 mm) in a handheld casing was used. The laser diode was driven by an apparatus that allowed low-frequency switching of the laser beam and provided automatic power control (Bimed, Munich, Germany).

In an initial experiment, the extinction of laser light ( $\lambda = 780$  nm) was examined in a freshly enucleated pig eye ( $22 \times 24$  mm) to determine the lowest penetrating laser power required for the laser energy to reach the RPE and retina. Power output was measured using a LC-U-2E power meter (Laser Components GmbH, Olching, Germany).

### Treatment

As illustrated in Fig. 1, laser radiation was applied transconjunctivally to the macula for 40 sec ( $0.3 \text{ J/cm}^2$ ). During LLLT the eye was in adduction; if necessary, the lids were fixed manually.

Four treatments were administered (two treatments per week) resulting in a total dose of  $1.2 \text{ J/cm}^2$ . Ten patients with AMD ( $n = 20$  eyes) were randomly selected to receive mock treatment (control group); the laser beam was directed above the nose without contacting the eye. An audible signal heard every 10 sec was interpreted by the patients as treatment. During the treatment period, no other therapy was applied.

### Measurements

Eyes were examined before inclusion, prior to each treatment session, and at the end of the study. Visual acuity was assessed by projection of American Optical optotypes (Snellen) at a distance of 20 feet after optimal correction of refraction with blinding. In order to avoid patient memorization of the letters, only unknown optotypes were presented each time. Color vision was examined by use of a desaturated color test (Farnsworth D-15 series). The Amsler test was used to screen central scotomas.

To assess treatment safety, the investigator examined the patients' eyes before and after each treatment session and asked patients about their general well-being by asking non-leading questions.

### Data analysis

Data on visual acuity were analyzed by calculating the changes in visual acuity (end of study versus baseline); data were transformed logarithmically to allow presentation of results as logarithmic minimal angle resolution (log MAR). For statistical analysis, a *t*-test for paired observations was used.

TABLE 1. EXTINCTION OF LASER LIGHT ( $\lambda = 780$  nm) THROUGH THE OCULAR LAYERS IN PIG'S EYE

Input laser power, $I_0$ (mW)	Tissue(s)	Output laser power, $I$ (mW)	Extinction ( $E = \log I_0/I$ )
10.5	Cornea	10.5	0
	Lens	11.0	-0.20
	Sclera	4.2	0.397
	Choroidea	2.9	0.558
	RPE	1.5	0.845
	Retina	8.8	0.076
	Conjunctiva-sclera-choroidea-RPE-retina	0.2	1.720

RPE, retinal pigmented epithelium.

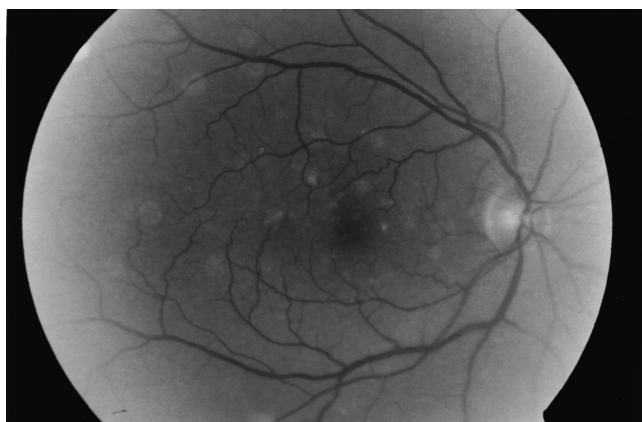


FIG. 2. Right eye of a 64-year-old patient with early-stage AMD.

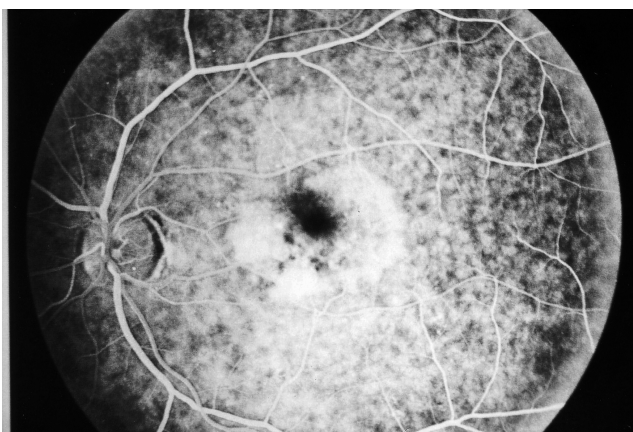


FIG. 3. Fluorescein angiogram of exudative advanced AMD in the left eye of a 62-year-old patient.

## Results

### Determination of laser power

Initial experimentation on a freshly enucleated pig eye aimed to determine the optimum power level of laser energy to be used in this study. By using a low sub-thermal dose of radiation (10.5 mW), only a small proportion of the energy reached the retina (Table 1). The largest proportion was absorbed by the sclera, choroidea, and RPE. The data indicated that a power output of 10.3 mW was required for the laser light to pass through all layers of the eye.

### Demographic characteristics

In total, 203 patients (90 men and 113 women) with AMD of various stages ( $n = 348$  eyes) and a mean age of  $63.4 \pm 5.3$  y were included in the study. All patients received treatment as planned; none of the patients withdrew from the study.

One hundred ninety-three patients (mean age  $64.6 \pm 4.3$  y) were treated using LLLT; of 328 treated eyes, 146 (45%)

eyes were without cataracts, and 182 (55%) eyes were with cataracts. Eye examination revealed that 230 eyes had drusen or were depigmented; geographic atrophy was noted in 12 eyes. Progressive, exudative AMD was diagnosed in 86 eyes with no other disorders. Examples of early-stage and advanced AMD are shown in Figs. 2 and 3, respectively.

The control group receiving mock treatment comprised 10 patients (20 eyes) with all stages of AMD (4 men and 6 women) with a mean age of  $62.3 \pm 6.4$  years.

### Changes in visual acuity

There was a statistically significant increase in visual acuity ( $p < 0.00001$ , end of study versus baseline) for both patients with and those without cataracts. The improvement in visual acuity was maintained for 3–36 mo. By contrast, visual acuity remained unchanged in all patients in the control group.

In patients without cataracts (Table 2), visual acuity improved in 142/146 eyes (97.3%;  $p < 0.00001$ ): by one row of

TABLE 2. VISUAL ACUITY BEFORE AND AFTER LLLT IN PATIENTS WITH AMD WITHOUT CATARACTS ( $N = 146$  EYES)

		Before therapy											Log MAR	Sums
Visual acuity		20/400	20/200	20/100	20/80	20/70	20/60	20/50	20/40	20/30	20/25	20/20		
After therapy	20/400	1												1
	20/200		2										+1.0	2
	20/100			1									+0.7	
	20/80				1								+0.6	1
	20/70					1							+0.55	1
	20/60						1						+0.5	
	20/50		2	1				1					+0.4	3
	20/40			1					1				+0.3	2
	20/30			2	3	4	1	2	1				+0.2	13
	20/25				4	5	3	6	9	7			+0.1	34
	20/20				1		1	4	12	31	4		0	53
	20/16									9	11	16	-0.1	36
Sums		1	5	4	8	10	5	13	22	47	15	16		146

Number of eyes are in bold type.  
log MAR, logarithmic minimal angle resolution.

TABLE 3. VISUAL ACUITY BEFORE AND AFTER LLLT IN PATIENTS WITH AMD WITH CATARACTS (N = 182 EYES)

		Before therapy												Log MAR	Sums
	Visual acuity	20/ 400	20/ 200	20/ 100	20/ 80	20/ 70	20/ 60	20/ 50	20/ 40	20/ 30	20/ 25	20/ 20			
After therapy	20/400	2												2	
	20/200	3	2											5	
	20/100		1											1	
	20/80		2		1									3	
	20/70	1		2	3	1								7	
	20/60			2	3									5	
	20/50		1	3	4	2								10	
	20/40		1	2	2		1	2	1					9	
	20/30			2	2	4	1	16	15	3				43	
	20/25		1			1	2	13	7	14				38	
	20/20					1	4	5	32		4			46	
	20/16										10	3		13	
Sums		6	8	11	15	8	5	35	28	49	14	3		182	

Number of eyes are in bold type.  
log MAR, logarithmic minimal angle resolution.

optotypes in 29/146 (19.8%), by two rows in 54/146 (37.0%), by three rows in 28/146 (19.2%), by four or five rows in 12/146 (8.2%), by six rows in 6/146 (4.1%) and by seven rows in 1/146 (0.7%). Visual acuity remained unchanged in 4/146 eyes (2.7%).

In patients with cataracts (Table 3), visual acuity improved in 172/182 eyes (94.5%;  $p < 0.00001$ ) eyes: by one row of optotypes in 45/182 (24.7%), by two rows in 75/182 (41.2%), by three rows in 25/182 (13.7%), by four rows in 16/182 (8.8%), by five rows in 7/182 (3.8%), by six rows in 3/182 (1.6%), and by seven rows in 1/182 (0.5%). Visual acuity remained unchanged in 10/182 eyes (5.5%).

#### Changes in concomitant eye disorders

In patients treated with LLLT the improvement in visual acuity was in most cases accompanied by a decrease in meta-

morphopsias, scotomas, and acquired dyschromatopsia (Fig. 4). In patients with wet AMD, edema and bleeding were reduced.

#### Safety and tolerability

The treatment was well tolerated. No adverse local or systemic side effects were observed.

#### Discussion

LLLT given over 2 wk led to an improvement in visual acuity in most patients with AMD (>90%). An increase of three to seven rows of optotypes was observed in 52/182 (28.6%) of eyes with cataracts, and in 59/146 (40.4%) of eyes without cataracts. Unlike other therapeutic approaches, LLLT improved visual acuity in patients with AMD of every

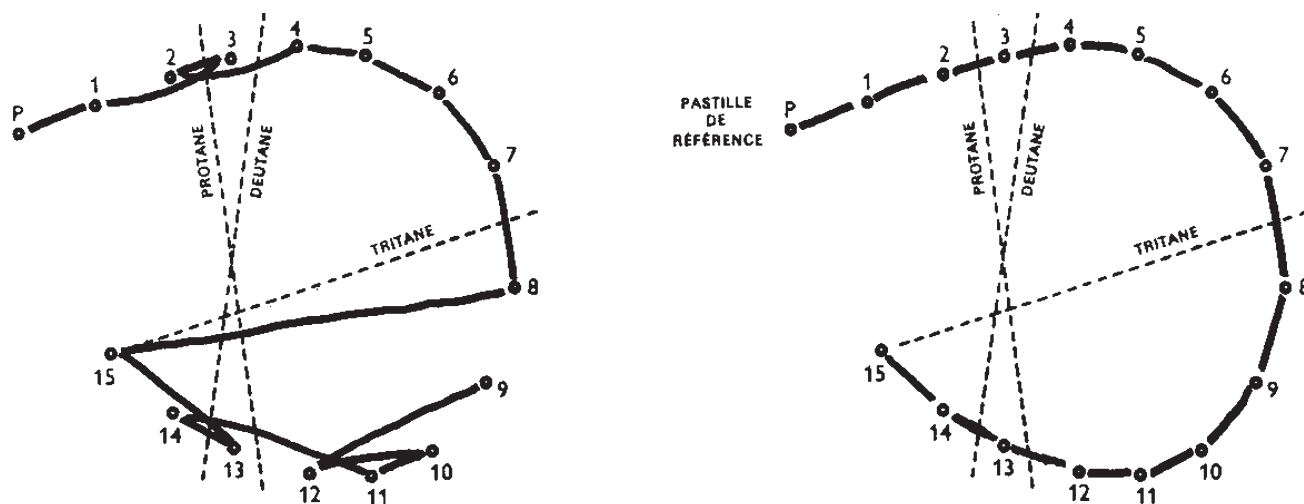


FIG. 4. Normalization of impaired color vision in a 49-year-old patient. Farnsworth color test results (Series D-15) before (left) and after (right) four treatments with LLLT. Visual acuity increased from 20/30 to 20/16.



stage. The improvement in visual function was maintained for up to 36 mo.

The results of this retrospective analysis of a case series are encouraging, especially in light of the fact that if untreated, AMD inevitably leads to irreversible loss of vision. Thus LLLT may, when initiated during the early stages of AMD, help prevent loss of vision. LLLT may also be combined with other therapeutic approaches. Although not investigated in this study, it is likely that synergistic effects may be seen (e.g., improved outcome or shorter treatment duration).

In addition to the improvement in visual acuity, other positive effects of LLLT were noted. Eye examinations revealed that LLLT diminished pigment accumulations and cystic drusen. Metamorphopsia, acquired impairments of color vision, and relative scotomas improved as well. Moreover, in patients with wet AMD, edema and bleeding were reduced.

Treatment with laser energy at a wavelength of 780 nm was not perceived as unpleasant and was well accepted by the patients. No adverse effects were observed.

In general, the photochemical effects of light are mediated through the interaction of photons and various cellular acceptor molecules. Thus, photon energy is transformed into biochemical energy, which stimulates metabolic reactions.

LLLT may increase cellular metabolism in choroidea, RPE, and in photoreceptors, where the energy is absorbed by pigments. Regular metabolic processes may be enhanced and repair processes may be triggered or accelerated. Recently, an increase in the expression of heat shock proteins was found in the retinal and choroidal layers after sub-thermal transpupillary application of laser energy.<sup>13</sup> Heat shock proteins (or chaperones) are known to stimulate cellular metabolism and may help prevent premature cell death. In *in vitro* experiments, application of laser light was shown to increase cellular metabolic activity, the generation of adenosine triphosphate, and phagocytosis.<sup>14,15</sup> Enhanced lysosomal activity and phagocytosis of cell debris and pigments may help to revitalize the retina.<sup>16</sup> The detailed cellular and molecular mechanisms underlying the biomedical effects of laser energy in the treatment of patients with AMD have yet to be further elucidated.

## Conclusion

In conclusion, this study of a case series shows that LLLT may be a novel therapeutic option for both early and advanced forms of AMD. This simple and highly effective treatment improves visual acuity and may help to prevent loss of vision without adverse side effects.

## References

1. Pauleikhoff, D., and Holz, F.G. (1996). Age-related macular degeneration. 1. Epidemiology, pathogenesis and differential diagnosis. *Ophthalmologie*. 93, 299–315.
2. Apte, R.S., Scheufele, T.A., and Blomquist, P.H. (2001). Etiology of blindness in an urban community hospital setting. *Ophthalmology*. 108, 693–696.
3. Evans, J., and Wormald, R. (1996). Is the incidence of registrable age-related macular degeneration increasing? *Br. J. Ophthalmol.* 80, 9–14.
4. Moore, D.J., and Clover, G.M. (2001). The effect of age on the macromolecular permeability of human Bruch's membrane. *Invest. Ophthalmol. Vis. Sci.* 42, 2970–2975.
5. Liang, F.Q., and Godley, B.F. (2003). Oxidative stress-induced mitochondrial DNA damage in human pigment epithelial cells: a possible mechanism for RPE aging-related macular degeneration. *Exp. Eye Res.* 76, 397–403.
6. Ambati, J., Ambati, B.K., Yoo, S.H., Ianchule, S., and Adamis, A.P. (2003). Age-related macular degeneration: etiology, pathogenesis, and therapeutic strategies. *Surv. Ophthalmol.* 48, 257–293.
7. Hooper, C.Y., and Guymer, R.H. (2003). New treatments in age-related macular degeneration. *Clin. Experiment. Ophthalmol.* 31, 376–391.
8. AREDS Report No. 8 (Age-Related Eye Disease Study Research Group). (2001). A randomized, placebo-controlled, clinical trial of high-dose supplementation with vitamins C and E, beta carotene, and zinc for age-related macular degeneration and vision loss. *Arch. Ophthalmol.* 119, 1417–1436.
9. Evans, J.R. (2002). Antioxidant vitamin and mineral supplements for age-related macular degeneration. *Cochrane Database Syst. Rev.* CD000254.
10. Holz, F.G., and Miller, D.W. (2003). Pharmacological therapy for age-related macular degeneration. Current developments and perspectives. *Ophthalmologie*. 100, 97–103.
11. Holz, F.G., and Pauleikhoff, D. (1996). Age-related macular degeneration. 2. Therapeutic approaches. *Ophthalmologie*. 93, 483–506.
12. Rosenfeld, P.J., Brown, D.M., Heier, J.S., Boyer, D.S., Kaiser, P.K., and Chung Kim, R.Y. (2006). Ranibizumab for neovascular age-related macular degeneration. *N. Engl. J. Med.* 14, 1419–1431.
13. Desmettre, T., Maurage, C.A., and Mordon, S. (2003). Transpupillary thermotherapy (TTT) with short duration laser exposures induce heat shock protein (HSP) hyperexpression on choroidoretinal layers. *Lasers Surg. Med.* 33, 102–107.
14. Mester, E., Mester, A.F., and Mester, A. (1985). The biomedical effects of laser application. *Lasers Surg. Med.* 5, 31–39.
15. Karu, T.I. (1987). Photobiological fundamentals of low-power laser therapy. *IEEE J. Quantum Electronics*. 10, 1703–1717.
16. Chen, L., Yang, P., and Kijlstra, A. (2002). Distribution, markers, and functions of retinal microglia. *Ocul. Immunol. Inflamm.* 10, 27–39.

Address reprint requests to:  
Dr. Boris T. Ivandic, M.D.  
University of Heidelberg  
Otto-Meyerhof Centre  
Im Neuenheimer Feld 350  
69120 Heidelberg, Germany

E-mail: boris.ivandic@med.uni-heidelberg.de