

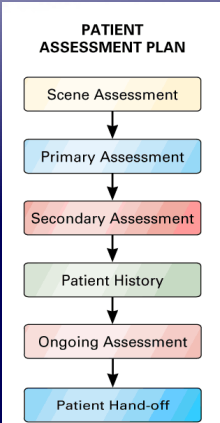


Emergency Medical Responder
PATIENT ASSESSMENT




Patient Assessment Plan


Patient Assessment Plan



```
graph TD; A[PATIENT ASSESSMENT PLAN] --> B[Scene Assessment]; B --> C[Primary Assessment]; C --> D[Secondary Assessment]; D --> E[Patient History]; E --> F[Ongoing Assessment]; F --> G[Patient Hand-off];
```

Figure 11-1
Patient assessment plan.






Primary Survey

- Primary Assessment

PRIMARY ASSESSMENT


```
graph TD; A[General Impression] --> B[Level of Consciousness]; B --> C[Airway]; C --> D[Breathing]; D --> E[Circulation]; E --> F[EMS Update];
```

Figure 11-2 The primary assessment takes about a minute.


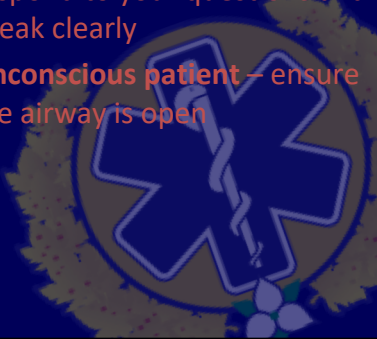


- Primary Assessment

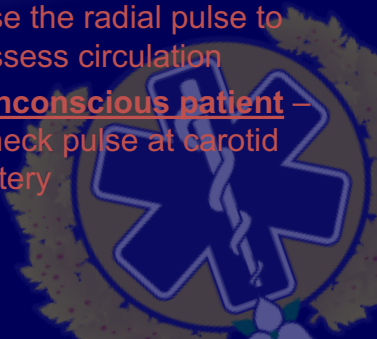
- Level of Consciousness
 - 1) Alert
 - 2) Verbal
 - 3) Painful
 - 4) Unconscious




- Primary Assessment
 - Airway
 - **Conscious patient** – can respond to your questions and speak clearly
 - **Unconscious patient** – ensure the airway is open




- Primary Assessment
 - Circulation
 - **Conscious patient** – use the radial pulse to assess circulation
 - **Unconscious patient** – check pulse at carotid artery



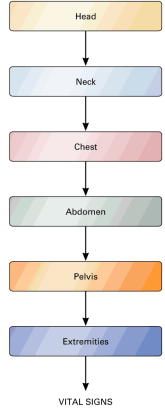


- **Primary Assessment**
 - **EMS Update**
 - Report the following:**
 - 1) Age and gender of patient
 - 2) Chief complaint
 - 3) Level of consciousness (LOC)
 - 4) Airway and breathing status
 - 5) Circulation



- **Secondary Assessment**
 - **Methods of Examination**
 - 1) Inspection
 - 2) Auscultation
 - 3) Palpation
 - **Look for DOTS**
 - 1) Deformities (D)
 - 2) Open injuries (O)
 - 3) Tenderness (T)
 - 4) Swelling (S)


THE SECONDARY ASSESSMENT



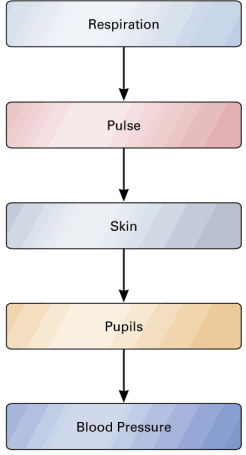
```

graph TD
    A[Head] --> B[Neck]
    B --> C[Chest]
    C --> D[Abdomen]
    D --> E[Extremities]
    E --> F[VITAL SIGNS]
    
```

Figure 11-15 Components of the secondary assessment.



- Secondary Assessment – Vital signs



```

graph TD
    A[Respiration] --> B[Pulse]
    B --> C[Skin]
    C --> D[Pupils]
    D --> E[Blood Pressure]
    
```

Figure 11-26 Vital signs.




TABLE 11-1
NORMAL RESPIRATORY RATES

Patient	Respiratory Rate*
Infant	Up to 60
Child	20–40
Adult	12–20

* Approximate rate per minute at rest.
Copyright © 2010 Pearson Education Canada



TABLE 11-2
NORMAL PULSE RATES

Patient	Pulse Rate*
Infant	120–150
Child	80–150
Adult	60–80

* Approximate rate per minute at rest.

Copyright © 2010 Pearson Education Canada



TABLE 11-3
NORMAL BLOOD PRESSURE RANGES

Patient	Systolic	Diastolic
Child	$2 \times \text{patient's age} + 80$	50–80 mmHg
Adult	Males: patient's age + 100 (up to 150 mmHg)	65–90 mmHg
	Females: patient's age + 100 (up to 140 mmHg)	55–80 mmHg

Copyright © 2010 Pearson Education Canada

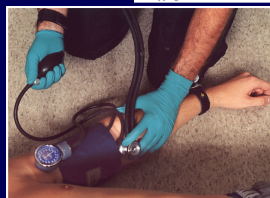

Figure 11-32 Taking blood pressure by auscultation.

Copyright © 2010 Pearson Education Canada

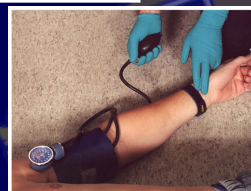
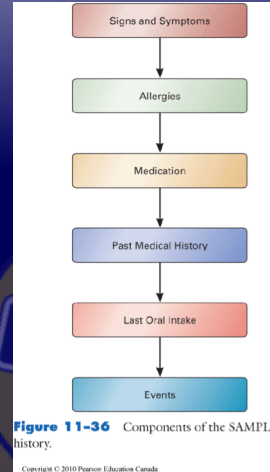
Figure 11-33 Taking blood pressure by palpation.

Copyright © 2010 Pearson Education Canada



- Patient History (Sample)



- Patient History (Sample)

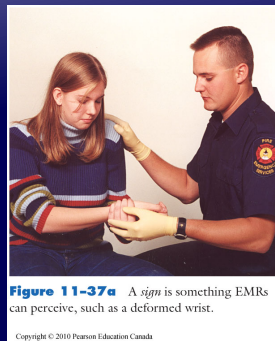


Figure 11-37a A *sign* is something EMRs can perceive, such as a deformed wrist.

Copyright © 2010 Pearson Education Canada

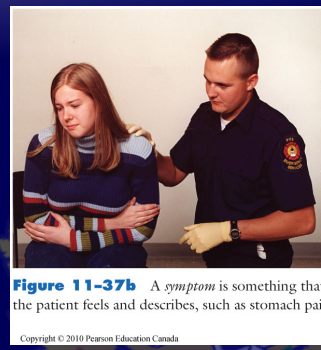



Figure 11-37b A *symptom* is something that the patient feels and describes, such as stomach pain.

Copyright © 2010 Pearson Education Canada



- Ongoing Assessment

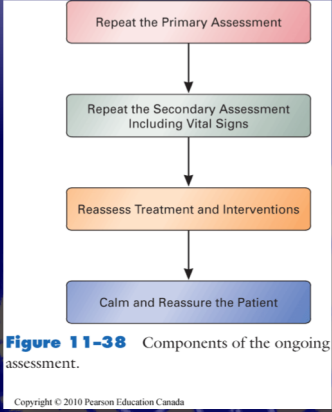



Figure 11-38 Components of the ongoing assessment.

Copyright © 2010 Pearson Education Canada



- Patient Hand-Off Report

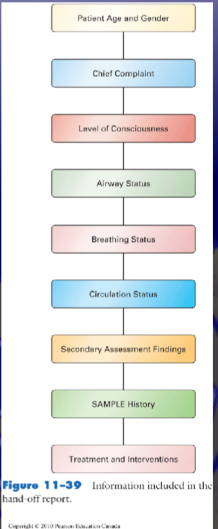


Figure 11-39 Information included in the hand-off report.

Copyright © 2010 Pearson Education Canada